

## L-Shaped nipple reconstruction: a novel technique to improve patient satisfaction outcomes

KRISHNAMURTHY SREEDHAR MURTHY

**SUMMARY: L-Shaped nipple reconstruction: a novel technique to improve patient satisfaction outcomes.**

KRISHNAMURTHY SREEDHAR MURTHY

*Introduction. Nipple reconstruction is the final stage of breast reconstruction and performed after acceptable breast mound shape and symmetry has been achieved. Here is a description of an original technique of L shaped nipple reconstruction to address issues such as transverse mas-tectomy scar which lies at the Neo nipple position.*

*Aim. The objective of this study is to describe an original technique of nipple reconstruction, using a combination of random flap and dermal graft; and also measures patient satisfaction of outcomes. This original technique is set to overcome challenges of nipple reconstruction such as correct positioning, maintaining adequate*

*projection and creating an almost inconspicuous scar.*

*Methods. 31 patients underwent the L-shaped nipple reconstruction between 2011 and 2016 at our Breast Unit. Complications and outcomes were analysed and compared with 59 patients who underwent traditional CV flap during the same study period (total N=90, i.e., L flap n=31 and CV flap=59).*

*Results. There was no statistically significant difference in complication rates between traditional CV flap (9.7%) and L-shaped (13.6%) nipple reconstructions (Fishers exact test  $p=0.74$ ). In our study cohort undergoing L flap nipple reconstruction, 94% were either pleased or very pleased with their decision to have undergone nipple reconstruction and 93% would either strongly or very strongly recommend it to a friend.*

*Conclusions. The innovative L-shaped nipple reconstruction has positive patient satisfaction out-comes and is a very suitable alternative to traditional nipple reconstruction such as CV flap.*

KEY WORDS: L flap - Nipple reconstruction - Novel technique - Patient satisfaction - Areolar graft.

### Introduction

Reconstruction of Nipple-Areolar Complex has been shown to have a positive influence on the overall recovery process of women undergoing post mastectomy breast reconstruction and hence helps to restore body image more completely. This clearly underscores the well-known concept that, part of the reconstruction of an aesthetically pleasing breast, is a high-quality nipple-areolar reconstruction (1).

Over the last 30 years, many different techniques have been described to accomplish this task of nipple-areola reconstruction. The goals for this nipple-areola reconstruction include appropriate nipple pro-

jection, areolar colour, and areolar texture. A number of reconstructive techniques have been described for nipple reconstruction including skin grafts, composite grafts, and various local flaps. Numerous techniques, using a variety of geometric designs, have been reported and reviewed (2-9). Each of these techniques aims to achieve a natural shape with maintenance of projection over time, and minimal donor site morbidity. The most popular techniques benefit from simplicity, reliability and reproducibility.

Presented in this article is an original and novel technique, L shaped nipple reconstruction; which achieves these goals by providing an alternative to traditional techniques such as CV flap (9). This has proven to be a suitable alternative option when previous mastectomy scars preclude optimum nipple positioning.

In this chapter, we share our institution's experience with the L flap nipple areolar reconstruction.

Department of Breast Surgery, Liverpool University, United Kingdom

Corresponding author: Krishnamurthy Murthy, e-mail: rksmurthy@gmail.com

© Copyright 2019, CIC Edizioni Internazionali, Roma

Here, an earnest attempt is made to describe the indications for its use, flap design and surgical technique, and outcomes and complications associated with its use.

## Patients and methods

31 patients underwent L shaped nipple reconstruction following breast reconstruction between 2011 and 2016, at Liverpool Breast Unit. The study cohort were identified from prospectively collected data and analysed. All patients with transversely placed mastectomy scar, considered otherwise unsuitable for traditional CV flap reconstruction, were included in this study.

Once the patients were identified, their case notes were reviewed to record patient's age, body mass index, and position of previous mastectomy scar, type of breast reconstruction, chemotherapy, medical history, and smoking history. Complications explored included haematoma formation, postoperative wound healing problems, nipple-areola complex necrosis (partial or complete), infection, discharge, pain, fat necrosis and hypertrophic scarring.

Of the 31 patients, 17 patients (55%) had implant based reconstruction and 12 patients (39%) had Latissimus dorsi (LD) with implant reconstruction and 2 patients (6%) had LD flap autologous breast shape reconstruction.

The timing of L flap nipple reconstruction ranged from 6 months to 2 years after the initial cancer surgery or breast reconstruction, with an average time of 15 months.

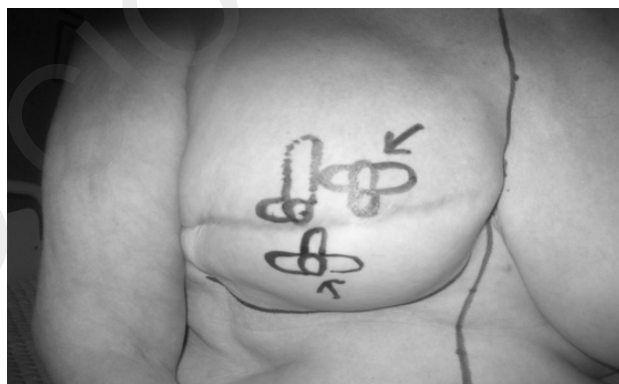

Figure 1 - Transverse mastectomy scar with mark up of L flap and CV flap (depicted with arrows).

Each patient was sent an outcome questionnaire, using validated Likert scoring scales (scale of 1 to 5), relating specifically to their nipple reconstruction. The questionnaire using Likert Scales was developed to evaluate overall patient satisfaction with cosmetic result, and addressed key issues, such as perceived match to contralateral nipple, confidence in clothing and reported complications.

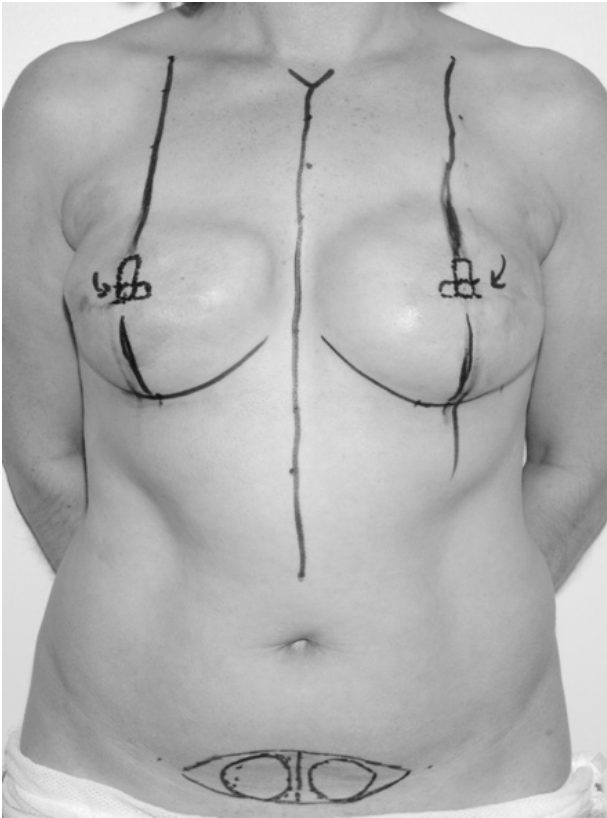
## Surgical technique

L-flap nipple reconstruction is a random skin flap, containing dermal and adipose tissue. It has a pedicle with long and short arms which resemble the letter L and hence the terminology. The L-flap was used on all our patients with transverse mastectomy scars, which would otherwise preclude the use of traditional flap, such as CV flap (Figure 1).

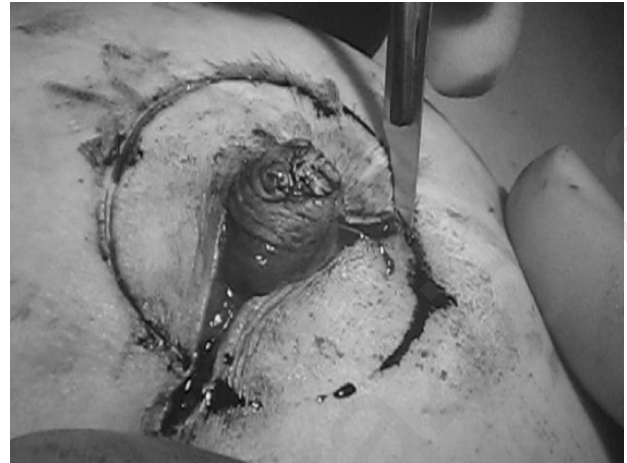
The traditional CV flap marked in Figure 1 above, would produce unsatisfactory neo nipple position, i.e., above or below the mastectomy scar. Whereas, the alternate L shaped flap offers optimal neo nipple position.

Preoperative marking was performed with patient standing to achieve ideal and closest natural nipple position. Marking with patient stood up would further ensure to centre the nipple symmetrically to the opposite side (natural or reconstructed nipple). The important markings included the patient's breast meridian, infra-mammary fold, and new nipple-areolar position (Figure 2).

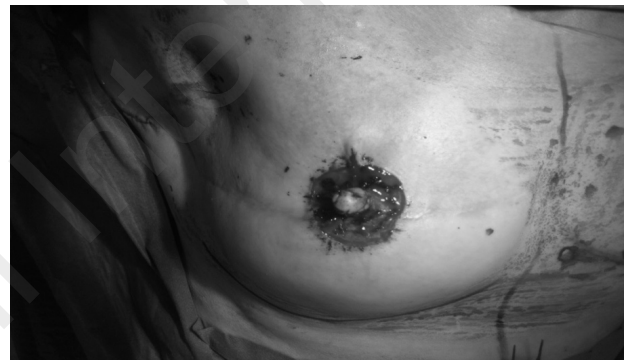The skin incision is made using no.11 blade with depth of incision extending to pectoral fascia or onto subcutaneous tissue in event of autologous tissue breast shape reconstruction (Figure 3). The base of the L pedicle is measured to be equal to the nipple diameter to be created. The short arm lies opposite to the pedicle (Figure 3). The long arm of the L flap is based on a laterally based random flap and is one and half to two times the diameter of the nipple. The marked long arm is raised and rotated through 180 degrees, and sutured (Figure 4) with absorbable 4-0 monocryl (poliglecaprone 25, Ethicon) sutures. The short arm is then sutured to the upper border of long arm to create the summit of the neo nipple and hence fashioned to create a projecting neo-nipple (Figure 4).



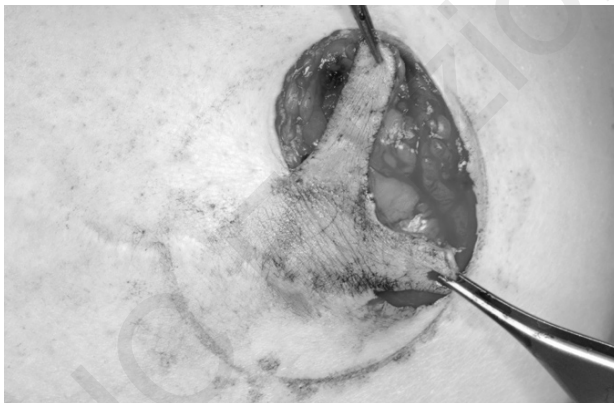
**Figure 2 - Pre-operative markings for L flap nipple and areola.**



**Figure 4 - Neo-nipple inset and creation of base for areola.**



**Figure 5 - De-epithelialised neo-areolar base.**



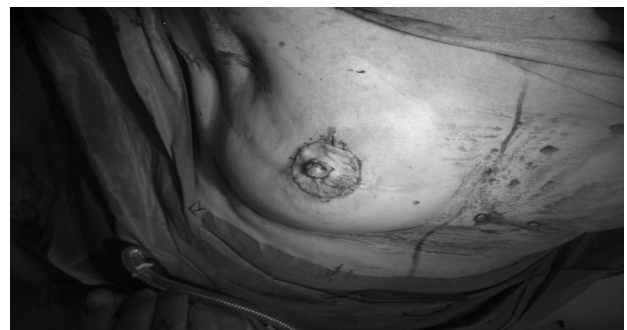**Figure 3 - Details of raising the L flap.**

The area surrounding the reconstructed nipple site is de-epithelialised to match the areola on the native breast and this forms the first step in preparing the areolar base (Figure 5).

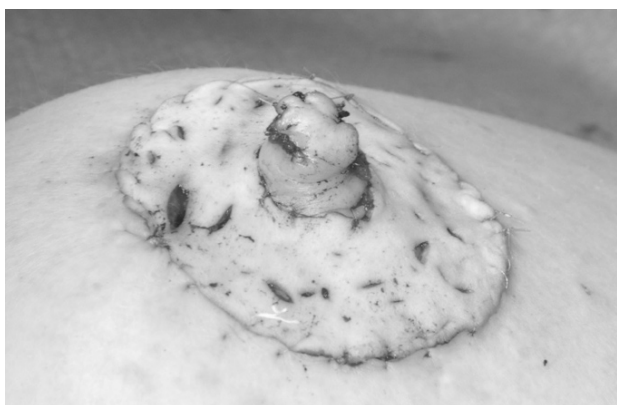
The next step involves harvesting and preparing the areolar graft from abdomen or from skin envelope of the opposite breast. The skin graft is then fashioned and placed over the raw surface to recon-

struct the neo-areola (Figure 6), using absorbable 4-0 monocryl.

The full thickness graft is fenestrated to facilitate drainage of serous collection or blood, which would ensure very low infection rates. The additional value of designing small openings in the graft is that it eventually generates the appearance of Montgomery tubercles over the neo-areola (Figure 7).



**Figure 6 - Full thickness skin graft to create neo areola.**



**Figure 7 - A per op view of neo nipple and neo areola with typical fenestrations.**

An interrupted 4-0 monocryl suture is used to secure the skin to the graft. Once the graft is secured, the entire neo nipple/areolar complex is covered with mepitel (safetac; molnlycke) or jelonet (steroplast), covered with surgical gauze with a central button hole; all held together with clear Tegaderm Hydrocolloid dressings. Tegaderm (3M) backing allows the patient to shower, easy to use and can be applied one-handed. The dressing is left intact for 10 days until the outpatient clinic review, wherein all 31 patients were reviewed by the Surgeon.

Prophylactic antibiotics are administered, with Co-amoxiclav (500mg/125mg) being our antibiotic of choice. In patients with allergies to Penicillin, we found macrolide antibiotics such as Erythromycin or Clarithromycin helpful.

## Statistical analysis

The data of complications from concurrently performed traditional CV flap was compared with the

novel L-flap technique.

The categorical data were summarised using frequencies, percentages, cross tabulation and bar chart and analysed by Fisher's Exact test. All statistics and analyses were produced using IBM SPSS version 20.

## Results

A total of 31 patients met inclusion criteria (previous transverse mastectomy scar and not deemed suitable for CV flap nipple-areola reconstruction) and were evaluated. The mean age of patients identified was 44 years (range, 33 to 64 years) and the mean body mass index was 28 (range, 24 to 32). Patients displayed minimal medical co-morbidities, and there were no patients who were actively smoking at the time of surgery.

All patients had undergone total mastectomy and had well healed transversely placed chest wall scars. Twelve patients (38.7%) were treated with chemotherapy (Adriamycin with or without Paclitaxel) and none of the thirty-one patients underwent external beam irradiation.

Intra-operatively, all patients underwent L-shaped flap nipple reconstruction with areolar skin graft from abdomen or contralateral breast, with technique as described above.

As depicted in Table 1, below; the incidence of any complications, including infection, discharge, pain, bleeding, partial or total nipple loss; as compared with traditional CV flap were similar and no statistically significant difference (Fisher's Exact test).

Table 2 summarises the patients' undergoing L flap showed good cosmetic outcomes in comparison

TABLE 1 - COMPLICATIONS: L FLAP AND CV FLAP NIPPLE RECONSTRUCTIONS COMPARED.

Complications	L flap (n=31)	CV flap (n=59)	P-value(Fisher's Exact test)
Superficial Nipple tip necrosis	3 (10%)	6 (10%)	P=1.0
Cellulitis	2 (6%)	3 (5%)	P=1.0
Pain	2(6%)	5 (8%)	P=1.0
Bleeding/haematoma	1 (3%)	3 (5%)	P=1.0
Partial nipple loss	2 (6%)	2 (3%)	P=0.60
Surgical revision	2 (6%)	3 (5%)	P=1.0

TABLE 2 - PROMS (PATIENT REPORTED OUTCOME MEASURES) IN EACH OF THE TECHNIQUES.

	<b>L flap (n=31)</b>	<b>CV flap (n=59)</b>	<b>P-value</b>
Overall Cosmetic Outcome - Satisfied/ Very Satisfied	90% (n=28)	86% (n=51)	P=0.74
Wearing daily clothes-Confident/Very Confident	81%(n=25)	69%(n=41)	P=0.32
Wearing Swim Clothes-Confident/Very Confident	77%(n=24)	63%(n=37)	P=0.24
Wearing Night Clothes-Confident/Very Confident	71%(n=22)	63%(n=37)	P=0.49
Nipple Reconstruction-Good/Very Good Match to opposite side	77%(n=24)	69%(n=41)	P=0.47

TABLE 3 - COMPARISON OF NIPPLE PROJECTION BETWEEN TWO COHORTS.

<b>Nipple Projection</b>	<b>L flap</b>	<b>CV flap</b>
Immediate post op	4 - 5 mm (4.5mm)	5 - 6 mm (5.5mm)
6 months follow up	3 - 5 mm (4 mm)	4 - 5 mm (4.5 mm)
24 months follow up	2 - 4 mm (3 mm)	2 - 4 mm (3 mm)

with patients' undergoing CV flap in the same breast Unit during the same period of time as the study cohort.

Table 3 shows that nipple projection in the study cohort of L flap compared favourably with patients' undergoing traditional CV flap, over 6 and 24 months.

## Discussion

Nipple reconstruction and patient satisfaction outcomes study seem to be an area of very limited research and hence lack of evidence-based scientific literature. While nipple reconstruction is considered a minor procedure, its profound implications on patient satisfaction after post-mastectomy breast reconstruction have been clearly demonstrated (9,10).

A vast majority of contributions related to nipple reconstruction merely focus on surgical techniques. Literature review has shown a major emphasis of articles has been on ways to prevent the inevitable loss of nipple projection (11-16). This is in contrast to the limited number of studies analysing risk factors and complication rates after nipple reconstruction (13, 17).

It is prudent, however, to not only concentrate on preservation of nipple projection but also analyse and

identify factors that predict poor outcome, as complications after nipple reconstruction can have devastating consequences for patients.

It is reasonable for the patient undergoing breast shape reconstruction to expect the same high standards of nipple-areolar reconstruction as the breast mound itself (18). Hence it would be prudent to give the greatest consideration to the position of the new nipple-areola complex and to the symmetry on the other side. It is important to assert that nipple-areola reconstruction represents the final stage of breast reconstruction, whereby a reconstructed breast mound is transformed into a breast facsimile that more closely resembles the original breast. Shestak et al. in their salient review of Assessment of Long-Term Nipple Projection - A Comparison of Three Techniques, using either a bell flap, a modified star flap, or a skate flap and full-thickness skin graft for areola reconstruction, note that loss of nipple and areola projection was quite remarkable using the bell flap and hence would discourage its use in virtually all patients requiring nipple-areola reconstructions (19). They find the other two techniques reviewed, i.e., modified star flap and skate flap with full-thickness skin graft for areolar reconstruction, to be more suitable in a variety of situations to maintain long term nipple projections (19).

The complexity and outcomes of the creation of a

new nipple areola following cancer surgery is succinctly demonstrated by Sisti et al. (20) In their seminal review of literature, the authors having thoroughly analysed 75 papers published over 69 years, and have observed that *flaps* have held the “*test of time*” in nipple reconstructions. Overcorrection of nipple projection (up to 50%), in suitable patients, to prevent long term loss of nipple projection is an interesting observation in this review. In this context, being informed and sharing decision making with patients, helps patient empowerment and improves overall satisfaction. This concept could support future studies involving techniques, outcomes and influence patient confidence which would all further enhance patient safety.

This novel L-flap nipple reconstruction was devised and developed at Liverpool Breast Unit, to provide a viable and robust alternative to traditional flaps and keeping with patient’s expectations and interest. This technique seems a very useful resource considering several criteria it should fulfil to near match contralateral native nipple areolar complex or a previously reconstructed neo-nipple. Our clinical observation over the years of an unsatisfactory nipple position with traditional CV flap, in people with transversely placed mastectomy scar, has led us to develop this innovative L flap. The outcomes of PROMs (patient reported outcome measures), in addition to our clinical observation of a better and satisfactory nipple position achieved with L flap have supported our journey to develop this L flap.

Our choice of creating Neo-areola by means of a full-thickness graft has resulted in a better colour match and projection compared with other techniques, such as tattooing.

In this study we have noted complication rates in all our L-shaped flaps are not significantly different from the traditional and well established CV flap. There was no statistically significant difference in complication rates between both types of nipple reconstruction, although perceived clinical difference should be individually addressed. These outcomes

support our nascent work of developing a technique to enhance patient satisfaction

We acknowledge the study limitations being small population sizes and intermediate follow up period. A larger group of patients and a longer follow up will help us draw conclusions, with particular attention to nipple projection. Analysing the patient feedback and reflecting on the overall outcomes, we are pleased that we have developed and presented a novel technique to enhance patient care and safety. This provides further stimulus to our ongoing service improvement project keeping In line with modern National Health Services “Patient Centred Care”.

## Conclusions

This novel design for nipple-areola complex reconstruction can be used in either primary or secondary nipple reconstruction. Of particular and distinct advantage is that all the scars are contained within the peripheral peri-areolar incision and thus can be completely camouflaged by an intra-dermal tattoo. Nipple projection has been consistently maintained and outcomes are reasonable and are similar to that of a CV flap. The creative use of patient’s own tissue expands the utility of the L flap beyond its current application in poorly placed transverse mastectomy scars.

---

### Conflict of interest statement

Krishnamurthy Sreedhar Murthy: None

### Funding

None.

### Acknowledgements

We acknowledge Dr Poornima Murthy BDS, MPH, FRSH for her help in manuscript preparation and graphics.

Thanks to Mr MV Chandrashekar for sharing the pictures of L Flap nipple reconstruction

## References

1. Bogue DP, Mungara AK, Thompson M, Cederna PS. Modified Technique for Nipple-Areolar Reconstruction: A Case Series.

Plastic & Reconstructive Surgery. October 2003 112(5):1274-1278.

2. Farhadi J, Maksvytyte GK, Schaefer DJ, Pierer G, Scheufler O. Reconstruction of the nipple-areola complex: An update. *J Plast Reconstr Aesthet Surg.* 2006;59:40-53.
3. Shestak KC, Nguyen TD. The double opposing periareola flap: A novel concept for nipple-areola reconstruction. *Plast Reconstr Surg.* 2007;119:473-80.
4. Eo S, Kim SS, Da Lio AL. Nipple reconstruction with C-V flap using dermofat graft. *Ann Plast Surg.* 2007;58:137-40.
5. Schoeller T, Schubert HM, Pulzl P, et al. Nipple reconstruction using a modified arrow flap technique. *Breast.* 2006;15:762-8.
6. Germano D, De Biasio F, Piedimonte A, et al. Nipple reconstruction using the fleur-de-lis flap technique. *Aesthetic Plast Surg.* 2006;30:399-402.
7. Gamboa-Bobadilla GM. Nipple reconstruction: The top hat technique. *Ann Plast Surg.* 2005;54:243-6.
8. Rubino C, Dessy LA, Posadinu A. A modified technique for nipple reconstruction: The 'arrow flap'. *Br J Plast Surg.* 2003;56:247-51.
9. Losken A, Mackay GJ, Bastwick J. Nipple reconstruction using C-V flap technique: A long-term evaluation. *Plast Reconstr Surg.* 2001;108:361.
10. Shaikh-Naidu N, Preminger BA, Rogers K, Messina P, Gayle LB. Determinants of aesthetic satisfaction following TRAM and implant breast reconstruction. *Ann Plast Surg.* 2004;52:465-470. discussion 470.
11. Shestak KC, Gabriel A, Landecker A, Peters S, Shestak A, Kim J. Assessment of long-term nipple projection: a comparison of three techniques. *Plast Reconstr Surg.* 2002;110:780-786.
12. Shestak KC, Nguyen TD. The double opposing periareola flap: a novel concept for nipple-areola reconstruction. *Plast Reconstr Surg.* 2007;119:473-480.
13. Zhong T, Antony A, Cordeiro P. Surgical outcomes and nipple projection using the modified skate flap for nipple-areolar reconstruction in a series of 422 implant reconstructions. *Ann Plast Surg.* 2009;62:591-595.
14. Rosing JH, Momeni A, Kamperman K, Kahn D, Gurtner G, Lee GK. Effectiveness of the Asteame Nipple Guard(TM) in Maintaining Projection Following Nipple Reconstruction: A Prospective Randomised Controlled Trial. *J Plast Reconstr Aesthet Surg.* 2010;63(10):1592-1596.
15. Eo S, Kim SS, Da Lio AL. Nipple reconstruction with C-V flap using dermofat graft. *Ann Plast Surg.* 2007;58:137-140.
16. Jones AP, Erdmann M. Projection and patient satisfaction using the "Hamburger" nipple reconstruction technique. *J Plast Reconstr Aesthet Surg.* 2012;65:207-212.
17. Draper LB, Bui DT, Chiu ES, et al. Nipple-areola reconstruction following chest-wall irradiation for breast cancer: is it safe? *Ann Plast Surg.* 2005;55:12-15.
18. Little JW III. Nipple-areola reconstruction. *Plastic & Reconstructive Surgery.* 1985;76(5):806.
19. Shestak KC, Gabriel A, Landecker A, Peters S, Shestak A, Kim J. Assessment of long-term nipple projection: A comparison of three techniques. *Plast Reconstr Surg.* 2002;110:780.
20. Sisti A, Grimaldi L, Tassinari J, Cuomo R, Fortezza L, Bocchiotti MA, Roviello F, D'Aniello C, Nisi G. Nipple-areola complex reconstruction techniques: A literature review. *Eur J Surg Oncol.* 2016 Apr;42(4):441-65.