

Hyperbaric oxygen therapy in Plastic Surgery practice: case series and literature overview

F. BASSETTO¹, G. BOSCO², T. BRAMBULLO¹, E. KOHLSCHEEN¹,
I. TOCCO-TUSSARDI¹, V. VINDIGNI¹, C. TIENGO¹

SUMMARY: Hyperbaric oxygen therapy in Plastic Surgery practice: case series and literature overview.

F. BASSETTO, G. BOSCO, T. BRAMBULLO, E. KOHLSCHEEN, I. TOCCO-TUSSARDI, V. VINDIGNI, C. TIENGO

Hyperbaric oxygen therapy (HBOT) is the use of 100% oxygen at pressures more than atmospheric. Several approved applications and indications exist for HBOT in the literature. Non-healing wounds, such as diabetic and vascular insufficiency ulcers, have

been a major area of application, and the use of HBOT as an adjunct has been approved by several studies and trials. HBOT is also indicated for acute soft tissue infections like clostridial myonecrosis, necrotising soft tissue infections, as also for traumatic wounds, crush injury, compartment syndrome, and compromised skin grafts and flaps. Another major area of application of HBOT is radiation-induced wounds. With increasing availability of chambers and studies proving the benefits of use, HBOT should be considered as an essential part of the overall management strategy for plastic surgeons.

KEY WORDS: Application - Guidelines - Hyperbaric medicine - Hyperbaric oxygen therapy - Indication - Plastic reconstructive surgery.

Introduction

Hyperbaric oxygen therapy (HBOT) is defined as breathing pure (100%) oxygen while under increased absolute atmospheric pressure (ATA). The first record of use of air at raised ambient pressure for the treatment of illnesses can be traced back to 1662, when the British clergyman Henshaw developed an airtight chamber (the *domicilium*) in which the atmosphere could be compressed and decompressed using oxygen bellows and valves; but it was not until the 19th century that the first successful employment was achieved by Benke and Shaw with resolution of decompression sickness (1).

The era of modern-generation hyperbaric chambers begins in 1955, when Churchill-Davidson et al. began to use oxygen therapy in a hyperbaric cham-

ber to treat radiotherapy-induced damage in cancer patients. After encouraging reports, there was an upsurge in the number of chambers and applications; however, reports of use of HBOT without sound rationale (e.g. as anti-aging treatment) led to calls for better regulation during the 1960s (1, 2).

The Undersea and Hyperbaric Medical Society (UHMS) was established in 1967 with the rationale of giving HBOT a full professional status in terms of regulation, staffing, training, and certification. UHMS acts as the primary scientific body for HBOT in the USA and provides with a list of emergent and non-emergent applications proved by reasonable scientific evidence or clinical experience (3). These indications had also been subsequently supported by the British Hyperbaric Association (4). Most recently, the 2016 European consensus conference recommended HBOT for some additional conditions based on sufficient evidence in the form of expert consensus opinion (5).

The generic application of HBOT is in clinical conditions characterized by an imbalance between the oxygen request and supply. HBOT is adminis-

¹ Clinic of Plastic and Reconstructive Surgery, Department of Neurosciences, University Hospital of Padova, Padova, Italy

² Department of Physiology, University of Padova, Padova, Italy

Corresponding author: Ilaria Tocco-Tussardi,
e-mail: ilaria.tocottussardi@gmail.com

tered inside chambers that are pressurized using air or oxygen to pressures more than atmospheric. Broadly, there are two types of chambers: multi-place, which can hold more than one patient; and monoplace chambers, designed to cater for a single patient. Administration, commonly referred to as a “compression”, involves pressurization between 2.0 and 3.0 ATA and the average duration of therapy is 60-90 min. Number of therapies may vary from 3 to 5 for acute conditions to 50-60 for radiation illnesses. Treatments are administered once or twice a day. Overall, the modality of administration is highly variable, depending not only on the clinical indication, but also on the patient’s conditions.

HBOT mechanisms of action

In normobaric conditions, we live at 1 ATA of pressure measured at the sea level, meaning that downward pressure exerted on a body equals the weight of the atmosphere above a body. Commonly, the atmospheric pressure is measured in millimetres of mercury, where 1 ATA is equal to 760 mm Hg, 1.101 bar, 14.7 psi, 760 torr, or 10 m of seawater.

The physics behind HBOT lies within the ideal gas laws, Boyle and Henry laws. Boyle law states that the absolute pressure exerted by a given mass of gas is inversely proportional to the volume it occupies (if the temperature and amount of gas remain unchanged):

$$PV=k$$

and Henry law states that the amount of dissolved gas is proportional to its partial pressure in the gas phase:

$$C=kP_{\text{gas}}$$

The application of Boyle law is seen in many aspects of HBOT. This can be useful with embolic phenomena such as decompression sickness or arterial gas embolism, as the volume of a bubble decreases directly in proportion to increasing pressure. On the other hand, Henry law accounts for the increase in oxygen dissolved in the plasma by increasing the atmospheric pressure in the chamber. Thus, the dissolved plasma oxygen concentration of 0.3 ml/dL at

1 ATA increases to 1.5 ml/dL upon administration of 100% oxygen, while hyperbaric oxygen delivered at 3 ATA yields a dissolved oxygen content of 6 ml/dL. The raise in the partial pressure of oxygen in the blood, and subsequently in tissues, has been shown to have many downstream biological effects:

- Neovascularization: regional angiogenic stimuli influence the efficiency of new blood vessel growth by local endothelial cells (termed *angiogenesis*); and they stimulate the recruitment and differentiation of circulating stem/progenitor cells (SPCs) to form vessels *de novo* in a process termed *vasculogenesis* (6-11). HBOT has effects on both these processes, as an effect of an increased oxygen gradient between the centre and periphery of the wound. In an *in vivo* mouse model and in an experimental wound, HBOT directly promoted neovascularization in a dose-dependent manner, which peaked at 2.5 ATA. The Authors postulated the cyclic nature of HBOT facilitates the process since neovascularization requires collagen to form microvessel tubes, with procollagen forming during periods of hypoxia, and collagen export and maturation occurring during hyperoxic periods (12). Vascular endothelial growth factor (VEGF) and angiopoietin, as well as stromal derived factor-1 (SDF-1) influence SPCs homing to wounds and SPCs differentiation to endothelial cells (13, 14). Synthesis of VEGF has been shown to be increased in wounds by HBO: in a rat model, HBOT applied at 2.1 ATA twice per day for 7 days significantly increased VEGF within wounds (15). HBO also stimulates synthesis of basic fibroblast growth factor (bFGF) and transforming growth factor β 1 by human dermal fibroblasts (16), angiopoietin-2 by human umbilical vein endothelial cells (17), bFGF and hepatocyte growth factor in ischemic limbs (18), and it up-regulates platelet derived growth factor receptor in wounds (19).
- Reduction of inflammation: an early event associated with post-ischemic tissue reperfusion is the adherence of circulating neutrophils to vascular endothelium by β 2 integrins and extravasation from capillaries, leading to what is known as ‘ischemia-reperfusion injury’ (20). When animals or humans are exposed to HBO at 2.8 to 3.0 ATA for at least 45 minutes, the ability of

circulating neutrophils to adhere to target tissues is temporarily inhibited, as part of a general response, protecting endothelium, reducing its porosity, and hence reducing interstitial edema (20-23). In animal models, HBO-mediated inhibition of neutrophil $\beta 2$ integrin adhesion has been shown to ameliorate reperfusion injuries of brain, heart, lung, liver, skeletal muscle and intestine, as well as smoke-induced lung injury and encephalopathy due to carbon monoxide poisoning (11, 24-31).

- Control of infection: HBOT may promote the efficiency of leukocytes to kill pathogens by phagocytosis. Phagocytosis requires large quantities of oxygen to form reactive species such as free radicals, to inactivate pathogens within phagosomes. This mechanism is blunted in a hypoxic environment: HBOT increases the generation of oxygen free radicals, which oxidize proteins and membrane lipids, damage DNA, and inhibit bacterial metabolic functions (32). Superoxide dismutase, catalase, and glutathione reductase keep the formation of these radicals in check until the oxygen load overwhelms the enzymes, leading to the detrimental effects on cell membranes, proteins, and enzymes (32, 33). In a rabbit experimental model of osteomyelitis, *Staphylococcus aureus* inoculum decreases after exposure to hyperoxia (150 mm Hg) (34). This suggests HBOT could help the host to overcome infection within hypoxic soft tissue and bone. Control of anaerobic organisms is also achieved by HBOT by suppression of clostridial α -toxin production in gas gangrene (34, 35). Moreover, the efficacy of antibiotics has been reported to improve in the hyperbaric environment: the activity of aminoglycosides and antimetabolite agents such as trimethoprim, sulfamethoxazole, and sulfasoxazole all showed an increase in effectiveness with high oxygen tensions (36, 37).
- Promotion of wound healing: animal trials have documented wound healing benefits of HBO (38-40). The basis for its efficacy continues to be investigated and appears to be a combination of systemic events as well as local alterations within the wound margin. In the early wound repair phase, fibroblasts repopulate and proliferate within the wound bed. There is evidence that HBOT facilitates this process. Fibroblasts proliferate

increases in a dose-dependent manner between 1.0 and 2.5 ATA. This occurs for both normal and diabetic skin fibroblasts (34).

Fibroblasts participate in wound repair by synthesis of collagen. Procollagen is formed in a hypoxic environment. However, maturation of collagen requires oxygen: HBOT promotes polymerization and cross-linking of collagen in a dose-dependent manner. This process involves proline hydroxylation: proline hydroxylase uses oxygen as a substrate and is maximally active at 225 mm Hg and higher (34).

Extracellular matrix formation is closely linked to neovascularization and it is another oxygen-dependent process (12). Enhanced collagen synthesis and cross-linking by HBO₂ have been described, but whether changes are linked to the oxygen-dependence of fibroblast hydroxylases, alteration in balance of wound growth factors, metalloproteinases and/or inhibitors of metalloproteinases, is as yet unclear (12, 41).

HBOT in plastic surgery

HBOT and plastic surgery are tightly connected: a large number of conditions treated by this surgical specialty are eligible to benefit from HBO as adjunct treatment. In 2015, the Italian Undersea and Hyperbaric Medicine Society updated its current indications for HBOT (42). Applications related to plastic surgery are several (Table 1) and discussed below.

Acute soft tissue infections (clostridial myositis and myonecrosis, necrotizing soft tissue infections)

HBOT, combined with antibiotics and surgical removal of dead tissue, is an effective treatment for severe soft tissue infections.

Clostridial myositis and myonecrosis (gas gangrene). Gas gangrene is a fulminating, soft-tissue infection with gram-positive anaerobic bacilli of the species *Clostridium*, notably *Cl. perfringens*. The skin, subcutaneous fat and muscle may all be affected. The majority of cases are the consequence of contamination of traumatic wounds, where the initial cause of necrosis is not the microorganism itself, but the fact that tissue damage has resulted in locally hypoxic tissue, so allowing *Clostridium* to thrive (43). Bacteria then produce the α -toxin, which causes the necrosis.

TABLE 1 - APPLICATIONS OF HBOT RELATED TO PLASTIC SURGERY ACCEPTED BY THE ITALIAN UNDERSEA AND HYPERBARIC MEDICINE SOCIETY.

	Inclusion criteria	Protocol	Clinical considerations	Exclusion criteria	References
Acute conditions					
Acute soft tissue infections (clostridial myositis and myonecrosis, necrotizing soft tissue infections)	Strong indication for treatment in case of myositis – myonecrosis and necrotizing fasciitis. Optional treatment to be considered on a case-by-case fashion for dry gangrene (diabetic) and necrotizing soft tissue infections other than fasciitis.	During the first 3 days, the maximum dose of oxygen is advisable (2.8 ATA, 2-3 sessions / day) according to the clinical conditions. From day 4: daily treatment (once or twice a day depending on the clinical evolution), with sessions at 2.4-2.8 ATA and variable duration between 80 and 120 min., until the infection is resolved. The number of sessions varies between 20 and 40 depending on the clinical scenario.	HBOT should be an adjunct to surgical debridement / treatment, targeted wound care, and antibiotic therapy.	General conditions contraindicating treatment. PaO ₂ /FiO ₂ < 200.	48-54, 58, 113, 114
Crush injuries – severed fractures	Mangled Extremities Severity Score (MESS) (Table 2): <ul style="list-style-type: none"> • 3-6: Treatment indicated in presence of diabetes mellitus, peripheral vascular disease, and disorders of the connective tissue. • ≥7: Treatment mandatory for all patients. Gustilo Classification (Table 3): <ul style="list-style-type: none"> • II-III A: Treatment indicated in presence of risk factors (diabetes mellitus, peripheral vascular disease, and 	Pressure ≥ 2.4 ATA. Depending on the clinical scenario, it might be advisable to treat twice a day in the first 5-6 days. Number of compressions: 10-12.	New clinical assessment after 1 0-12 compressions: <ul style="list-style-type: none"> • If the injury is healed, HBOT can be stopped. • If the injury has improved but not fully healed yet, HBOT should be continued (daily treatment for 15 days). • In case of complications (e.g. development of osteomyelitis) or no response to treatment, HBOT should be stopped and specialists should be consulted. 	General conditions contraindicating treatment. PaO ₂ /FiO ₂ < 200.	59-67, 115, 116

To be continued

Continued from Table 1

- disorders of the connective tissue).
 IIB-IIC: Treatment mandatory for all patients.

Compromised flaps or grafts	<p>TcPO₂ around the flap/graft site \leq 30 mmHg within the first 36 post-op hours.</p>	<p>Pressure 2.4-2.5 ATA for at least 60 min. for a total of 5-10 compressions.</p>	<p>New clinical assessment after 5 compressions:</p> <ul style="list-style-type: none"> If the flap / graft has taken, HBOT can be stopped; If the flap / graft has partially taken (around 50%): <ul style="list-style-type: none"> - TcPO₂ \geq 30 mmHg: HBOT can be stopped; - TcPO₂ $<$ 30 mmHg: proceed with 5 more compressions at 2.2 - 2.5 ATA; In case of complications or no response to treatment, HBOT should be stopped and specialists should be consulted. 	<p>General conditions contraindicating treatment. PaO₂/ FiO₂ $<$ 200. Arterial or venous thrombosis (free flaps).</p>	68-75
-----------------------------	---	--	--	---	-------

Chronic conditions

Chronic refractory osteomyelitis	<p>Cierny – Mader Classification (Table 4): 3-4 BL/BS, 3 – 4 C.</p>	<p>The treatment is carried out at 2.4-2.5 ATA for a total of 30- 60 c ompressions.</p>	<p>HBOT should be performed both before and after tissue debridement (e.g. 40 HBOT sessions > intervention > 20 HBOT sessions).</p>	<p>General conditions contraindicating treatment. PaO₂/ FiO₂ $<$ 200.</p>	76-84
Chronic non-healing wounds	<ul style="list-style-type: none"> Peripheral arteriopathy (already revascularized) with TcPO₂ around the ulcer \leq 30 mmHg. Peripheral arteriopathy not eligible for revascularization, 	<p>Pressure 2.4 - 2.5 ATA for at least 60 min. for a total of 30- 40 compressions.</p>	<ul style="list-style-type: none"> It is mandatory to perform a vascular assessment of the ulcer before starting the treatment. Revascularization should be considered. Transcutaneous oxygen tension measurement 	<p>Cierny - Mader Classification A. General conditions contraindicating treatment. PaO₂/ FiO₂ $<$ 200. TcPO₂ $<$ 10 mmHg.</p>	9, 87-99

To be continued

Continued from Table 1

- TcPO2 \geq 10 mmHg, \leq 40 mmHg. Peripheral arteriopathy with TcPO2 \geq 50 mmHg during HBOT.

- serves as a guide for HBOT application.
- Reversibility of hypoxia predicts the utility of HBOT.

New clinical assessment after 15 compressions:

- If the patient is healed, HBOT can be stopped;
- If the patient is not healed:
 - TcPO2 \geq 40 mmHg: favorable outcome, HBOT can be stopped.
 - TcPO2 $<$ 30 mmHg: proceed with 15 more compressions at 2.2 – 2.5 ATA.
- In case of complications or no response to treatment, HBOT should be stopped and specialists should be consulted.

100-106

Pressure 2.4 – 2.5 ATA for a total of 40-60 compressions.

Radiation ulcers

Radiation injuries

- New clinical assessment after 30 compressions:
 - If the patient is healed, HBOT can be stopped;
 - If the patient is not healed:
 - TcPO2 \geq 40 mmHg: favorable outcome, HBOT can be stopped.
 - TcPO2 $<$ 40 mmHg: proceed with 20 more compressions at 2.2 – 2.5 ATA.
 - In case of complications or no response to treatment, HBOT should be stopped.

TABLE 2 - MANGLED EXTREMITY SCORING SCALE. ADAPTED FROM JOHANSEN ET AL. (117).

-
- A. Skeletal/Soft tissue Injury
1. Low energy (stab, simple fracture), low velocity (gunshot wound)
 2. Medium energy (open or multiple fractures)
 3. High energy (close range gunshot wound, crush injury)
 4. Very high energy (above + gross contamination, avulsion)
- B. Limb Ischemia (double time if ischemia time > 6 h)
0. Perfusion normal
 1. Pulse reduced/absent – perfusion still present
 2. No pulse, paresis, diminished capillary refill
 3. Cool, paralyzed, insensate, numb
- C. Shock
0. Systolic blood pressure always >90 mmHg
 1. Hypotension transiently
 2. Persistent hypotension
- D. Age
1. <30
 2. 30-50
 3. >50
-

TABLE 3 - HBOT THERAPY FOR FRACTURED CRUSH INJURY (GUSTILO CLASSIFICATION). ADAPTED FROM GUSTILO ET AL. (118).

Type	Characteristic	Infection Rate	Amputation Rate	Use of HBOT and Host Status		
				Normal Host	Impaired Host	Compromised Host
I	Small (<1 cm) laceration, from inside out	Almost nil	0	No	No	Yes
II	Laceration, with minimal soft tissue injury	3%	0	No	Yes	Yes
III-A	Crush with adequate soft tissue coverage	<10%	0	No	Yes	Yes
III-B	Crush with extensive soft tissue injury, insufficient to cover bone	52%	16%	Yes	Yes	Yes
III-C	Crush with major vascular injury	42%	42%	Yes	Yes	Yes

TABLE 4 - CIERNY-MADER STAGING SYSTEM. ADAPTED FROM CIERNY ET AL. (116).

Anatomic Type	
Stage 1: Medullary osteomyelitis	
Stage 2: Superficial osteomyelitis	
Stage 3: Localized osteomyelitis	
Stage 4: Diffuse osteomyelitis	
Physiologic class	
A host: Normal host	
B host	
Systemic compromise (Bs)*	
Local compromise (Bl)*	
Systemic and local compromise (Bls)*	
C host: Treatment worse than the disease	
Systemic or local factors that affect immune surveillance, metabolism, and local vascularity	
Systemic (Bs)	Local (Bl)
Malnutrition	Chronic lymphedema
Renal or hepatic failure	Venous stasis
Diabetes mellitus	Major-vessel compromise
Chronic hypoxia	Arteritis
Immune disease	Extensive scarring
Malignancy	Radiation fibrosis
Extremes of age	Small-vessel disease
Immunosuppression or neuropathy	Complete loss of sensation
Immune deficiency	Tobacco abuse

The toxin is not only hemolytic but also has phospholipase activity, with consequent activation of inflammatory pathways causing increased vascular permeability. This results in edema of the affected tissues, which in turn contributes to hypoxia, so facilitating the further multiplication of the bacteria (44).

Appropriate surgical management with antibiotic therapy should constitute the first line of management. At tissue oxygen tensions in excess of 250mmHg, α -toxin production is halted within minutes of commencing hyperbaric oxygen therapy (28, 45). The combination of HBOT and surgery has been demonstrated to be synergistic in reducing both mortality and morbidity, since the need for extensive debridement and amputation is significantly reduced, with viable and non-viable tissue being more strongly demarcated, thus making possible more accurate tissue debridement (46). It has therefore been proposed that, where there is close contact between surgical and hyperbaric facilities, the initial surgical management should be limited to fasciotomy, with debridement of necrotic tissue performed later, after treatment with hyperbaric oxygen ther-

apy (47). The extent of ablation might be reduced if early HBO treatment is used to halt progression of the infection.

Necrotizing soft tissue infections (NSTIs). NSTIs are a rare spectrum of rapidly progressive infections that are highly destructive of skin, fascia, and surrounding tissue, with approximately 500 to 1500 cases reported annually in the US (48). Despite aggressive therapy, including emergent surgical debridement and broad-spectrum antibiotic use, mortality remains as high as 76% in some series (48-51). The literature surrounding the use of HBOT in STIs is mixed. The majority support the use of adjunctive HBOT to reduce mortality in NSTIs. Several case series and retrospective cohort studies report lower than expected mortality relative to published mortality rates from earlier series of NSTI patients treated with surgery and antibiotics alone (52-54). On the other hand, other studies have reported that use of HBO appears to provide no mortality benefit and may be associated with increased morbidity (e.g. increase in the number of operative debridements needed) (55-57). A recent retrospective analysis on the topic concluded that no statistically

significant differences in mortality or amputation rate could be found between patients who underwent HBO treatment and those who did not (58). Nonetheless, the Authors agreed that given the theoretical advantages of HBO, it should be considered as an adjunctive therapy in NSTI patients who have been surgically debrided and medically optimized.

Crush injuries - severed fractures

HBO can be used as adjunctive therapy for trauma patients with crush injury, compartment syndrome, and acute traumatic peripheral ischemia (59, 60). The rationale is the need to counter the effects of tissue hypoxia arising as a direct consequence of vascular injury and as a secondary consequence of trauma and infection. The unifying factors among these various conditions include a self-perpetuating cycle of ischemia, edema, and injury gradient (20).

Crush injury/Compartment syndrome. Three aspects of a diffuse crushing injury contribute to the development of compartment syndrome: (1) tissue destruction, (2) type of tissue involved, and (3) gradient of injury. Tissue is destroyed at the site of injury: the extent of this destruction depends on the acceleration/deceleration force applied to the tissue. The goal of therapy is to limit the spread of injury (59-61). The rationale for using HBO in crush injury and compartment syndrome has been outlined as follows:

1. Vasoconstriction: vasoconstriction occurs as a protective reaction to hyperoxia. A 20% reduction in blood flow lessens extravasation of fluid and thus edema, with reduced collapse of capillaries. The net effect is an increase in oxygenation to the tissues, with improvement in microcirculation (60).
2. Cellular function: with enhanced oxygenation at the injury zone, host factors related to healing and infection control come into play. Tissue oxygen levels less than 30 mm Hg inhibit fibroblast proliferation, which in turn inhibits neovascularization and repair (see above) (34, 38-40).
3. Inhibition of infection (see above) (32-27).
4. Mitigation of reperfusion injury (see above) (20-31).

Severed fractures. HBOT effect on bone tissue has been heavily investigated and reported in the literature. Basset demonstrated that cultures of multipotent mesenchymal cells can differentiate into bone

or cartilage depending on the oxygen tension (62). At increased oxygen tension with compression, there was an enhancement of bone formation, whereas reduced oxygen tension produced cartilaginous cells and tissues. These mesenchymal cells are found within the perivascular zone. Trueta demonstrated that pericytes from blood vessels act as osteoprogenitor cells (63). These pericytes are considered undifferentiated mesenchymal cells, which have the capacity to differentiate into various connective tissue forming cell types, including bone-forming osteoblasts. According to Hulth et al., vascularity is essential in the healing of all tissues except for cartilage (64). Jan et al. showed enhanced healing of supra-critical sized defects with HBOT even in the absence of bone grafts or bone substitutes (65, 66). Muhonen et al. investigated the effect of HBOT on the osteoblastic activity and angiogenesis in both irradiated and non-irradiated rabbit model subjected to mandibular distraction osteogenesis procedure. They found that HBO increased the osteoblastic activity in the irradiated rabbit model but not to the same level as in the non-irradiated controls (67).

Compromised flaps of grafts

HBOT is used on occasion to treat compromised flaps and grafts, where there is decreased perfusion or hypoxia, a practice supported also by the Guidelines from UHMS (3, 68-70). HBO can help maximize the viability of the compromised tissue thereby reducing the need for re-grafting or repeat flap procedures. A published prospective, blinded clinical trial showed that administration of HBO prior to and for three days following skin grafting led to a significant 29% improvement in graft survival (71). A problem with this trial, however, is that the success in the control arm of the study was markedly less than one would expect in current practice. As previously emphasized, support for use of HBO in flap/graft compromise comes from quite a number of studies (70, 72-75) but more work is needed.

Chronic refractory osteomyelitis

Refractory osteomyelitis is defined as a chronic osteomyelitis that persists (≥ 6 weeks) or recurs after appropriate interventions have been performed or where acute osteomyelitis has not responded to accepted management techniques. The pathophysiolo-

gy of chronic osteomyelitis is characterized by both acute and chronic sources of ischemia. The hypothesis that raising oxygen tension within the soft tissue and bone can enhance the treatment of chronic osteomyelitis stems from lines of evidence similar to those that exist in the many other conditions for which HBOT has been applied (76-78). HBOT has been shown to be effective in acutely reducing tissue edema, lowering intra-compartmental pressures and ameliorating the detrimental effects of inflammatory reactions; over the longer term, HBOT can be used to promote new collagen formation and capillary angiogenesis in both hypoxic bone and surrounding tissues; and this neovascularization works to counter the less easily reversible consequences of osteomyelitis, such as surgical trauma, tissue scarring and nutrient blood vessel occlusion. By creating a sustained increase in the arterial perfusion of previously hypoxic bone and soft tissues, HBOT can reduce the susceptibility of these tissues to recurrent infection and necrosis. Although high-quality clinical trials may not be available, several retrospective reports have been published in the recent literature (79-84). Despite the inherent weaknesses of these studies, they do suggest great potential for HBOT in the treatment of chronic osteomyelitis. In most cases, the best clinical results are obtained when HBOT is administered in conjunction with culture-directed antibiotics and scheduled to begin soon after thorough surgical debridement.

Chronic non-healing wounds (non-diabetic and diabetic)

The hypoxic nature of all wounds has been demonstrated, and the hypoxia, when pathologically increased, correlates with impaired wound healing and increased rates of wound infection. HBOT has been increasingly utilized in an adjunctive role in many of these scenarios including venous ulcers, pressure ulcers, diabetic foot ulcers, coinciding with optimized patient and local wound care (85-95).

Patients with wounds that fall within a category defined as potentially appropriate for adjunctive HBOT should be evaluated for likelihood of benefit. Hypoxia (i.e. wound PO₂ < 40 mmHg) generally best defines wounds appropriate for HBOT or rather, lack of hypoxia (i.e. wound PO₂ >40-50 mmHg) defines wounds potentially not appropriate

for HBOT. Breathing 100% oxygen at 1 ATA or under hyperbaric conditions can improve the accuracy of transcutaneous oximetry (PtcO₂) measurement in predicting successful healing with adjunctive hyperbaric oxygen treatment. The following conclusions were drawn from a study of 1144 diabetic foot ulcer patients who underwent adjunctive hyperbaric oxygen treatment in support of wound healing or limb salvage (96). PtcO₂ measured on air at sea level defines the degree of periwound hypoxia but has almost no value in predicting benefit with subsequent hyperbaric oxygen treatment. These measurements are more useful in predicting who will fail to heal without hyperbaric oxygen treatment. PtcO₂ values below 35 mmHg obtained while breathing 100% oxygen at sea level are associated with a 41% failure rate of subsequent hyperbaric oxygen treatment while values obtained greater than 35 mmHg were associated with a 69% likelihood of a beneficial response. PtcO₂ values measured during hyperbaric oxygen treatment exceeding a cutoff value of 200 mmHg were 74% reliable in predicting wound healing improvement or limb salvage as the result of a therapeutic course of hyperbaric oxygen. This positive predictive value is consistent with those reported by others in both arterial insufficiency and diabetic lower extremity wounds (97, 98). Lack of an increase in PtcO₂ to >100 mmHg appears to be an appropriate cut-off for predicting failure to heal, at least in ischemic diabetic foot ulcers. This requirement for achieving supra-physiologic wound oxygen concentration lends support to the argument that restoration of wound normoxia is not the primary mechanism of action of HBOT in healing hypoxic wounds. The failure rate for <100 mmHg is not 100%, however, so that it is not unreasonable to give a trial of HBOT (10-15 treatments) to such patients for whom the alternative is amputation (99).

Radiation injuries

Radiation complications are fortunately fairly rare, with most radiation oncologists willing to accept a 5% serious complication rate when treating with curative intent. HBO has been applied as a therapy for delayed radiation injury for more than 30 years, and soft-tissue and bony necrosis is one of the entities included as an approved indication in the Hyperbaric Oxygen Thera-

py Committee Report of the UHMS (100-106). In the U.S., third-party insurance entities will frequently reimburse for this application, but often a formal appeal will be required to obtain payment. In informal surveys of practitioners at continuing medical education meetings on HBO, it was consistently found that between one third and one half of US patients are treated for delayed radiation injuries (unpublished data). A recent comment on the topic by Feldeimer stated that 'Hyperbaric oxygen is a very safe therapy; its serious complications occur in fractions of a percentage point. It is not uncommon for patients to have myopic visual changes, but these are usually temporary. Treatments with HBO2 are expensive, but much less so than some of the newer cancer therapies, including intensity-modulated radiation therapy and the newer chemotherapy agents and marrow growth factors' (107). Because a consistent cause and manifestation of radiation injury is vascular obliteration and stromal fibrosis, the known impact of hyperbaric oxygen in stimulating neovascularization is an obvious and important mechanism whereby hyperbaric oxygen is effective in radiation injury.

HBOT report of treatment

The University Hospital of Padova is a public 1,400-bed tertiary care facility located in the northern-eastern Italy. It serves a population of approximately 1,000,000 inhabitants. In 2016-17, there were 110,380 urgent care records, and more than 60,000 patients were hospitalized. Among multiple services, the facility contains a state-of-the-art Hyperbaric Medicine Centre with dual chambers for capacity of 24 patients. From January 2006 to December 2015, the Clinic of Plastic Surgery of the Hospital referred 184 patients (≥ 18 -years of age) to the Hyperbaric Medicine Centre (mean of 18.9 ± 7.7 per year) (Figure 1). The population was male predominant (M=140) of mean age of 47 ± 17 years. Reasons for referral to HBO treatment are shown in Figure 2. More than half of patients (N=97, 52.7%) required HBO treatment for severed injuries of the upper or lower extremity (N=64 injuries of the lower extremity; N=33 injuries of the upper extremity) (Figures 3, 4 show sequential pictures of patients managed for complex injuries of the upper and low-

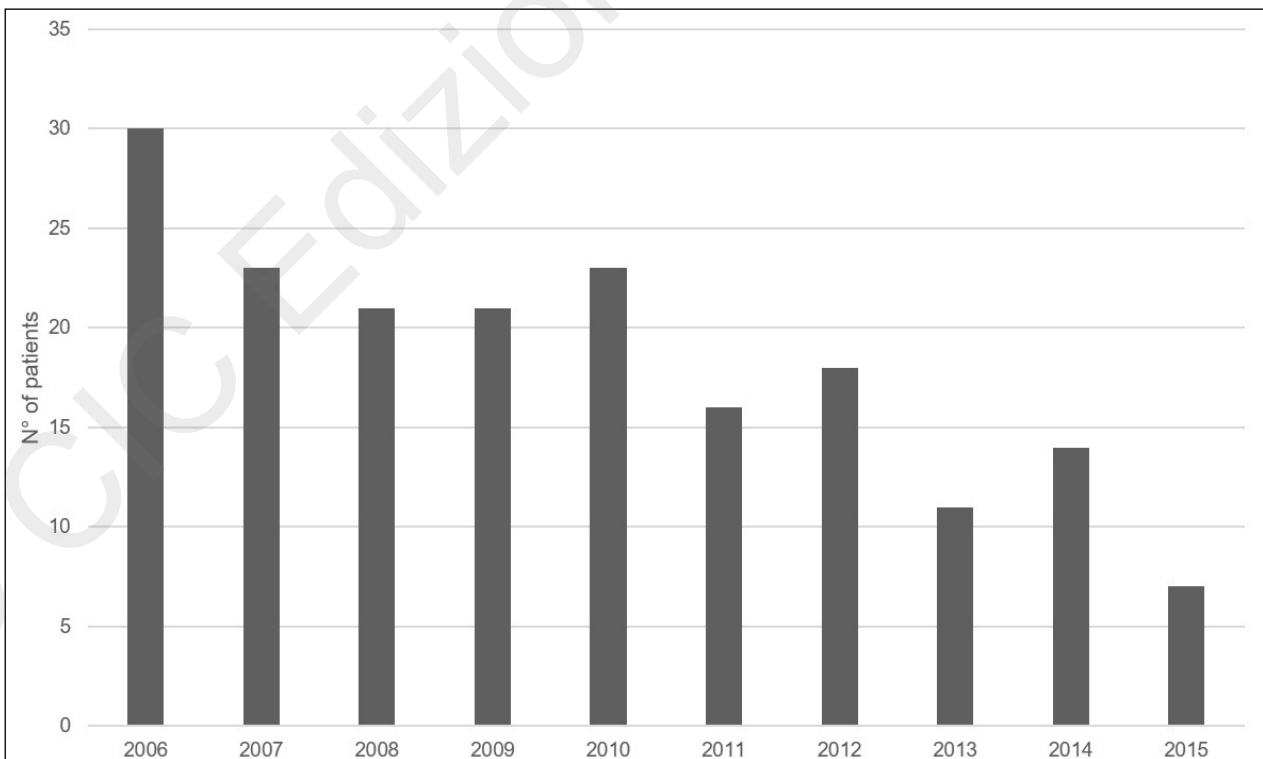


Figure 1 - Number of plastic surgery patients referred to the Hyperbaric Medicine Centre per year from January 2006 to December 2015.

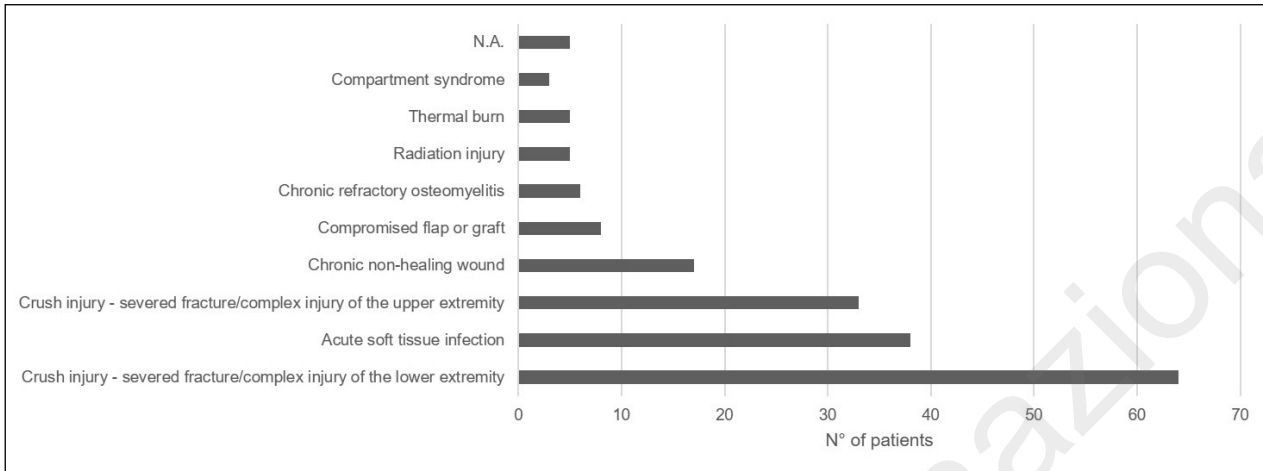


Figure 2 - Reasons for referral to HBO therapy for the patient population.

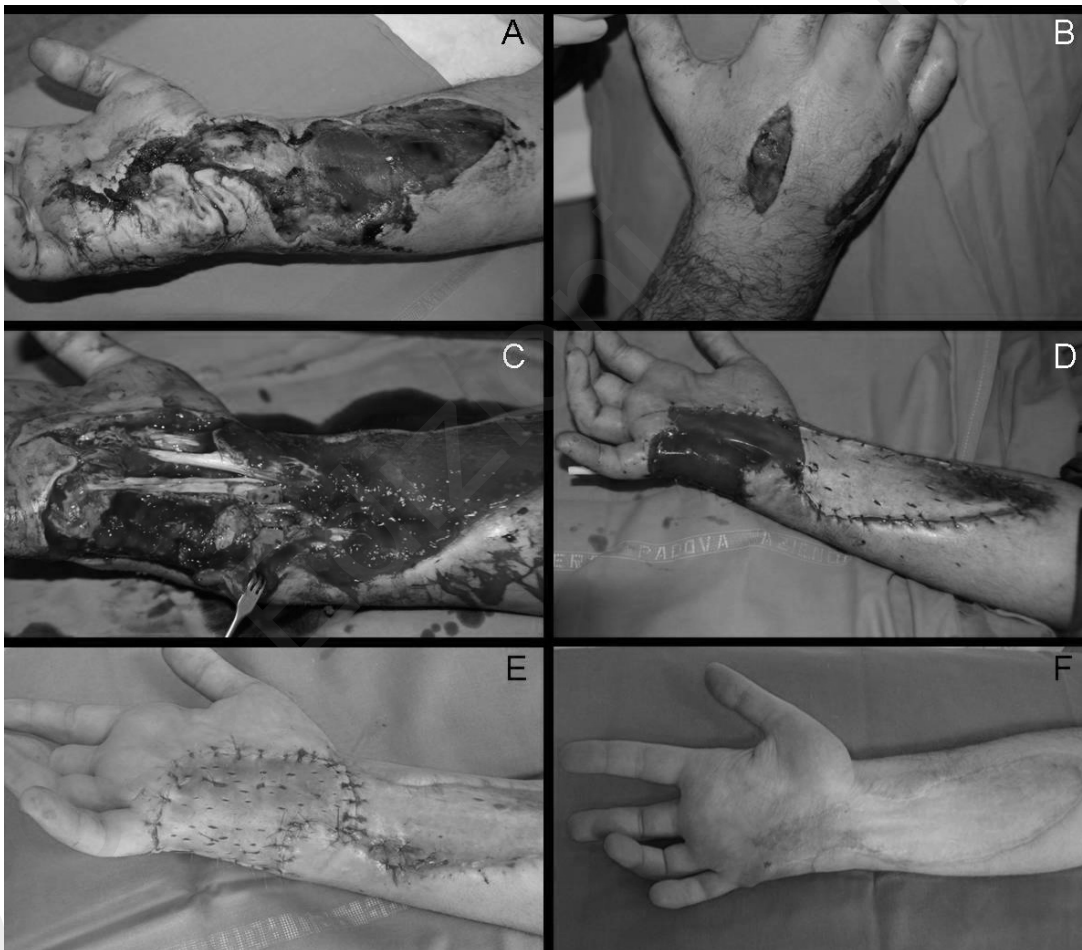


Figure 3 - Age: 27-year old. Gender: M. Indication for HBOT: High-pressure injection injury to the upper arm with subsequent soft tissue necrosis and high risk for acute infection. A, B) Clinical presentation at admission (7 days after injury) as referral from a secondary-care facility, where he had been treated with decompression fasciotomies, broad-spectrum empiric antibiotic therapy, and local wound care. The patient was immediately started on daily HBO treatment sessions (<24 hours from admission). C) Surgical debridement (sharp debridement) and wound coverage with cadaveric donor skin (post-injury day 17). D) New surgical debridement and wound coverage with artificial dermal substitute on the palm and autologous skin graft on the forearm (post-injury day 39). The dermal substitute required revision and re-application 34 days after the procedure. E) Final wound coverage with autologous skin graft on the palm (post-injury day 96). F) Ten-month follow-up. Total number of treatment sessions: 19.

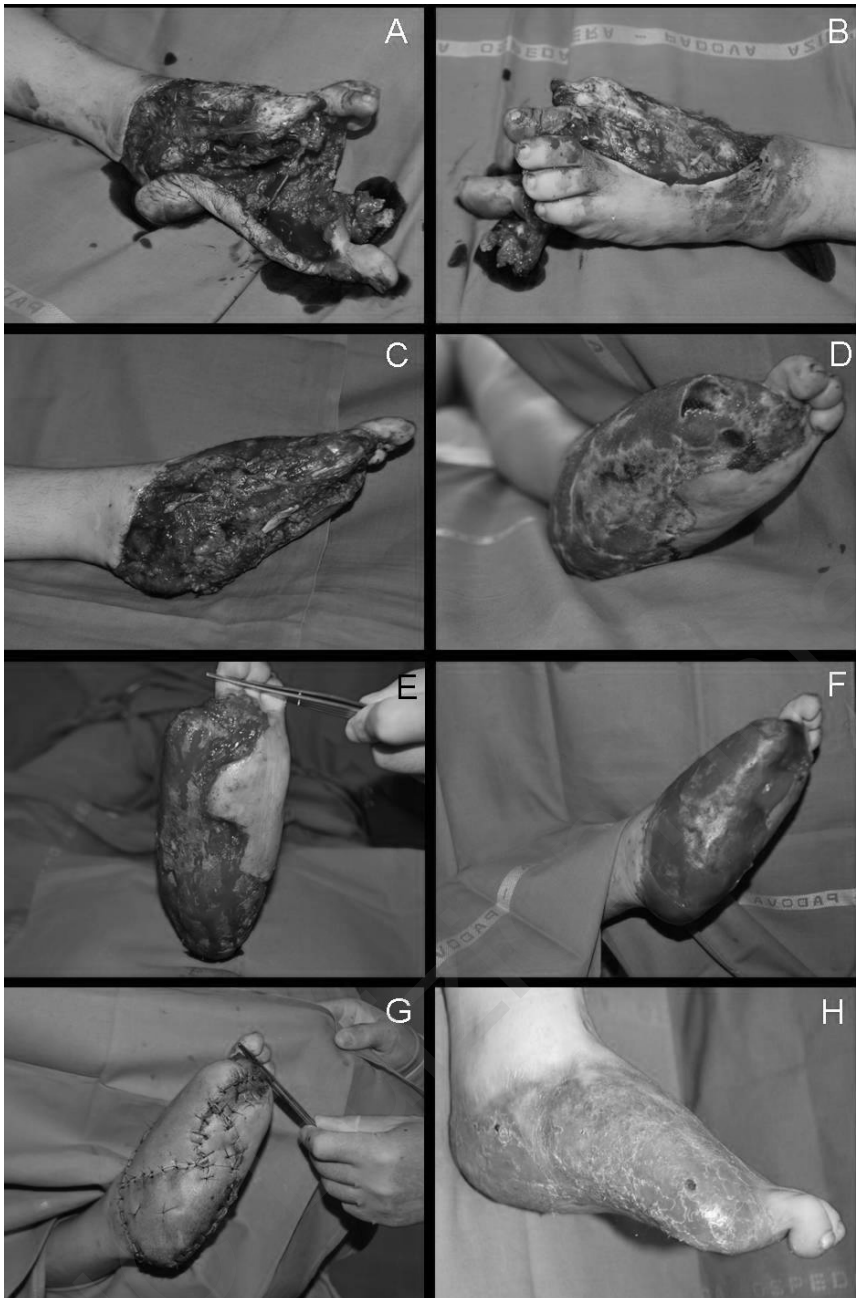


Figure 4 - Age: 16-year old. Gender: F. Indication for HBOT: Crush injury to the lower arm with degloving injury of the foot and high risk for soft tissue necrosis and acute infection. A, B) Clinical presentation at admission. C) After urgent surgical debridement. The patient was immediately started on daily HBO treatment sessions (<48 hours from admission), broad-spectrum empiric antibiotic therapy, and local wound care. C) Surgical debridement (sharp debridement) and wound coverage with cadaveric donor skin (post-injury day 20). D) Clinical status at post-injury day 67. The patient required a new surgical debridement. E) Fresh bleeding tissue after debridement. F) Application of single-layer artificial dermal substitute. G) Coverage of the dermal substitute with autologous skin graft. H) One-year follow-up. Total number of treatment sessions: 15.

er arm, respectively). The second most common reason for referral was acute soft tissue infections (N=38, 20.6%, of which N= 5 necrotizing fasciitis).

The patient population was treated with HBO per protocol according to the most recent Guidelines from Italian Undersea and Hyperbaric Medicine Society (42) (Table 1). Patients underwent a mean of 12.6 ± 8.0 HBO treatment sessions (Figure 5). HBOT was begun a mean of 2.7 ± 3.1 days after

admission and continued until healing/resolution was completed. There were no adverse effects related to HBO treatment in our series.

Discussion

Our experience confirms the usefulness of HBO as auxiliary treatment for many plastic surgical con-

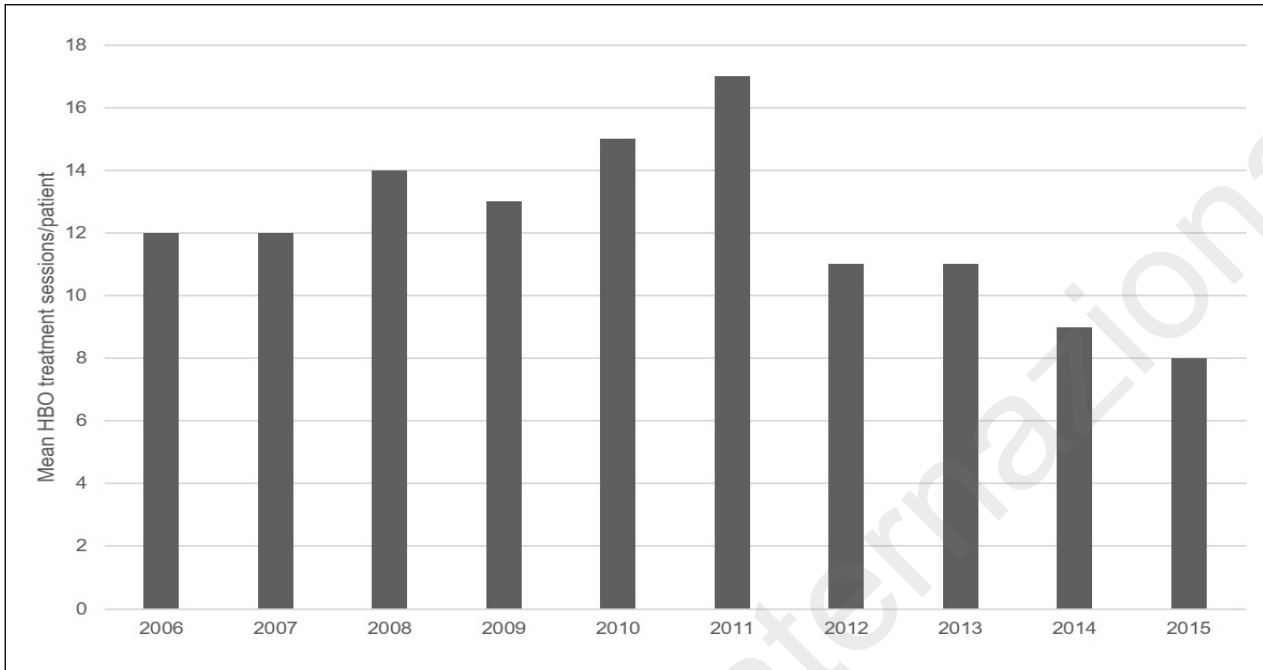


Figure 5 - Mean HBO treatment sessions per patient per year.

ditions and the low incidence of complications. However, the timing and start of the treatment seems to impact on the final outcome. A previously published case series from our group (108) showed that amongst 33 patients affected by complex injuries of the upper arm and who were treated with a mean of 12.3 HBO treatment sessions per patient, the only two secondary amputations were performed in patients who underwent the first HBO session more than 48 hours after the injury. Moreover, a late start of HBO therapy was also associated with a significantly higher infection rate (15.4% *vs* 57.1% in patients receiving the first session within and after the first 48 hours from the injury, respectively). Data on surgical procedures from the case series also highlighted how the number of patients requiring highly complex reconstructions (pedicled and/or free flaps) was lower in the group receiving HBOT earlier (15.4% *vs* 85.6%). Therefore, Authors postulated that an early (<48 hours from admission) start of HBOT could be associated with a reduction in treatment costs by reducing surgical time, length of hospital stay, number of dressing changes and amount of dressing material (including advanced products). Also, the patient could be referred to physical and occupational therapy earlier, limiting lost workdays and reducing social costs. The study

was certainly limited by the small patient population and absence of randomization, but it could provide the cue for further research focusing on the timing and start of HBO therapy.

Although thermal burns have not been mentioned as one of the indications for HBO by the Italian Undersea and Hyperbaric Medicine Society, five patients from our population were treated for this condition. Universal consensus on the issue is still lacking (109), but clinical results show HBOT reduces capillary stasis and limits the increase in size of the coagulation zone, thus assisting in tissue preservation. This mechanism might be of particular value in the case of burns in aesthetically or functionally important zones (face, hands, perineum) or with delicate vascularization (cartilaginous - ears, nose). In a prospective study on burn patients, Hart et al. found that HBOT treated patients required 2.2 ml/kg/% total body surface area (TBSA) of fluids as opposed to 3.4 ml/kg/% TBSA in the control group (110). The hypothesized mechanisms of action involves a vasoconstriction induced by hyperoxia, resulting in reduced plasma exudation while preserving and enhancing tissue oxygenation. The reduction in edema and fluid loss is responsible for a reduction in the amount of fluids required for resuscitation. Further, HBOT may exert beneficial effects by its anti-sludg-

ing effect in the microcirculation and prevention of injury by oxygen free radicals (109). Finally, HBOT in the later stages of management of burns may be useful by its antibacterial action (thus reducing sepsis) and by improved take of skin grafts. UHMS approves the use of HBO for thermal burns in the most recently published guidelines (3).

Dangers, side effects and contraindications

HBOT is generally considered safe and with few side effects. The most common problem is barotraumas of the middle ear. Patients are taught autoinflation techniques and sometimes decongestants are used. If necessary, grommets can be inserted. In emergency treatments in unconscious patients, myringotomy is performed. Prolonged exposure to high-pressure oxygen can cause two potentially serious side-effects: seizures and pulmonary oxygen toxicity. Both of these are very rare, as safe therapeutic limits have been developed over time. Oxygen toxicity seizures are not inherently harmful, and air breathing intervals during HBO therapy are factored into treatment regimens and prophylactic vitamin E is administered to further minimize the risk. Careful history is taken and prophylactic treatment is given in those with specific risk factors; e.g. those with history of seizures, fever, acidosis, or low blood sugar. Claustrophobia may be a problem with some patients, and it is reduced by having an attendant inside the chamber (multiplace) or beside it (mono-place). Mild sedatives are sometimes indicated. Patients are expected to stop smoking for the entire course of HBO therapy. The vasoconstrictive effects of nicotine may interfere with angiogenesis, and raised carbon monoxide levels reduce the full benefit of oxygenation (111, 112).

The only absolute contra-indications are an untreated pneumothorax and certain anticancer drugs, i.e. doxorubicin, bleomycin and cis-platinum, as HBO significantly increases their cytotoxicity. Relative contra-indications include acute viral URTI's, sinusitis, bullous pulmonary disease, history of spontaneous pneumothorax and congenital spherocytosis. Consultation with a physician trained in hyperbaric medicine is important, both for evaluating the indication for HBO therapy and for addressing any possible contraindications (111, 112, 119).

Conclusions

HBOT was started as a treatment modality for management of decompression sickness and, with the passage of time, its scope has gradually increased to include numerous indications. While there has been substantial advancement of the field in recent years, more work is required to establish the place of HBOT in 21st century medicine. Investigation of fundamental mechanisms is still needed, and better patient selection criteria would improve cost-efficacy.

Declarations

Ethics approval and consent to participate

The need for approval was waived.

Consent for publication

Acquired.

Availability of data and material

The datasets used and/or analysed during the current study are available from the corresponding Author on reasonable request.

Funding

Not applicable.

Competing interests

The Authors declare that they have no competing interests.

Authors' contributions

Dr. Bassetto substantially contributed to the conception and design of the article. Dr. Vindigni contributed to the conception and design of the article and critically revised the content. Dr. Tocco-Tussardi acquired and analysed the clinical data, contributed to the conception and design of the article. Dr. Brambullo and Tiengo contributed to the present work by interpreting the data. All Authors read and approved the final manuscript.

Acknowledgments

The Authors would like to thank Dr. Elena Pescarini and Dr. Gabriela Spanikova for skillful assistance in data collection.

References

- Kindwall EP. A history of hyperbaric medicine. In: Kindwall EP, Wheelan H, eds. *Hyperbaric medicine practice*, 2nd ed, revised. Flagstaff, 2004.
- Davis JC, Hunt TK (eds). *Hyperbaric oxygen therapy*. Bethesda, MD: Undersea and Hyperbaric Medicine Society, 1977.
- Undersea and Hyperbaric Medical Society. <http://www.uhms.org/> (Accessed December 2017).
- Camporesi EC. Current diseases approved for treatment, hyperbaric oxygen therapy: A Committee Report. <http://hyperbaric.org.uk/> (Accessed December 2017).
- European committee for hyperbaric medicine. Lille, France: 2016. Proceedings of the 10th European consensus conference on hyperbaric medicine. <http://www.echm.org/> (Accessed December 2017).
- Carmeliet P. Mechanisms of angiogenesis and arteriogenesis. *Nat Med*. 2000;6:389-395.
- Hattori K, Dias S, Heissig B, et al. Vascular endothelial growth factor and angiopoietin-1 stimulate postnatal hematopoiesis by recruitment of vasculogenic and hematopoietic stem cells. *J Exp Med*. 2001;193:1005-1014.
- Tepper OM, Capla JM, Galiano RD, et al. Adult vasculogenesis occurs through in situ recruitment, proliferation, and tubulization of circulating bone marrow-derived cells. *Blood*. 2005;105:1068-1077.
- Goldstein LJ, Gallagher KA, Bauer SM, et al. Endothelial progenitor cell release into circulation is triggered by hyperoxia-induced increases in bone marrow nitric oxide. *Stem Cells*. 2006;24:2309-2318.
- Shyu KG, Hung HF, Wang BW, et al. Hyperbaric oxygen induces placental growth factor expression in bone marrow-derived mesenchymal stem cells. *Life Sci*. 2008;83:65-73.
- Godman CA, Chheda KP, Hightower LE, et al. Hyperbaric oxygen induces a cytoprotective and angiogenic response in human microvascular endothelial cells. *Cell Stress and Chaperones*. 2009;12190-12192.
- Hopf HW, Gibson JJ, Angeles AP, et al. Hyperoxia and angiogenesis. *Wound Repair Regen*. 2005;13:558-564.
- Hildbrand P, Cirulli V, Prins RC, et al. The role of angiopoietins in the development of endothelial cells from cord blood CD34+ progenitors. *Blood*. 2004;104:2010-2019.
- Thom SR, Bhopale VM, Velazquez OC, et al. Stem cell mobilization by hyperbaric oxygen. *Am J Physiol Heart Circ Physiol*. 2006;290:H1378-86.
- Sheikh AY, Gibson JJ, Rollins MD, et al. Effect of hyperoxia on vascular endothelial growth factor levels in a wound model. *Arch Surg*. 2000;135:1293-1297.
- Kang TS, Gorti GK, Quan SY, et al. Effect of hyperbaric oxygen on the growth factor profile of fibroblasts. *Arch Facial Plast Surg*. 2004;6:31-35.
- Lin S, Shyu KG, Lee CC, et al. Hyperbaric oxygen selectively induces angiopoietin-2 in human umbilical vein endothelial cells. *Biochem Biophys Res Commun*. 2002;296:710-715.
- Asano T, Kaneko E, Shinozaki S, et al. Hyperbaric oxygen induces basic fibroblast growth factor and hepatocyte growth factor expression and enhances blood perfusion and muscle regeneration in mouse ischemic hind limbs. *Circ J*. 2007;71:405-411.
- Bonomo SR, Davidson JD, Yu Y, et al. Hyperbaric oxygen as a signal transducer: upregulation of platelet derived growth factor-beta receptor in the presence of HBO2 and PDGF. *Undersea Hyperb Med*. 1998;25:211-216.
- Zamboni WA, Roth AC, Russell RC, et al. Morphologic analysis of the microcirculation during reperfusion of ischemic skeletal muscle and the effect of hyperbaric oxygen. *Plast Reconstr Surg*. 1993;91:1110-1123.
- Thom SR. Leukocytes in carbon monoxide-mediated brain oxidative injury. *Toxicol Appl Pharmacol*. 1993;123:234-247.
- Labrousche S, Javorschi S, Leroy D, et al. Influence of hyperbaric oxygen on leukocyte functions and haemostasis in normal volunteer divers. *Thromb Res*. 1999;96:309-315.
- Kalns J, Lane J, Delgado A, et al. Hyperbaric oxygen exposure temporarily reduces Mac-1 mediated functions of human neutrophils. *Immunol Lett*. 2002;83:125-131.
- Thom SR. Functional inhibition of leukocyte B2 integrins by hyperbaric oxygen in carbon monoxide-mediated brain injury in rats. *Toxicol Appl Pharmacol*. 1993;123:248-256.
- Wong HP, Zamboni WA, Stephenson LL. Effect of hyperbaric oxygen on skeletal muscle necrosis following primary and secondary ischemia in a rat model. *Surgical Forum*. 1996;705-707.
- Ueno S, Tanabe G, Kihara K, et al. Early post-operative hyperbaric oxygen therapy modifies neutrophil activation. *Hepato Gastroenterology*. 1999;46:1798-1799.
- Atochin D, Fisher D, Demchenko I, et al. Neutrophil sequestration and the effect of hyperbaric oxygen in a rat model of temporary middle cerebral artery occlusion. *Undersea and Hyperbaric Med*. 2000;27:185-190.
- Yang ZJ, Bosco G, Montante A, et al. Hyperbaric O2 reduces intestinal ischemia-reperfusion induced TNF-alpha production and lung neutrophil sequestration. *Eur J Appl Physiol*. 2001;85:96-103.
- Tahepold P, Valen G, Starkopf J, et al. Pretreating rats with hyperoxia attenuates ischemia reperfusion injury of the heart. *Life Sci*. 2001;68:1629-1640.
- Thom S, Mendiguren I, Fisher D. Smoke inhalation-induced alveolar lung injury is inhibited by hyperbaric oxygen. *Undersea and Hyperbaric Med*. 2002;28:175-180.
- Kihara K, Ueno S, Sakoda M, et al. Effects of hyperbaric oxygen exposure on experimental hepatic ischemia reperfusion injury: relationship between its timing and neutrophil sequestration. *Liver Transpl*. 2005;11:1574-1580.
- Bhutani S, Vishwanath G. Hyperbaric oxygen and wound healing. *Ind J Plast Surg*. 2012;45:316-324.
- Ferreira APP, Vide SS, Fernandes TDF, et al. Hyperbaric oxygen therapy as an adjuvant to source control in necrotizing soft tissue infections. *Undersea Hyperb Med*. 2017;44:535-542.
- Cianci P. Advances in the treatment of the diabetic foot: Is there a role for adjunctive hyperbaric oxygen therapy? *Wound Repair Regen*. 2004;12:2-10.
- Yang Z, Hu J, Qu Y, et al. Interventions for treating gas gangrene. *Cochrane Database Syst Rev*. 2015;(12):CD010577.
- Bornside GH. Enhancement of antibiotic activity against *Staphylococcus aureus* by exposure to hyperbaric oxygen. *Appl Microbiol*. 1967;15:1020-1024.
- Marzella L, Vezzani G. Effect of hyperbaric oxygen on activity

- of antibacterial agents. In: Oriani G, Marroni A, Wattel F (eds). *Handbook on Hyperbaric Medicine*. Milan, 1996.
38. Marx RE, Ehler WJ, Tayapongsak P, et al. Relationship of oxygen dose to angiogenesis induction in irradiated tissue. *Am J Surg*. 1990;160:519-524.
 39. Gallagher KA, Liu ZJ, Xiao M. Diabetic impairments in NO-mediated endothelial progenitor cell mobilization and homing are reversed by hyperoxia and SDF-1 alpha. *J Clin Invest*. 2007;117:1249-1259.
 40. Zhang Q, Chang Q, Cox RA, et al. Hyperbaric oxygen attenuates apoptosis and decreases inflammation in an ischemic wound model. *J Invest Dermatol*. 2008;128:2102-2112.
 41. Dinar S, Agir H, Sen C, et al. Effects of hyperbaric oxygen therapy on fibrovascular ingrowth in porous polyethylene blocks implanted under burn scar tissue: an experimental study. *Burns*. 2008;34:467-473.
 42. Società Italiana di Medicina Subacquea e Iperbarica. Italian Undersea and Hyperbaric Medicine Society. <http://www.simsi.it/> (Accessed December 2017).
 43. Malerba F, Oriani G, Farnetti A. HBO in orthopaedic disorders. In: Oriani G, Marroni A, Wattel F (eds). *Handbook on Hyperbaric Medicine*. Milan, 1996.
 44. Sakurai J, Nagahama M, Oda M. Clostridium perfringens Alpha-Toxin: Characterization and mode of action. *J Biochem*. 2004;136:569-574.
 45. Bakker DJ. Clostridial Myonecrosis. In: Davis JC, Hunt TK (eds). *Problem Wounds: The Role of Oxygen*. New York, 1988.
 46. Hart GB, Strauss MB. Gas gangrene – clostridial myonecrosis: a review. *J Hyper Med*. 1990;5:125-44.
 47. Cohn GH. Hyperbaric oxygen therapy; promoting healing in difficult cases. *Postgrad Med*. 1986;79:89-92.
 48. Lancerotto L, Tocco I, Salmaso R, et al. Necrotizing fasciitis: classification, diagnosis, and management. *J Trauma Acute Care Surg*. 2012;72:560-566.
 49. McHenry CR, Piotrowski JJ, Petrinic D, et al. Determinants of mortality for necrotizing soft-tissue infections. *Ann Surg*. 1995;221:558-563.
 50. Tocco I, Lancerotto L, Pontini A, et al. “Synchronous” multifocal necrotizing fasciitis. *J Emerg Med*. 2013;45:e187-191.
 51. Arif N, Yousef S, Vinnard C. Deaths from Necrotizing Fasciitis in the United States, 2003-2013. *Epidemiol Infect*. 2016;144:1338-1344.
 52. Riseman JA, Zamboni WA, Curtis A, et al. Hyperbaric oxygen therapy for necrotizing fasciitis reduces mortality and the need for debridement. *Surgery*. 1990;108:847.
 53. Escobar SJ, Slade JB Jr, Hunt TK, et al. Adjuvant hyperbaric oxygen therapy (HBO2) for treatment of necrotizing fasciitis reduces mortality and amputation rate. *Undersea Hyperb Med*. 2005;32:437.
 54. Shaw JJ, Psoinos C, Emhoff TA, et al. Not just full of hot air: hyperbaric oxygen therapy increases survival in cases of necrotizing soft tissue infections. *Surg Infect (Larchmt)*. 2014;15:328-335.
 55. Brown DR, Davis NL, Lepawsky M, et al. A multicenter review of the treatment of major truncal necrotizing infections with and without hyperbaric oxygen therapy. *Am J Surg*. 1994;167:485.
 56. Elliott DC, Kufera JA, Myers RAM. Necrotizing soft tissue infections: Risk factors for mortality and strategies for management. *Ann Surg*. 1996;224:672.
 57. George ME, Rueth NM, Skarda DE, et al. Hyperbaric oxygen does not improve outcome in patients necrotizing soft tissue infection. *Surg Infect*. 2009;10:21.
 58. Massey PR, Sakran JV, Mills AM, et al. Hyperbaric oxygen therapy in necrotizing soft tissue infections. *J Surg Res*. 2012;146-151.
 59. Myers RAM. Hyperbaric oxygen therapy for trauma: crush injury, compartment syndrome, and other acute traumatic peripheral ischemias. *Int Anesth Clin*. 2000;38:139-151.
 60. Strauss MB. The effect of hyperbaric oxygen in crush injuries and skeletal muscle-compartment syndromes. *Undersea Hyperb Med*. 2012;39:847-855.
 61. Dougherty JE. The role of hyperbaric oxygen therapy in the management of crush injury and traumatic ischemia: an evidence-based approach. *Am Surg*. 2005;71:144-151.
 62. Bassett CAL. Current concepts of bone formation. *J Bone Joint Sur*. 1962;44:1217-1244.
 63. Trueta J. The role of vessels in osteogenesis. *J Bone Joint Surg Br*. 1963;45:402.
 64. Hulth A, Johnell O, Lindberg L, et al. Demonstration of blood-vessel like structures in cartilaginous callus by antilaminin and antiheparin sulfate proteoglycan antibodies. *Clin Orthop Relat Res*. 1990;289-293.
 65. Jan AM, Sandor GK, Iera D, et al. Hyperbaric oxygen results in an increase in rabbit calvarial critical sized defects. *Oral Surg Oral Med Oral Pathol Oral Radiol Endod*. 2006;101:144-149.
 66. Jan A, Sandor GK, Brkovic BB, et al. Effect of hyperbaric oxygen on grafted and nongrafted calvarial critical-sized defects. *Oral Surg Oral Med Oral Pathol Oral Radiol Endod*. 2009;107:157-163.
 67. Muhonen A, Haaparanta M, Gronroos T, et al. Osteoblastic activity and neoangiogenesis in distracted bone of irradiated rabbit mandible with or without hyperbaric oxygen treatment. *Int J Oral Maxillofac Surg*. 2004;33:173-178.
 68. Baynosa RC, Zamboni WA. The effect of hyperbaric oxygen on compromised grafts and flaps. *Undersea Hyperb Med*. 2012;39:857-865.
 69. Sheik N, Porten BR, Isaacson E, et al. Hyperbaric oxygen treatment outcome for different indications from a single center. *Ann Vasc Surg*. 2015;29:206-214.
 70. Zhou YY, Liu W, Yang YL, Lu GD. Use of hyperbaric oxygen on flaps and grafts in China: analysis of studies in the past 20 years. *Undersea Hyperb Med*. 2014;41:209-2016.
 71. Perrins DJD, Cantab MB. Influence of hyperbaric oxygen on the survival of split skin grafts. *Lancet*. 1967;II:868-871.
 72. Bowersox J, Strauss M, Hart G. Clinical experience with hyperbaric oxygen therapy in the salvage of ischemic skin flaps and grafts. *J Hyperbaric Med*. 1986;1:141-149.
 73. Kindwall E, Gottlieb L, Larson D. Hyperbaric oxygen therapy in plastic surgery: a review article. *Plast Reconstr Surg*. 1991;88:898-908.
 74. Friedman HIF, Fitzmaurice M, Lefavre JF, et al. An evidence-based appraisal of the use of hyperbaric oxygen on flaps and grafts. *Plast Reconstr Surg*. 2006;117 Suppl:175S-190S.
 75. Francis A, Baynosa RC. Hyperbaric oxygen therapy for the compromised graft or flap. *Adv Wound Care (New Rochelle)*. 2017;6:23-32.
 76. Mader JT, Adams KR, Wallace WR, Calhoun JH. Hyperbaric

- oxygen as adjunctive therapy for osteomyelitis. *Infect Dis Clin north Am.* 1990;433-440.
77. Goldman RJ. Hyperbaric oxygen therapy for wound healing and limb salvage: a systematic review. *Wound Care and Rehab Med.* 2009;1:471-489.
 78. Yu WK, Chen YW, Shie HG, et al. Hyperbaric oxygen therapy as an adjunctive treatment for sternal infection and osteomyelitis after sternotomy and cardiothoracic surgery. *J Cardiothorac Surg.* 2011;6:141.
 79. Davis JC, Heckman JD, DeLee JC, et al. Chronic non-hematogenous osteomyelitis treated with adjuvant hyperbaric oxygen. *J Bone Jt Surg Am.* 1986;68:1210-1217.
 80. Esterhai JL Jr, Pisarello J, Brighton CT, et al. Adjunctive hyperbaric oxygen therapy in the treatment of chronic refractory osteomyelitis. *J Trauma Inj Infect Crit Care.* 1987;27:763-768.
 81. Morrey BF, Dunn JM, Heimbach RD, et al. Hyperbaric oxygen and chronic osteomyelitis. *Clin Orthop Related Res.* 1979;144:121-127.
 82. Chen CY, Lee SS, Chan YS, et al. Chronic refractory tibia osteomyelitis treated with adjuvant hyperbaric oxygen: a preliminary report. *Changeng Yi Xue Za Zhi.* 1998;21:165-171.
 83. Chen CE, Ko JY, Fu TH, et al. Results of chronic osteomyelitis of the femur treated with hyperbaric oxygen: a preliminary report. *Chang Gung Med J.* 2004;27:91-97.
 84. Chen CE, Shih ST, Fu TH, et al. Hyperbaric oxygen therapy in the treatment of chronic refractory osteomyelitis: a preliminary report. *Chang Gung Med J.* 2003;26:114-121.
 85. Eggleton P, Bishop AJ, Smerdon GR. Safety and efficacy of hyperbaric oxygen therapy in chronic wound management: current evidences. *Chronic Wound Care Management and Research.* 2015;2:81-93.
 86. Niinikoski J. Current concepts of the role of oxygen in wound healing. *Ann Chir Gynaecol.* 2001;90 Suppl 215:9-11.
 87. Hammarlund C, Sundberg T. Hyperbaric oxygen reduced size of chronic leg ulcers: a randomized double-blind study. *Plast Reconstr Surg.* 1994;93:829-833.
 88. Zamboni WA, Browder LK, Martinez J. Hyperbaric oxygen and wound healing. *Clin Plast Surg.* 2003;30:67-75.
 89. Wang C, Schwaitzberg S, Berliner E, et al. Hyperbaric oxygen for treating wounds. *Arch Surg.* 2003;138:272-279; discussion 280.
 90. Thackham JA, McElwain DLS, Long RJ. The use of hyperbaric oxygen therapy to treat chronic wounds: a review. *Wound Repair Regen.* 2008;16:321-330.
 91. Hunter S, Langemo DK, Anderson J, et al. Hyperbaric oxygen therapy for chronic wounds. *Adv Skin & Wound Care.* 2010;23:116-119.
 92. Peters EJG, Lipsky BA, Berendt AR, et al. A systematic review of the effectiveness of interventions in the management of infection in the diabetic foot. *Diabetes Metab Res Rev.* 2012;28:142-162.
 93. Bishop AJ, Mudge E. Diabetic foot ulcers treated with hyperbaric oxygen therapy: a review of the literature. *Int Wound J.* 2014;11:28-34.
 94. Opananon S, Pongsapich W, Taweepraditpol S, et al. Clinical effectiveness of hyperbaric oxygen therapy in complex wounds. *J Am Coll Clin Wound Spec.* 2015;6:9-13.
 95. Elraiyah T, Tsapas A, Prutsky G, et al. A systematic review and meta-analysis of adjunctive therapies in diabetic foot ulcers. *J Vasc Surg.* 2016;63:46S-58S.e1-2.
 96. Fife CF, Buyukcakil C, Otto GH. The predictive value of transcutaneous oxygen tension measurement in diabetic lower extremity ulcers treated with hyperbaric oxygen therapy: a retrospective analysis of 1144 patients. *Wound Rep Reg.* 2002;10:198-207.
 97. Wattel FE, Mathieu DM, Fossati P, et al. Hyperbaric oxygen in the treatment of diabetic foot lesions: search for healing predictive factors. *J Hyperbaric Med.* 1991;6:263-268.
 98. Smith BM, Desvigne LD, Slade JB, et al. Transcutaneous oxygen measurements predict healing of leg wounds with hyperbaric therapy. *Wound Rep Reg.* 1996;4:224-229.
 99. Niinikoski JHA. Clinical hyperbaric oxygen therapy, wound perfusion, and transcutaneous oximetry. *World J Surg.* 2004;28:307-311.
 100. Feldmeier JJ, Hampson NB. A systematic review of the literature reporting the application of hyperbaric oxygen prevention and treatment of delayed radiation injuries: an evidence based approach. *Undersea Hyperb Med.* 2002;29:4-30.
 101. Pasquier D, Schmutz J, Lartigau E. Radio-induced lesion in normal tissues. In: Mathieu D, ed. *Handbook on Hyperbaric Medicine.* Dordrecht (NL): Springer, 2006:363-399.
 102. Pasquier D, Hoelscher T, Schmutz J, et al. Hyperbaric oxygen therapy in the treatment of radio-induced lesions in normal tissues: a literature review. *Radiother Oncol.* 2004;72:1-13.
 103. Shaw RJ, Dhanda J. Hyperbaric oxygen in the management of late radiation injury of the head and neck. Part I: treatment. *Br J Oral Maxillofac Surg.* 2011;49:2-8.
 104. Hampson NB, Holm JR, Wreford-Brown CE, Feldmeier J. Prospective assessment of outcomes in 411 patients treated with hyperbaric oxygen for chronic radiation tissue injury. *Cancer.* 2012;118:3860-3868.
 105. Tahir ARM, Westhuyzen J, Dass J, et al. Hyperbaric oxygen therapy for chronic radiation-induced tissue injuries: Australasia's largest study. *Asia Pac J Clin Oncol.* 2015;11:68-77.
 106. Gesell L, ed. *Hyperbaric Oxygen 2008: Indications and Results.* The Hyperbaric Oxygen Therapy Committee Report. Durham, NC: Undersea and Hyperbaric Medical Society; 2008.
 107. Feldmeier JJ. Hyperbaric oxygen for radiation injury: is it indicated? *Curr Oncol.* 2011;18:211-212.
 108. Bassetto F, Monticelli A, Dalla Venezia E, et al. Hyperbaric oxygen therapy in complex injuries of the upper extremity. *Chirurgia della Mano.* 2016;53:4-13.
 109. Germonpre P. Burns. In: Mathieu D (ed). *Handbook on Hyperbaric Medicine.* Dordrecht, 2006.
 110. Hart GB, O'Reilly RR, Broussard ND. Treatment of burns with hyperbaric oxygen. *Surg Gynecol Obstet.* 1974;139:693-696.
 111. Latham E, Hare MA, Neumeister M, Schraga BD, Windle ML, Mosenifar Z (eds). *Hyperbaric oxygen therapy.* <http://emedicine.medscape.com/article/1464149-overview/> (Accessed December 2017).
 112. Michael N, Cram AE, Talavera F, Newsome RE, Slenkovich NG, Torre JT (eds). *Hyperbaric oxygen therapy.* <http://emedicine.com/plastic/topic526.html/> (Accessed December 2017).
 113. Levett D, Bennett MH, Millar I. Adjunctive hyperbaric oxygen for necrotizing fasciitis (review). *The Cochrane collaboration, review reprint:* 2015;1-4.
 114. Weaver LK. Hyperbaric oxygen in the critically ill. *Crit Care Med.* 2011;39:1784-1791.

115. Yamada N, Toyoda I, Doi T, et al. Hyperbaric oxygenation therapy for crush injuries reduces the risk of complications: research report. *Undersea Hyperbaric Med.* 2014;41:283-289.
116. Cierny G 3rd, Mader JT, Pennick JJ. A clinical staging for adult osteomyelitis. *Clin Orthop Rel Res.* 2003;7-24.
117. Johansen K, Daines M, Howey T, et al. Objective criteria accurately predict amputation following lower extremity trauma. *J Trauma.* 1990;30:568-72; discussion 572-3.
118. Gustilo RB, Mendoza RM, Williams DN. Problems in management of type III (severe) open fractures: a new classification of type III open fractures. *J Trauma.* 1984;24:742-746.
119. Heyboer M 3rd, Sharma D, Santiago W, McCulloch N. Hyperbaric Oxygen Therapy: Side Effects Defined and Quantified. *Adv Wound Care (New Rochelle).* 2017;6:210-224.
-