

Modified transverse coloplasty pouch: new reconstruction techniques after total mesorectal excision. Our experience

G. GRIMALDI, C. EBERSPACHER, A.M. ROMANI, D. MERLETTI, A. MATURO,
F.M. DI MATTEO, S. PONTONE, D. PIRONI

SUMMARY: Modified transverse coloplasty pouch: new reconstruction techniques after total mesorectal excision, our experience.

G. GRIMALDI, C. EBERSPACHER, A.M. ROMANI, D. MERLETTI, A. MATURO, F.M. DI MATTEO, S. PONTONE, D. PIRONI

Aim. The incidence of rectal cancer continues to rise. The functional results after complete Total Mesorectal Excision (TME) depend on the segment of colon used for reconstruction of colonic continuity and the form, the volume and the functional proprieties of the "neorectum". The aim of our study is evaluate the efficacy of our Modified Transverse Coloplasty Pouch (MTCP) after the treatment of low rectal cancer in terms of functional outcomes and quality of life.

Patients and methods. The study included 136 patients, un-

derwent TME from January 2007 to December 2016 with diagnosis of extraperitoneal carcinoma of the rectum. The average distance of the tumor from the dentate line was 5.6 cm.

Our follow-up protocol included functional outcome evaluation at 7th post-operative day (POD), 2nd month, and 6th month after the surgery.

Results. All patients (M/F 84/52) underwent anterior rectal resection (TME) with MTCP. Frequency of bowel movements per 24 hours in the studied patients compared at 7th POD, 2 months, and 6 months. Since the first post-operative weeks there is an encouraging reduction of the frequency of bowel movements.

Conclusion. Modified Transverse Coloplasty Pouch (MTCP) had better functional results and quality of life compared to patients with a Colonic J Pouch (CJP) and traditional Transverse Coloplasty Pouch (TCP).

KEY WORDS: Modified Transverse Coloplasty Pouch (MTCP) - Coloplasty - Colonic J Pouch.

Introduction

The incidence of rectal cancer continues to rise, especially in Western countries where it is the second most common cause of death from cancer in both men and women.

In spite of primary prevention programs rectal cancer is rarely diagnosed in an early stage.

Currently surgical resection in a multidisciplinary setting is still the main method of treating this disease and the only one that offers patients a chance of a cure. In cases of locoregional spread or systemic disease neoadjuvant and/or adjuvant therapy (radiochemotherapy) can consolidate and improve the

results of oncologically correct surgery. The important modifications and innovations made in rectal cancer surgery over the past thirty years have made possible greater oncological radicality and more frequent sparing of the anal sphincter, even in patients with distal rectal tumors.

The preservation of continence and the definition of the adequacy of rectal and TME represent two of the formidable challenges in rectal surgery during the last 30 years. The functional results after complete rectal excision depend on the segment of colon used for reconstruction of colonic continuity and the form, the volume and the functional proprieties of the "neorectum".

Performing a straight coloanal anastomosis for restoring the bowel continuity may be complicated by "anterior resection syndrome (ARS)" characterized by increase in defecatory frequency, urgency, and incontinence (1-3). This syndrome results from loss of rectal reservoir.

Z'graggen K developed a very small pouch, the Transverse Coloplasty Pouch (TCP), initially tested for its safety and early outcome in the animal model where it was compared with the standard operations like straight coloanal anastomosis and Colonic J Pouch (CJP) (4-10).

With the establishment of safety and excellent early results in animal model, the technique of TCP anastomosis was adapted in humans. It is claimed that this small volume reservoir, similar to pyloroplasty or strictureplasty, gives an improvement in early functional outcome and a decrease in late evacuation problems. The TCP is technically simpler than J Pouch and can be performed in presence of short or thick mesocolon or narrow male pelvis. Besides, TCP is more physiological and is in conformity with peristalsis at the time of defecation (11, 12).

In accord to the original Z'graggen's technique, we performed a smaller pouch since we believe that the functional principle of the coloplasty (Modified Transverse Coloplasty Pouch, MTCP) is not only the creation of a neorectum but, more importantly, the interruption of the peristaltic waves when the muscle layers are cut and of the intrinsic nervous plexus due to the colotomy. Our study indicates that the smaller capacity of this pouch is sufficient to allow normal defecation. Compared to both a traditional TCP, the functional results were better in our novel colon pouch.

Patients and methods

From January 2007 to December 2016, in the Department of Surgical Sciences at the "Umberto I" Polyclinic of the "Sapienza" University in Rome, Italy, 136 patients with extraperitoneal rectal cancer were operated on by the same surgeon. There were 84 men and 52 women, with an average age of 62 years (range 32-89 years). The average distance of the tumor from the dentate line was 5.6 cm (range 2-12 cm).

Our clinical staging protocol included a digital rectal examination, pancolonoscopy with biopsy, full-body computed tomography (CT) scan, magnetic resonance imaging (MRI) of the pelvis, abdominal ultrasound, chest X-ray, levels of tumor markers (CEA, CA 19-9) and, for tumors of the middle-lower third of the rectum, transrectal ultrasound. Preoperatively evacuation and sphincter function were evaluated using anorectal manometry and a standardized questionnaire containing questions about frequency of evacuation, defecation urgency (inability to postpone evacuation for more

than 15 minutes), ability to distinguish between gas and feces, and continence/incontinence of solid/liquid stool and gas.

Patients received antibiotic prophylaxis the day before surgery (Metronidazole 500 mg, 1 every 8 hours) and mechanical bowel preparation (Macro-gel, four 70 g sachets).

TME was performed in all cases, using Heald's technique, the autonomic innervation of the pelvis was spared and since all procedures were performed by the same surgeon uniformity of surgical technique was guaranteed.

All patients underwent surgery, coloanal anastomosis was performed and a colonic reservoir was fashioned proximally to the anastomosis, using MTCP.

Our follow-up protocol included functional outcome evaluation was done at 7th day, 2nd month, and 6th month focusing on the following points: frequency of bowel movements per 24 hours; nocturnal bowel movements; ability to defer defecation for more than 30 minutes; composite incontinence score; ability to evacuate bowel within 15 minutes; sensation of incomplete evacuation.

Surgical technique MTCP

All patients underwent a standard low anterior resection with TME.

Descending colon after proper mobilization was used to make anastomosis in all patients. Articulating linear stapler was applied to anorectal junction to remove rectum and specimen.

After inserting the anvil of the circular stapler into the colon stump and fixing it in place with a purse-string suture (1-0 prolene), a longitudinal incision in the serosa was made with an electric scalpel starting at 3 cm above the edge of the anvil, between two taenia on the antimesenteric aspect of the colon and continuing proximally for 5 cm (Figure 1). Then 2 absorbable stitches were placed on each side of the central part of the incision and the ends of each of the stitches were held by mosquito forceps. Upward and lateral traction was applied and the colotomy was completed along the incision in the serosa (Figure 2). Four Allis forceps were used to approximate the edges of the incision transversely. The colotomy was sutured transversely using a 60 mm linear stapler. In this way a small colonic reservoir was fashioned immediately distal to the anastomosis (Figures 3, 4).

The head of the circular stapler was introduced into anal canal and engaged with anvil. The stapler was fired to make the final anastomosis.

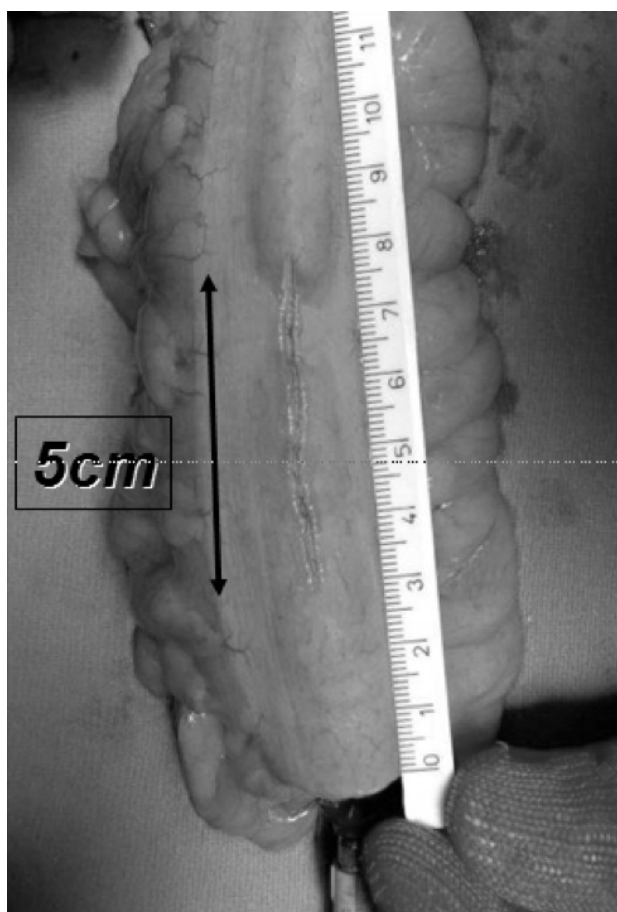


Figure 1 - Longitudinal incision starting at 3 cm above the edge of the anvil between two taenia on the antimesenteric side continuing proximally for 5 cm.

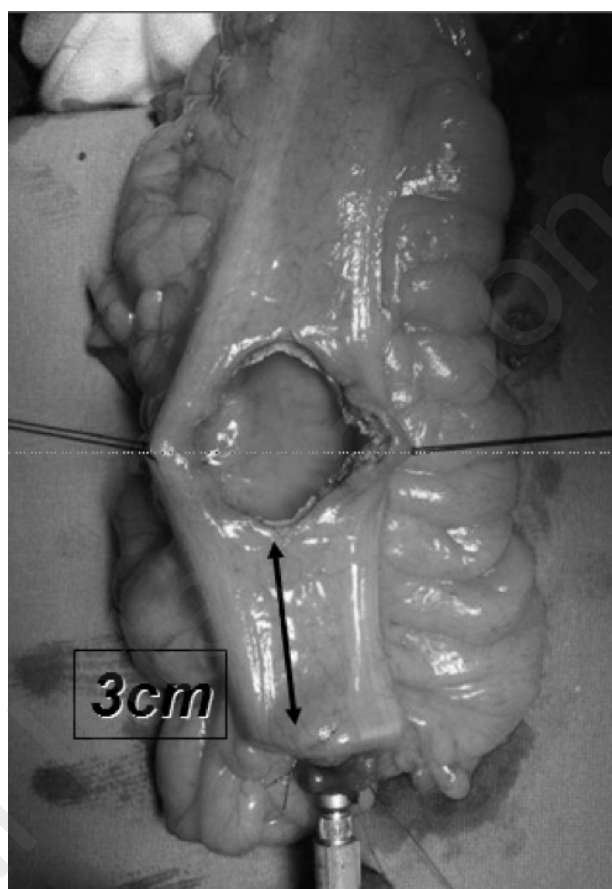


Figure 2 - Two absorbable stitches are placed on each side of the central part of incision and subsequently colotomy is completed.

Results

The data of patients and tumors are shown in Table 1.

All patients (136 - M/F 84/52) underwent anterior rectal resection (TME) with MTCP.

Frequency of bowel movements per 24 hours in the studied patients compared at 7th POD, 2 months, and 6 months is shown in Table 2. Since the first post-operative weeks there is an encouraging reduction of the frequency of bowel movements.

The nocturnal bowel movements are shown in Table 3.

The ability to defer defecation for more than 30 minutes showed significantly results at 7th POD, 2 months, and 6 months as detailed in Table 4.

Table 5 shows results of the composite incontinence score until 6th month.

Discussion and conclusions

As a result of the introduction of TME and the reduction of distal surgical margin width larger numbers of restorative procedures are performed that involve progressively more extensive rectal resection and even complete exeresis of the rectum in cases of intersphincteric resections, and, therefore, anastomoses that are often located in the last 2 cm of the rectum/anal canal (16-25). At this level, in most patients direct recanalization is associated with various continence problems (the anterior resection syndrome) such as more frequent defecation, defecation urgency, and episodes of minor incontinence which have a negative influence on quality of life although they usually resolve within one year after the procedure. This syndrome resulting from loss of rectal reservoir may affect up to 90% of patients with straight coloanal anastomosis and may worsen the quality of life in about 39% of patients (8-10).

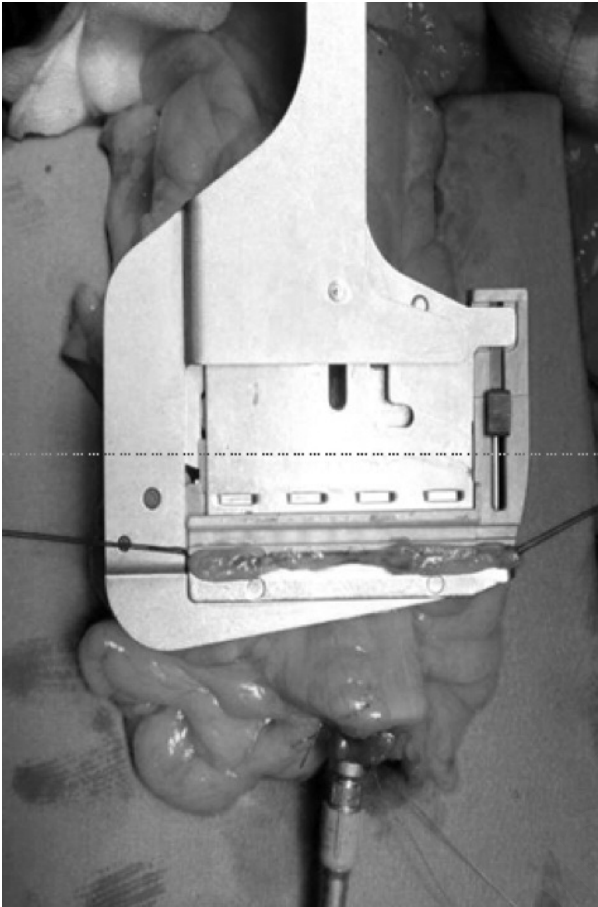


Figure 3 - Colotomy is sutured using a 60 mm linear stapler.

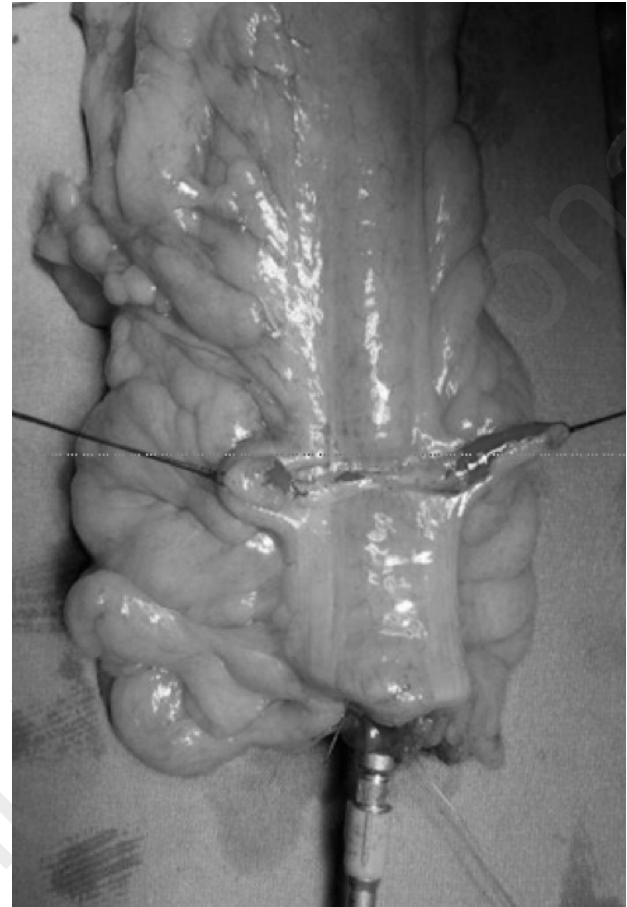


Figure 4 - Full colotomy suture: a small colonic reservoir will be found immediately distal to the anastomosis.

TABLE 1 - CHARACTERISTICS OF PATIENTS AND NEOPLASIAE.

N of patients	136
Sex (M/F)	84/52
Average age, years (range)	62 (32-88)
Distance of tumor from dentate line, cm (range)	5,6 (2-12)
Dukes stage of tumor, number of pts. (%):	
A	43 (31,6%)
B	30 (22,1%)
C	63 (46,3%)

Construction of a “neorectal” reservoir has been shown to be effective in reducing the frequency and duration of these incontinence problems. Two types of pouch have been developed; one formed from a loop of the colon bent in a J shape (J-pouch) which is connected to the anal canal in a latero-terminal

TABLE 2 - FREQUENCY OF BOWEL MOVEMENTS PER 24 HOURS.

	N	%
7 th day		
≤ 2	120	88,2
> 2	16	11,8
2 nd month		
≤ 2	85	62,5
> 2	51	37,5
6 th month		
≤ 2	112	82,3
> 2	24	17,7

anastomosis, and another made in a transverse coloplasty (TCP) just proximal to a termino-terminal anastomosis (11, 12). However, 10% to 30% of pa-

TABLE 3 - NOCTURNAL BOWEL MOVEMENTS.

	N	%
7 th day	74	54,4
2 nd month	48	35,3
6 th month	0	0

TABLE 4 - ABILITY TO DEFER DEFECTION FOR > 30 MINUTES.

	N	%
7 th day		
Never	70	51,4
Sometimes	59	43,4
Often	7	5,2
Always	0	0
2 nd month		
Never	0	0
Sometimes	45	33
Often	68	50
Always	23	17
6 th month		
Never	0	0
Sometimes	0	0
Often	50	36,7
Always	80	63,3

TABLE 5 - COMPOSITE INCONTINENCE SCORE.

	N	%
7 th day		
Nil	7	5,1
Mild	101	74,3
Moderate	28	20,6
Severe	0	0
2 nd month		
Nil	109	80
Mild	23	17
Moderate	4	3
Severe	0	0
6 th month		
Nil	136	100
Mild	0	0
Moderate	0	0
Severe	0	0

tients CJP may experience some late evacuation problems with incomplete defaecation that needs the daily use of laxatives, enemas and suppositories (13). But even then late evacuation problems remained in 10% of patients. The TCP had been proposed to overcome these limitations. Z'graggen et al. in their study confirmed the safety of TCP for reconstruction after sphincter saving rectal resection (11, 12). Their study showed a favorable early functional outcome following TCP with avoidance of late evacuation problems seen with colon pouch.

The method of pouch construction that we prefer, and which we have used since 2004, involves fashioning a 5 cm stapled coloplasty (MTCP) immediately proximal to the cut edge of the descending colon, and a distal termino-terminal transutural colorectal anastomosis, or a handsewn coloanal anastomosis in cases in which, in order to obtain an adequate distal margin, the anal canal is resected at the dentate line (26-28).

In contrast to the original technique, we perform a stapled coloplasty only 5 cm long (not 8-10 cm), and thus create a smaller pouch since we believe that the functional principle of the coloplasty is not only the creation of a "new" ampulla but, more importantly, the interruption of the peristaltic waves due to cutting of muscle layers and of the intrinsic nervous plexus due to the colotomy (6, 7, 11, 12).

According to the literature relevant to the TCP, in particular in the study of Huttner et al., the MTCP reduced the number of bowel movements per 24h ≤ 2 more than 60% of the patients since first postoperative days until 82,3% to 6 months (29).

In our study on the MTCP, the results to ability to evacuate bowel within 15 minutes is similar to data reported by Parray et al. (30). MTCP an excellent choice to avoid late evacuation problems seen with CJP.

A relevant data in our study is the composite incontinence scoring (CIS). At 2 months, 80% of patients had nil CIS whereas at 6 months, all patients had nil score.

In conclusion, MTCP, can be used for obese patients with a short and thick mesocolon or a narrow and deep pelvis, is not associated with longer operative times or additional complications, and provides good functional results with resolution of the symptoms of anterior resection syndrome as early as 2 months postoperatively, thus improving patients' quality of life. Summarizing our results, patients with Modified Transverse Coloplasty Pouch (MTCP) compared to patients with a Colonic J

Pouch (CJP) and traditional Transverse Coloplasty Pouch (TCP) had better functional results and quality of life.

References

1. Law WL, Chu Kw. Anterior resection for rectal cancer with mesorectal excision: a prospective evaluation of 622 patients. *Ann Surg.* 2004;240:260-268.
2. Pironi D, Vendettuoli M, Pontone S, Panarese A, Arcieri S, Filippini A, Grimaldi G. Use of the circular compression stapler and circular mechanical stapler in the end-to-side transanal colorectal anastomosis after left colon and rectal resections A single center experience. *Ann Ital Chir.* 2016;87:23-30.
3. Rullier E, Laurent C, Bretagnol F, Rullier A, Vendrely V, Zerbib F. Sphincter-saving resection for all rectal carcinomas: the end of the 2-cm distal rule. *Ann Surg.* 2005;241:465-469.
4. Lazorthes F, Fages P, Chiotasso P, Lemozy J, Bloom E. Resection of the rectum with construction of a colonic reservoir and colo-anal anastomosis for carcinoma of the rectum. *Br J Surg.* 1986;73:136-138.
5. Parc R, Tiret E, Frileux P, Moszkowski E, Loygue J. Resection and colo-anal anastomosis with colonic reservoir for rectal carcinoma. *Br J Surg.* 1986;73:139-141.
6. Z'graggen K, Maurer CA, Büchler MW. Transverse coloplasty pouch. A novel neorectal reservoir. *Dig Surg.* 1999;16:363-366.
7. Maurer CA, Z'graggen K, Zimmermann W, Häni HJ, Mettler D, Büchler MW. Experimental study of neorectal physiology after formation of a transverse coloplasty pouch. *Br J Surg.* 1999;86:1451-1458.
8. Williamson ME, Lewis WG, Finan PJ, Miller AS, Holdsworth PJ, Johnston D. Recovery of physiologic and clinical function after low anterior resection of the rectum for carcinoma: myth or reality? *Dis Colon Rectum.* 1995;38:411-418.
9. Karanjia ND, Schache DJ, Heald RJ. Function of the distal rectum after low anterior resection for carcinoma. *Br J Surg.* 1992;79:114-116.
10. Lee SJ, Park YS. Serial evaluation of anorectal function following low anterior resection of the rectum. *Int J Colorect Dis.* 1998;13:241-246.
11. Z'graggen K, Maurer CA, Birrer S, Giachino D, Kern B, Büchler MW. A new surgical concept for rectal replacement after low anterior resection. The transverse coloplasty pouch. *Ann Surg.* 2001;234:780-787.
12. Königer JS, Butters M, Redecke JD, Z'graggen K. Transverse coloplasty pouch after total mesorectal excision: functional assessment of evacuation. *Dis Colon Rectum.* 2004;47:1586-1593.
13. Hida J, Yasutomi M, Fujimoto K, Okuno K, Ieda S, Machidera N, Kubo R, Shindo K, Koh K. Functional outcome after low anterior resection with low anastomosis for rectal cancer using the colonic J-pouch: prospective randomized study for determination of optimum pouch size. *Dis Colon Rectum.* 1996;39:986-991.
14. Dehni N, Parc R. Colonic J-pouch-anal anastomosis for rectal cancer. *Dis Colon Rectum.* 2003;46:667-675.
15. Ho YH, Wong J, Goh HS. Level of anastomosis and anorectal manometry in predicting function following anterior resection for adenocarcinoma. *Int J Colorectal Dis.* 1993 Sep;8(3):170-4.
16. Cirocchi R, Campanile FC, Di Saverio S, Popivanov G, Carlini L, Pironi D, Tabola R, Vettoretto N. Laparoscopic versus open colectomy for obstructing right colon cancer: A systematic review and meta-analysis. *J Visc Surg.* 2017 Nov 4.
17. Pontone S, Hassan C, Maselli R, Pontone P, Angelini R, Brighi M, Patrizi G, Pironi D, Magliocca FM, Filippini A. Multiple, zonal and multi-zone adenoma detection rates according to quality of cleansing during colonoscopy. *United European Gastroenterol J.* 2016 Dec;4(6):778-783.
18. Pontone S, Cicerone C, Magliocca FM, Pironi D, Sorrenti S, Filippini A, Iafrate F. Intestinal neurofibromatosis found on surveillance colonoscopy. *Tech Coloproctol.* 2017 Feb;21(2):171-174.
19. Boselli C, Cirocchi R, Gemini A, Grassi V, Avenia S, Polistena A, Sanguinetti A, Burattini MF, Pironi D, Santoro A, Tabola R, Avenia N. Surgery for colorectal cancer in elderly: a comparative analysis of risk factor in elective and urgency surgery. *Aging Clin Exp Res.* 2017 Feb;29(Suppl 1):65-71.
20. Boselli C, Gemini A, Cirocchi R, Grassi V, Avenia S, Polistena A, Sanguinetti A, Pironi D, Santoro A, Tabola R, Burattini MF, Avenia N. Is it safe and useful, laparoscopic peritoneal lavage in the treatment of acute diverticulitis of octogenarian patients? A multicenter retrospective observational study. *Aging Clin Exp Res.* 2017 Feb;29(Suppl 1):83-89.
21. Pontone S, Palma R, Panetta C, Pironi D, Eberspacher C, Angelini R, Pontone P, Catania A, Filippini A, Sorrenti S. Endoscopic mucosal resection in elderly patients. *Aging Clin Exp Res.* 2017 Feb;29(Suppl 1):109-113.
22. Parisi A, Gemini A, Desiderio J, Petrina A, Trastulli S, Grassi V, Sani M, Pironi D, Santoro A. Laparoscopic peritoneal lavage: our experience and review of the literature. *Wideochir Inne Tech Maloinwazyjne.* 2016;11(2):83-7.
23. Parisi A, Trastulli S, Ricci F, Regina R, Cirocchi R, Grassi V, Gemini A, Pironi D, D'Andrea V, Santoro A, Desiderio J. Analysis of long-term results after liver surgery for metastases from colorectal and non-colorectal tumors: A retrospective cohort study. *Int J Surg.* 2016 Jun;30:25-30.
24. Panarese A, Pironi D, Vendettuoli M, Pontone S, Arcieri S, Conversi A, Romani AM, Filippini A. Stapled and conventional Milligan-Morgan haemorrhoidectomy: different solutions for different targets. *Int J Colorectal Dis.* 2012 Apr;27(4):483-7.
25. Pontone S, Leonetti G, Lamazza A, Fiocca F, Filippini A, Fanello G, Cereatti F, Fiori E, Angelini R, Patrizi G, Brighi M, Vetere S, Antoniozzi A, Pironi D, Manfredelli S, Pontone P. A Retrospective Case-Control Study Evaluating the Bowel Preparation Quality during Surveillance Colonoscopy after Colonic Resection. *ISRN Gastroenterol.* 2014 Mar 6;2014:681978.
26. Panunzi A, D'Orazi V, Toni F, Coppola GA, D'Alessandro V, Pontone S, Pironi D, Ortensi A. Unexpected granular cell tumor in abdominal wall: case report and literature review. *Tumori.* 2012 Jan-Feb;98(1):e18-21.
27. Pironi D, Candioli S, Manigrasso A, La Torre V, Palazzini G, Romani AM, Tarroni D, Filippini A. Complicated diverticular disease. Three cases of colovesical fistulas and review of literature. *G Chir.* 2006 Jan-Feb;27(1-2):15-20.
28. Candioli S, Manigrasso A, Pironi D, La Torre V, Panarese A, Belfiore C, Palazzini G, Tarroni D. Pelvic abscesses. Treatment modalities and personal experience. *G Chir.* 2004 Oct;25(10):356-60.
29. Parray FQ, Magray JA, Dar MA, Chowdri NA, Wani RA, Thakur N. Coloplasty Neorectum versus Straight Anastomosis in Low Rectal Cancers. *ISRN Surg.* 2014 Jan 30;2014:382371.