

## Non-functioning parathyroid cystic tumour: malignant or not? Report of a case

G. COCORULLO<sup>1</sup>, G. SCERRINO<sup>1</sup>, G. MELFA<sup>1</sup>, C. RASPANTI<sup>1</sup>, G. ROTOLO<sup>1</sup>, V. MANNINO<sup>1</sup>, P. RICHIUSA<sup>2</sup>, D. CABIBI<sup>3</sup>, A.G. GIANNONE<sup>3</sup>, C. PORRELLO<sup>1</sup>, G. GULOTTA<sup>1</sup>

**SUMMARY: Non-functioning parathyroid cystic tumour: malignant or not? Report of a case.**

G. COCORULLO, G. SCERRINO, G. MELFA, C. RASPANTI, G. ROTOLO, V. MANNINO, P. RICHIUSA, D. CABIBI, A.G. GIANNONE, C. PORRELLO, G. GULOTTA

*Parathyroid carcinoma (PC) is a very rare endocrine tumour, usually characterized by symptoms such as a neck mass, dysphonia, severe hypercalcemia exceeding 140 mg/L and elevated serum parathyroid hormone levels, even more than 5 times the upper limit of normal. Non-functioning parathyroid cancer is extremely rare and, in this case, its pre-operative diagnosis is often difficult.*

*A 54-year old female patient, referring dysphagia and dysphonia,*

*underwent neck ultrasound and neck CT. A left thyroid nodule, probably cystic, was found. It presented caudal extent on anterior mediastinum causing compression of the left lateral wall of the trachea. The preoperative calcemia was into the normal range.*

*The patient underwent left thyroid lobectomy. Histological exam showed a cystic lesion, immunohistochemically originating from parathyroid that oriented for carcinoma. The 18 months follow-up did not show a residual-recurrent disease.*

*The parathyroid origin of a neck lesion could not be suspected before surgery when specific laboratory tests are not available and clinical effects of hyperparathyroidism syndrome are not present. Histological features are not always sufficient for the differential diagnosis between the parathyroid adenoma and carcinoma. The immunohistochemistry is an useful tool that can aid to reach the definite diagnosis.*

KEY WORDS: Parathyroid carcinoma - Cystic thyroid nodule - Immunohistochemistry.

## Background

Parathyroid carcinoma (PC) is a very rare endocrine malignancy. It represents 0.005% of all cancers and less than 1% of cases of PHPT in the United States. It affects men and women equally, and its management and outcome are still debated (1, 2). It is a potentially lethal disease of the parathyroid glands, usually functioning, causing severe primary hyperparathyroidism, with high serum calcium and parathyroid hormone (PTH) levels (3, 4). Non-functioning PC, presenting with PTH within the normal range is considered rare (5, 6), although its frequency seems to be of 10-25% (3, 4, 7, 8).

In broad terms, the parathyroid tumours are classified as either parathyroid adenoma (PA) or aggressive parathyroid tumours (APA or PC). The sex distribution is significantly different between the classical PA and the APA groups; there are more females in the classical PA group, whereas there are more males in the APA group (3). Serum Ca levels are significantly higher in the PC group (1). The aetiology of PC remains unknown, but patients with a family history of hyperparathyroidism or a personal history of neck irradiation seem to be at increased risk of developing this disease (6, 9). The clinical presentation of parathyroid carcinoma is an overlap with that of PA, in fact the diagnosis is rarely made preoperatively. The pre-operative diagnosis of PC is often difficult also because available literature data are not homogenous and there is not a common operative guideline. The final diagnosis is made according to histopathological exam (5). Several signs are suggestive of carcinoma, such as a neck mass, dysphonia, severe hypercalcemia exceeding 140 mg/L and elevated serum parathyroid hormone levels, usually more than 5 times the upper limit of normal (7).

The presentation with classic symptoms of benign pri-

<sup>1</sup> Unit of General and Emergency Surgery, "Policlinico P. Giaccone", University of Palermo, Palermo, Italy

<sup>2</sup> Unit of Endocrinology, Di.Bi.M.I.S., "Policlinico P. Giaccone", University of Palermo, Palermo, Italy

<sup>3</sup> Department of Sciences for Promotion of Health and Mother and Child Care "G. D'Alessandro", University of Palermo, Palermo, Italy

Corresponding author: Cristina Raspanti, e-mail: cristinaraspanti@yahoo.it

© Copyright 2017, CIC Edizioni Internazionali, Roma

mary hyperparathyroidism occurs less often, and the diagnosis of normocalcemic hyperparathyroidism has become more common (8).

Although the association of parathyroid and thyroid disorders is quite common, the coexistence of parathyroid carcinoma and thyroid disease is rare (10). Concerning the cystic thyroid nodule, it is often associated with very mild manifestations. Its diagnosis is based on FNAB, but any degeneration that can be found, makes its evaluation more difficult. Large nodules with cystic degeneration also have higher probability of malignancy; thus, non-diagnostic specimens from such nodules most likely result in failure or delay of diagnosis of thyroid malignancy (10). Nodule volume neither significantly alters the sampling number necessary for achieving specimen adequacy nor affects the total time required for US-guided thyroid FNAB (11, 12).

## Case report

A 54-year old female patient was referred to our department complaining dysphagia and dysphonia. The neck ultrasound showed a 4.5 cm left thyroid cystic nodule, with regular margin, associated to an unexplained ipsi-lateral vocal fold paralysis showed from the appearance of hoarseness. Thyroid functional tests, serum calcium and plasma PTH were into the normal range. A neck CT was also performed, which showed, on the left side, a nodular lesion, apparently originating from the thyroid lobe, with homogeneous density (36 UH) of 4.6 x 4.8 cm, which compresses the thyroid lobe, presents caudal extension on anterior mediastinum and causes compression of the left lateral wall of the trachea. A thyroid cystic nodule was diagnosed and a fine-needle aspiration biopsy (FNAB) was then performed twice, which showed a cellular pattern characterized by scarcity of thyrocytes [Bethesda 1 according to Bethesda system for reporting thyroid cytopathology, or TIR 1-C according to the Italian cytological classification (13) in both samplings]. A left conventional thyroid lobectomy was then programmed, the recurrent laryngeal nerve was not involved in the cystic mass and the superior parathyroid gland was found in the typical site; on the contrary, the inferior parathyroid gland was not found in the usual site. Gross examination showed a multi-cystic lesion, measuring 6 cm in maximum diameter, that involved the entire left lobe of thyroid gland. Microscopically, the cystic spaces were lined by several layers of small monomorphic polygonal cells, with clear cytoplasm, round nuclei, and mild atypia (Figure 1 a, b). These cells formed irregular solid nests within the fibrous wall. The cystic spaces showed thick fibrous walls with fibrous septa. The morphological and immunohistochemical features (chromogranin A+, HBME1+, TTF1,

thyroglobulin-, calcitonin-) (Figure 1 c, d, h, i, j, k) were consistent with parathyroid cells, more likely chief cells. The infiltrative growth pattern within the fibrous walls, together with the immunohistochemical positivity for Galectin 3, Cyclin D1 (Figure 1 e, f) and Ki67 (accounting for 7% of neoplastic cells), the loss of MDM2 (Figure 1 g), suggest a potentially malignant behaviour (14-16).

Thus, the overall histopathologic features were consistent with an intrathyroid cystic parathyroid carcinoma and make the worthy framework of close follow-up.

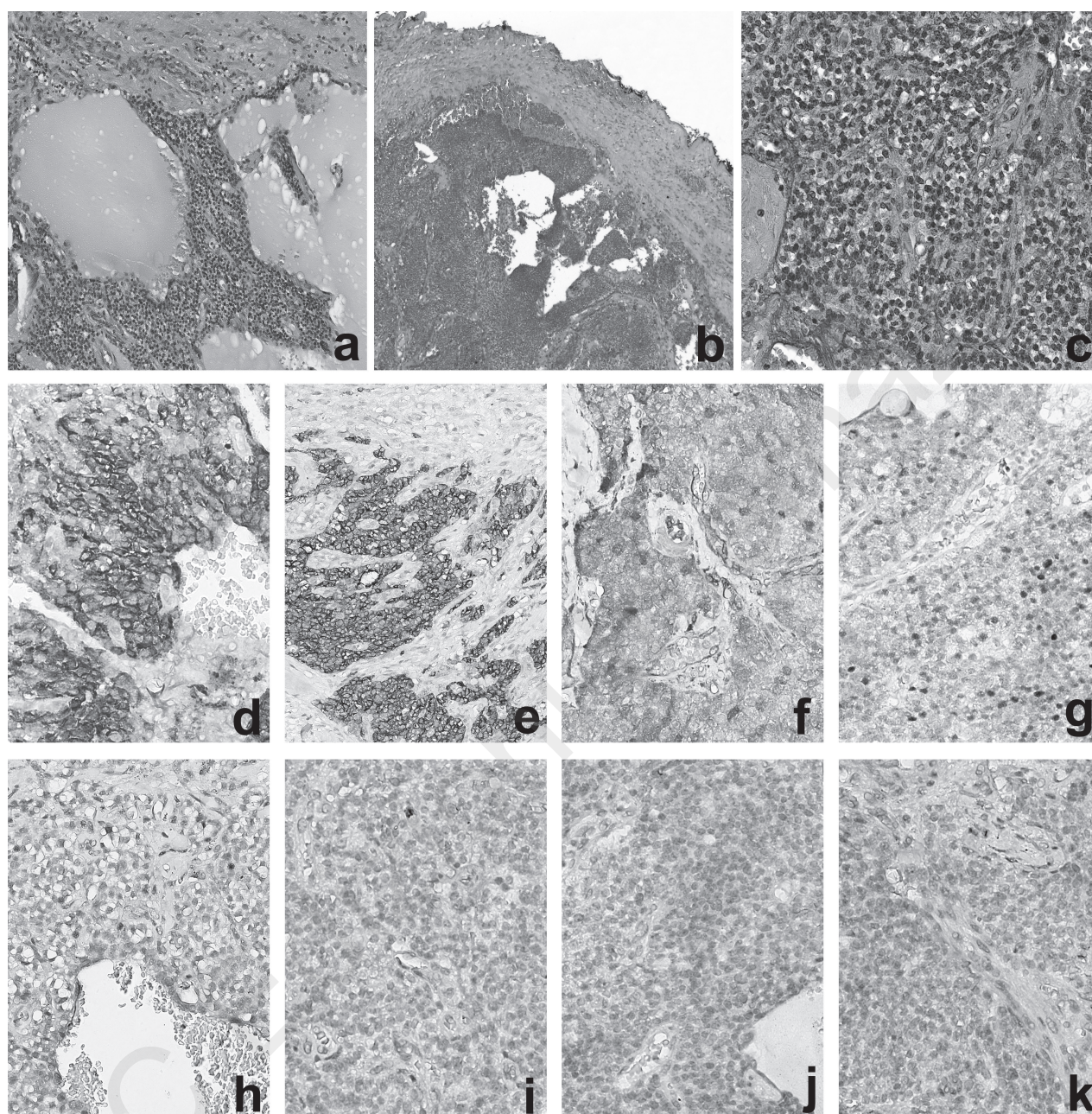
Postoperative serum calcium and phosphate levels were within the normal range. The genetic screening for the CDC73 mutation (jaw tumor syndrome) was also performed owing to the cystic character of the mass, and it resulted negative. One year after surgery, serum calcium and PTH were near the normal range (respectively 9.2 mg/dl and 71 pg/ml) and a neck scintigraphy and total body computed tomography scan were negative for local and metastatic disease (Figures 2, 3).

## Discussion

Parathyroid carcinoma usually appears with severe hypercalcemia, and elevated serum PTH level and frequently presents a neck mass that in the non-functioning variants may be an isolated sign. It can be associated to jaw-tumour syndrome, a rare autosomal disease in which a loss of parafibromin expression, as a consequence of inactivating germ-line mutations of HRPT2 gene, is observed (17, 18). The treatment of choice of the PC is surgical. An "en bloc" resection of the primary mass and surrounding tissues involved (adherent or infiltrated) is the widely accepted surgical option. The prognosis depends on the complete resection of the tumour: if the margins of resection are free of neoplastic tissue it is probable to obtain a good prognosis (5-7, 19-20).

The non-functioning PC is even more rare. The first description dates back to 1909, two more cases were published during the early XX century and, to our knowledge, only 32 more cases have been described up to now (21, 22). In accordance with these cases, the early diagnosis is difficult because of the lack of signs of hyperparathyroidism. Moreover, the absence of hypercalcemia do not lead to a PTH preoperative dosage, so just a few preoperative information are available on this subject. The sign mainly noticed seems to be the neck mass, even ulcerated, dysphagia and hoarseness (19, 20, 23, 24). The mechanisms involved in the non-secretory behaviour are not completely clarified. The accumulation of secretory granules, described in some cases (9) takes up the impaired hormone secretion. A hormone synthesis failure is indicated from a reduced mitochondrial rough endoplasmic reticulum in association with reduced Golgi ap-





**Figure 1 - Microscopic images.**

paratus and secretory granules (30). A production of an inactive hormone, or its intermittent production can be supposed with the finding of mRNA coding for a PTH precursor (25). No data concerning the grading and the staging of the disease are actually available.

The only classification criteria are those proposed by Schulte et al., in which the cut-off between low-risk and high-risk cancers is defined from the lymph node metastases and the involvement of the major anatomical neck structures, such as trachea, oesophagus and major neck

vessels (26). Although several diagnostic exams have been proposed for the diagnosis of the PC, neck ultrasound is the most reliable for the initial diagnosis. This is a cost saving exam, non-invasive and sensitive. The principal limitation is the intrathyroidal gland (27, 28). The diagnostic value of CT and Magnetic Resonance is inferior to that of ultrasound (9). The role of the FNAB is still debated. In fact, the results of the cytology are often similar in parathyroid and thyroid lesions; moreover, the parathyroid tumours have not always specific signs (3).



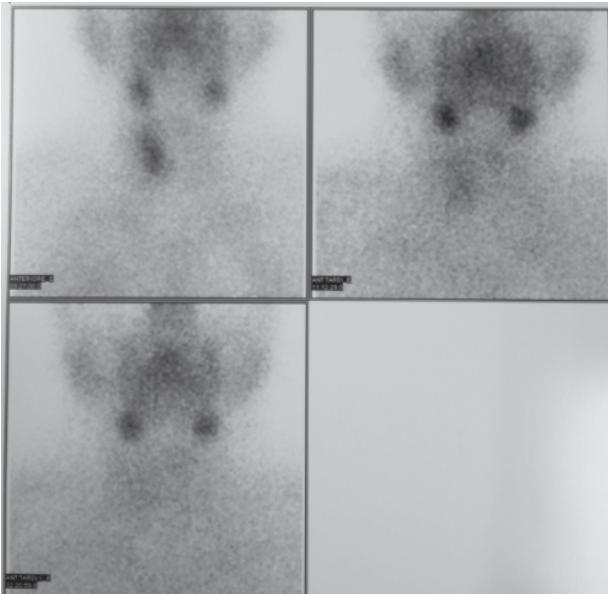


Figure 2 - Neck scintigraphy one year after surgery.

A cell spreading along the biopsy tract has also been described (29).

This is a rare case of non-functioning cystic parathyroid cancer misdiagnosed prior to surgery as a cystic thyroid nodule. FNAB failed to distinguish the parathyroid tumour from a benign thyroid nodule because at FNAB the inadequacy in identifying the cellular pattern could be caused by sampling error or sample processing (5, 6). A sample properly crawled, and colorful set that contains at least six groups consist of 10 well-preserved epithelial cells is considered appropriate. Fluid and foamy degenerating cells, erythrocytes, areas of necrosis, macrophages and hemosiderin embedding thyrocytes in insufficient quantities may confuse the diagnosis of a specific pattern. These findings define a TIR 1C scoresheet, in which no cells (thyrocytes nor parathyrocytes) were found. The cystic shape and the intrathyroidal location of the focal lesion led us to perform a FNAB that resulted non-conclusive. On the other hand, we think that the lack of knowledge directing towards a parathyroid origin leads to a FNAB for evaluating this neck mass (11, 30-32). In the absence of hypercalcaemia, the pre-operative parathyroid origin of the neck lump cannot be established. Moreover, at histological level, the differential diagnosis among parathyroid proliferative lesions, in particular between adenoma and carcinoma, is challenging. Histological features are not always enough for the differential diagnosis. The issue is more complicated in parathyroid cystic lesions. Some immunohistochemical features can aid to solve this diagnostic issue and several markers have been evaluated to further improve the diagnostic accuracy of

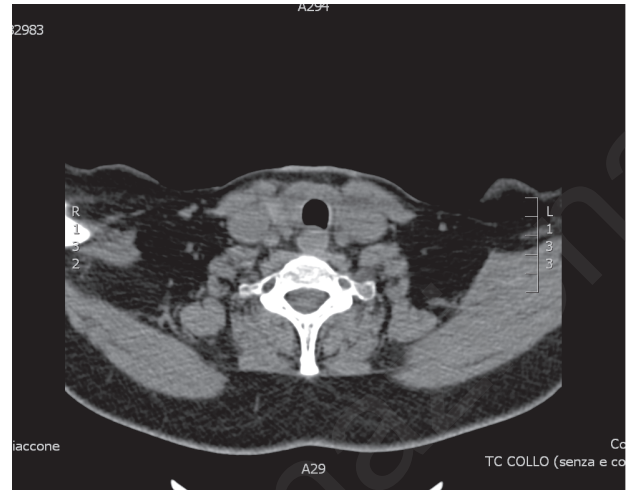


Figure 3 - Total computed tomography one year after surgery.

a non-functioning parathyroid cyst (3, 5, 8, 24, 33-39).

Parathyroid cysts are more common in women, usually arising from the lower glands but can be located in the upper region of the neck or in the mediastinum (40-42).

About the 10% of parathyroid cysts that are associated with hypercalcaemia (functioning cysts) demonstrate a male preponderance and invariably contain elevated C-terminal PTH (C-PTH) levels (43).

The diagnosis of non-functioning parathyroid cyst is often difficult, often being misdiagnosed as thyroid pathology and the final diagnosis is made during surgery confirmed by histopathological examination (44).

The symptoms of nonfunctioning cysts are limited to those caused by compression of neighbouring structures whereas the problems associated with functioning cysts are related to excessive secretion of PTH and subsequent hyperparathyroidism and hypercalcaemia (45-47).

Hughes et al. showed that T1-201-Tc-99m pertechnetate subtraction scintigraphy, CT, and US were unable to distinguish parathyroid cysts from thyroid nodules and failed to demonstrate the exact origin of cystic neck masses (48).

Despite the ability to detect parathyroid cysts preoperatively, many parathyroid cysts are only diagnosed postoperatively. For those identified preoperatively, treatment can be controversial. Although rare, two cases of parathyroid cyst carcinoma have been reported in the literature. Both of these cases have arisen in functioning cysts, with no report of carcinoma in nonfunctioning cysts (55, 56).

The surgical treatment of PC, especially for the non-functioning variant, is still controversial although the resection of the carcinoma "en bloc" with the involved structures and a lymph node dissection only if its involvement is clarified, seems a reasonable behaviour (5,



53, 54). Long-term follow-up and information on mortality are not available, but the advanced stage of the PC at diagnosis likely predict a poor prognosis, worse than that of patients with classical hypercalcemic PC (2, 7, 9, 49-53). In the present case, we preferred to perform a thyroid lobectomy because of the pre-existent ipsi-lateral vocal fold paralysis and for taking the opportunity of avoiding the possible sequelae and complications of the total thyroidectomy (57-59). An emostatic agent (gelatin-thrombin matrix) was used with the aim of preventing postoperative emorrhage (60, 61). As a preoperative diagnosis was not available, we did not use an intraoperative diagnostic tool for reducing the risk of residual parathyroid disease (59, 62, 63). The genetic screening for the mutation of the CDC73 gene, although negative, was justified according to the indications in the presence of a cystic lesion of a parathyroid gland (64).

## Conclusion

Parathyroid carcinoma is a rare endocrine tumour; its association with thyroid disease is not frequent and no reliable predictive markers are available.

Often, the parathyroid nature of a neck lesion

could not be suspected before surgery when laboratory and clinical effects by hyperparathyroidism syndrome are not available. Histological criteria are not always enough for the differential diagnosis between adenoma and carcinoma of the parathyroid gland, especially when the lesion shows unusual location and growth pattern. In our case, the lesion was intrathyroidal and presented as a cystic nodule, lined by several layers of monotonous cells with infiltrative growth pattern within the fibrous walls, without other obvious signs of malignancy (e.g. infiltration of blood vessels, distant metastases). In such cases, other histological techniques, as immunohistochemistry, are mandatory to outline the phenotype and can provide useful information about the biology of the lesion. The immunohistochemical positivity for Galectin 3 and Cyclin D1, the proliferation index (Ki67) accounting for 7% of neoplastic cells, together with the loss of MDM2 are features frequently reported in association with a malignant behaviour.

Thus, the overall histopathologic features were consistent with an intrathyroid cystic parathyroid carcinoma, although the final diagnosis remains uncertain one year after the surgical operation, owing to the good prognosis, that is unusual in the presence of a parathyroid malignancy.

## References

1. Cakir B, Polat SB, Kilic M, Ozdemir D, Aydin C, Süngü N, Ersoy R. Evaluation of preoperative ultrasonographic and biochemical features of patients with aggressive parathyroid disease: is there a reliable predictive marker? *Arch Endocrinol Metab.* 2016;60(6):537-544. doi: 10.1590/2359-3997000000224.
2. Marcocci C, Cetani F, Rubin MR, Silverberg SJ, Pinchera A, Bilezikian JP. Parathyroid carcinoma. *J Bone Miner Res.* 2008;23:1869-80. doi:10.1359/jbmr.081018.
3. Giessler GA, Beech DJ. Nonfunctional parathyroid carcinoma. *JNMA.* 2001;93:251-255.
4. Melfa GI, Raspanti C, Attard M, Cocorullo G, Attard A, Mazzola S, Salamone G, Gulotta G, Scerrino G. Comparison of minimally invasive parathyroidectomy under local anaesthesia and minimally invasive video-assisted parathyroidectomy for primary hyperparathyroidism: a cost analysis. *G Chir.* 2016;37(2):61-7.
5. Doina P, Alexandru I, George K, Andra P, Rares B. Highly aggressive pathology of non-functional parathyroid carcinoma. *Orphanet J Rare Dis.* 2013;8:115. doi: 10.1186/1750-1172-8-115.
6. Cetani F, Frustaci G, Torregrossa L, Magno S, Basolo F, Campomori A, Miccoli P, Marcocci C. A nonfunctioning parathyroid carcinoma misdiagnosed as a follicular thyroid nodule. *World J Surg Oncol.* 2015;8:13:270. doi: 10.1186/s12957-015-0672-9.
7. Christakis I, Silva AM, Kwatampora LJ, Warneke CL, Clarke CN, Williams MD, Grubbs EG, Lee JE, Busaidy NL, Perrier ND. Oncologic progress for the treatment of parathyroid carcinoma is needed *J Surg Oncol.* 2016;114(6):708-713. doi: 10.1002/jso.24407.
8. Aldinger KA, Hickey RC, Ibanez ML, Samaan MA. Parathyroid carcinoma: a clinical study of seven cases of functioning and two case of nonfunctioning parathyroid cancers. *Cancer.* 1982;49(2):388-97.
9. Wang L, Han D, Chen W, Zhang S, Wang Z, Li K, Gao Y, Zou S, Yang A. Non-functional parathyroid carcinoma: a case report and review of the literature. *Cancer Biol Ther.* 2015;16(11):1569-76.
10. Scerrino G, Attard M, Lo Piccolo C, Attard A, Melfa GI, Raspanti C, Zarcone M, Bonventre S, Mazzola S, Gulotta G. The coexistence of primary hyperparathyroidism and thyroid nodules: should the preoperative work-up of the parathyroid and the thyroid diseases be specifically adjusted? *G Chir.* 2016;37(3):123-9.
11. Cengic I, Tureli D, Altas H, Ozden F, Bugdayci O, Aribal E. Effects of nodule characteristics on sampling number and duration of thyroid fine-needle aspiration biopsy: size does not matter, but cystic degeneration ratio does. *Acta Radiol.* 2016;27. pii: 0284185116649797.
12. Romano G, Scerrino G, Profita G, Amato G, Salamone G, Di Buono G, Lo Piccolo C, Sorce V, Agrusa A, Gulotta G. Terminal or truncal ligation of the inferior thyroid artery during thyroidectomy? A prospective randomized trial. *Int J Surg.* 2016;28 Suppl 1:S13-6. doi: 10.1016/j.ijsu.2015.05.057.
13. Guido F, Rossi ED. The 2014 Italian Reporting System for Thy-

- roid Cytology: Comparison with the National Reporting Systems and Future Directions. *Journal of Basic & Clinical Medicine*. 2015;4(2):46-51.
14. Saggiorato E, Bergero N, Volante M, Bacillo E, Rosas R, Gasparri G, Orlandi F, Papotti M. Galectin-3 and Ki-67 expression in multiglandular parathyroid lesions. *Am J Clin Pathol*. 2006;126(1):59-66.
15. Cay T. Immunohistochemical expression of galectin-3 in cancer: a review of the literature. *Turk Patoloji Derg*. 2012;28(1):1-10.
16. Truran PP, Johnson SJ, Bliss RD, Lennard TW, Aspinall SR. Parafibromin, galectin-3, PGP9.5, Ki67, and cyclin D1: using an immunohistochemical panel to aid in the diagnosis of parathyroid cancer. *World J Surg*. 2014;38(11):2845-54.
17. Iacobone M, Masi G, Barzon L, Porzionato A, Macchi V, Ciarleglio FA, Palù G, De Caro R, Viel G, Favia G. Hyperparathyroidism-jaw tumor syndrome: a report of three large kindred. *Langenbecks Arch Surg*. 2009;394(5):817-25.
18. Masi G, Iacobone M, Sinigaglia A, Mantelli B, Pennelli G, Castagliuolo I, Palù G, Barzon L. Characterization of a new CDC73 missense mutation that impairs Parafibromin expression and nucleolar localization. *PLoS One*. 2014;9(5):e97994. doi: 10.1371/journal.pone.0097994.
19. Shane E. Clinical review 122: parathyroid carcinoma. *J Clin Endocrinol Metab*. 2001;86:485-93.
20. Wilkins BJ, Lewis Jr JS. Non-functional parathyroid carcinoma: a review of the literature and report of a case requiring extensive surgery. *Head and Neck Pathol*. 2009;3:140-9.
21. Quervain FD. Parastruma maligna aberrata[J]. *Langenbeck's Arch Surg*. 1909;100:334-53.
22. Dhom G, Hohbach C. The value of electron microscopy in diagnostic pathology. Case 12. *Ultrastruct Pathol*. 1980;1(1):141-50.
23. Scerrino G, Inviati A, Di Giovanni S, Paladino NC, Di Paola V, Lo Re G, Almasio PL, Cupido F, Gulotta G, Bonventre S. Esophageal motility changes after thyroidectomy: possible associations with postoperative voice and swallowing disorders: preliminary results. *Otolaryngol Head Neck Surg*. 2013;148(6):926-32. doi: 10.1177/0149599813482299.
24. Baba H, Kishihara M, Tohmon M, Fukase M, Kizaki T, Okada S, Matsuzuka F, Kobayashi A, Kuma K, Fujita T. Identification of parathyroid hormone messenger ribonucleic acid in an apparently nonfunctioning parathyroid carcinoma transformed from a parathyroid carcinoma with hyperparathyroidism. *J Clin Endocrinol Metab*. 1986;62(2):247-52.
25. Haven CJ, Howell VM, Eilers PH, Dunne R, Takahashi M, van Puijenbroek M, et al. Gene expression of parathyroid tumors: molecular subclassification and identification of the potential malignant phenotype. *Cancer Res*. 2004;64:7405-11.
26. Schulte KM, Jill AJ, Barkzynski M, Karakas E, Miyauchi A, Knoefel WT, Lombardi CP, Talat N, Diaz-Cano S, Grant CS. Classification of parathyroid cancer. *Ann Surg Oncol*. 2012;19(8):260-8.
27. Reeder SB, Desser TS, Weigel RJ, Jeffrey RB. Sonography in primary hyperparathyroidism: review with emphasis on scanning technique. *J Ultrasound Med*. 2002;21:539-52.
28. Haber RS, Kim CK, Inabnet WB. Ultrasonography for preoperative localization of enlarged parathyroid glands in primary hyperparathyroidism: comparison with (99m)technetium sestamibi scintigraphy. *Clin Endocrinol*. 2002;57:241-9. doi:10.1046/j.1365-2265.2002.01583.
29. Spinelli C, Bonadio AG, Berti P, Materazzi G, Miccoli P. Cutaneous spreading of parathyroid carcinoma after fine-needle aspiration cytology. *J Endocrinol Invest*. 2000;23(4):255-7.
30. O'Neal P, Mowschenson P, Connolly J, Hasselgren PO. Large parathyroid tumors have an increased risk of atypia and carcinoma. *Am J Surg*. 2011;202:146-50.
31. Baser H, Cakir B, Topaloglu O, Alkan A, Polat SB, Dogan HT, Yazicioğlu MO, Aydin C, Ersoy R. Diagnostic accuracy of Thyroid Imaging Reporting and Data System in the prediction of malignancy in nodules with atypia and follicular lesion of undetermined significance cytologies. *Clin Endocrinol (Oxf)*. 2016 Nov 7. doi: 10.1111/cen.13274.
32. Tartaglia F, Giuliani A, Tromba L, Carbotta S, Karpathiotakis M, Tortorelli G, Pelle F, Merola R, Donello C, Carbotta G, De Anna L, Conzo G, Sorrenti S, Ulisse S. Fine needle aspiration cytology of 650 thyroid nodules operated for multinodular goiter: a cyto-histological correlation based on the new Italian cytological classification (siapec 2014). *J Biol Regul Homeost Agents*. 2016 Oct-Dec;30(4):1187-93.
33. DeLellis RA. Parathyroid tumors and related disorders. *Mod Pathol*. 2011;24:S78-93. doi: 10.1038/modpathol.2010.132.
34. Guarnieri V, Scillitani A, Muscarella LA, Battista C, Bonfitto N, Bisceglia M, et al. Diagnosis of parathyroid tumors in familial isolated hyperparathyroidism with HRPT2 mutation: implications for cancer surveillance. *J Clin Endocrinol Metab*. 2006;91:2827-32. doi: 10.1210/jc.2005-1239.
35. Harari A, Waring A, Fernandez-Ranvier G, Hwang J, Suh I, Mitmaker E, et al. Parathyroid carcinoma: a 43-year outcome and survival analysis. *J Clin Endocrinol Metab*. 2011;96:3679-86.
36. Arribas B, Cristobal E, Alcazar JA, Tardio J, Matinez-Montero JC, Polo JR, Carrion R, Gil L, Azanedo M, Rojas JM, Menarguez J. p53/MDM2 Pathway Aberrations in Parathyroid Tumors: p21(WAF-1) and MDM2 Are Frequently Overexpressed in Parathyroid Adenomas. *Endocr Pathol*. 2000;11(3):251-257.
37. Scerrino G, Attard A, Melfa GI, Raspanti C, Di Giovanni S, Attard M, Inviati A, Mazzola S, Modica G, Gulotta G, Bonventre S. Role of prophylactic central neck dissection in cN0-papillary thyroid carcinoma: results from a high-prevalence area. *Minerva Chir*. 2016;71(3):159-67. Epub 2015 Jun 5.
38. Cay T. Immunohistochemical expression of galectin-3 in cancer: a review of the literature. *Turk Patoloji Derg*. 2012;28(1):1-10.
39. Juhlin CC, Villablanca A, Sandelin K, Haglund F, Nordenstrom J, Forsberg L, et al. Parafibromin immunoreactivity: its use as an additional diagnostic marker for parathyroid tumor classification. *Endocr Relat Cancer*. 2007;14(2):501-512.
40. Da Silva DA, Machado MC, Brito LL, Guimarães RA, Fava AS, Mamone MCAC. Parathyroid cysts: diagnosis and treatment. *Revista Brasileira de Otorrinolaringologia*. 2004;70(6):840-844.
41. Calandra DB, Shah KH, Prinz RA, Sullivan H, Hofmann C, Oslapas R, Ernst K, Lawrence AM, Paloyan E. Parathyroid cysts. A report of eleven cases including two associated with hyperparathyroid crisis. *Surgery*. 1984;94:887-892.
42. Shields TW, Immerman SC. Mediastinal parathyroid cysts revisited. *Ann Thorac Surg*. 1999;67:581-590.
43. Ippolito G, Palazzo FF, Sebag F, Sierra M, De Micco C, Henry JF. A single-institution 25-year review of true parathyroid cysts. *Langenbeck's Archives of Surgery*. 2006;391(1):13-18.
44. Mallette LE. The functional and Pathologic spectrum of parathyroid abnormalities in hyperparathyroidism. In: Bilezikian JP, Levine M, Marcus R, eds. *The parathyroids*. New York, NY: Raven Press; 1994:423-55.



45. Pontikides N, Karras S, Kaprara A. Diagnostic and therapeutic review of cystic parathyroid lesions. *Hormones*. 2012;11(4):410-418.
46. Fortson JK, Patel VG, Henderson VJ. Parathyroid cysts: a case report and review of the literature. *Laryngoscope*. 2001;111(10):1726-1728.
47. Goomany A, Rafferty A, Smith I. An Unusual Neck Mass: A Case of a Parathyroid Cyst and Review of the Literature. *Case Reports in Surgery*. 2015.
48. Hughes CR, Kanmaz B, Isitman AT, Akansel G, Lawson T, Collier BD. Misleading imaging results in the diagnosis of parathyroid cysts. *Clinical Nuclear Medicine*. 1994;19(5):422-425.
49. Munson ND, Foote RL, Northcutt RC. Parathyroid carcinoma: is there a role for adjuvant radiation therapy? *Cancer*. 2003;98:2378-84. doi: 10.1002/cncr.11819.
50. Schulte KM, Jill AJ, Barkzynski M, Karakas E, Miyauchi A, Knoefel WT, Lombardi CP, Talat N, Diaz-Cano S, Grant CS. Classification of parathyroid cancer. *Ann Surg Oncol*. 2012;19(8):260-8.
51. Shaha AR, Shah JP. Parathyroid carcinoma: a diagnostic and therapeutic challenge. *Cancer*. 1999;86(3):378-80.
52. Owen RP, Silver CE, Pellitteri PK, Shaha AR, Devaney KO, Werner JA, Rinaldo A, Ferlito A. Parathyroid Carcinoma: a review. *Head Neck*. 2011;33(3):429-36.
53. Merlano M, Conte P, Scarsi P, Tatarek R, Barbieri A, Santelli A, Scarpati D, De Angelis P. Non-functioning parathyroid carcinoma: a case report. *Tumori*. 1985;71(2):193-6.
54. Ambrogini E, Cetani F, Cianferotti L, Vignali E, Banti C, Viccica G, et al. Surgery or surveillance for mild asymptomatic primary hyperparathyroidism: a prospective, randomized clinical trial. *J Clin Endocrinol Metab*. 2007;92:3114-21.
55. Wright JG, Brangle RW. Carcinoma in a parathyroid cyst. *The Illinois Medical Journal*. 1985;168(2):98-100.
56. Pirundini P, Zarif A, Wihbey JG. A rare manifestation of parathyroid carcinoma presenting as a cystic neck mass. *Connecticut Medicine*. 1998;62(4):195-197.
57. Scerrino G, Melfa G, Raspanti C, Attard A, Mazzola S, Gullo R, Bonventre S, Attard M, Cocorullo G, Gulotta G. The prevalence of post-thyroidectomy chronic asthenia: a prospective cohort study. *Langenbecks Arch Surg*. 2017. doi: 10.1007/s00423-017-1568-7.
58. Scerrino G, Inviati A, Di Giovanni S, Paladino NC, Di Giovanni S, Paladino NC, Di Paola V, Raspanti C, Melfa GI, Cupido F, Mazzola S, Porrello C, Bonventre S, Gullotta G. Long-term esophageal motility changes after thyroidectomy: associations with aerodigestive disorders. *G Chir*. 2017;37(5):193-9.
59. Scerrino G, Di Giovanni S, Salamone G, Melfa G, Inviati A, Raspanti C, Gulotta G. Surgical complications in prophylactic central neck dissection: Preliminary findings from a retrospective cohort study. *Minerva Chir*. 2014;69(suppl. 1 to n. 2):131-4.
60. Docimo G, Tolone S, Conzo G, Limongelli P, Del Genio G, Parmeggiani D, De Palma M, Lupone G, Avenia N, Lucchini R, Monacelli M, Gulotta G, Scerrino G, Pasquali D, Bellastella G, Esposito K, De Bellis A, Pezzolla A, Ruggiero R, Docimo L. A Gelatin-Thrombin Matrix Topical Hemostatic Agent (FloSeal) in Combination With Harmonic Scalpel Is Effective in Patients Undergoing Total Thyroidectomy: A Prospective, Multicenter, Single-Blind, Randomized Controlled Trial. *Surg Innov*. 2016; 23(1):23-9. doi: 10.1177/1553350615596638. Epub 2015 Aug 3.
61. Scerrino G, Paladino NC, Di Paola V, Morfino G, Amodio E, Gulotta G, Bonventre S. The use of haemostatic agents in thyroid surgery: efficacy and further advantages. Collagen-Fibrinogen-Thrombin Patch (CFTP) versus Cellulose Gauze. *Ann Ital Chir*. 2013;84(5):545-50.
62. Scerrino G, Castorina S, Melfa GI, Lo Piccolo C, Raspanti C, Richiusa P, Costa RP, Gulotta G. The intraoperative use of the mini-gamma camera (MGC) in the surgical treatment of primary hyperparathyroidism: Technical reports and immediate results from the initial experience. *Ann Ital Chir*. 2015;86(3):212-8.
63. Guerin C, Paladino NC, Lowery A, Castinetti F, Taieb D, Sebag F. Persistent and recurrent hyperparathyroidism. *Updates Surg*. 2017. doi: 10.1007/s13304-017-0447-7.
64. Iacobone M, Citton M, Viel G, Schiavone D, Torresan F. Surgical approaches in hereditary endocrine tumors. *Updates Surg*. 2017. doi: 10.1007/s13304-017-0451-y.