

## Necrotizing fasciitis associated with primary cutaneous B-cell lymphoma. A case report

K.G. SPIRIDAKIS, D.S. INTZEPOGAZOGLOU, M.E. FLAMOURAKIS, E.E. SFAKIANAKIS, A.V. DASKALAKI, E.K. VAKONAKI, E. RAHMANIS, G.E. KOSTAKIS, M.S. CHRISTODOULAKIS

**SUMMARY: Necrotizing fasciitis associated with primary cutaneous B-cell lymphoma. A case report.**

K.G. SPIRIDAKIS, D.S. INTZEPOGAZOGLOU, M.E. FLAMOURAKIS, E.E. SFAKIANAKIS, A.V. DASKALAKI, E.K. VAKONAKI, E. RAHMANIS, G.E. KOSTAKIS, M.S. CHRISTODOULAKIS

*Necrotizing fasciitis is a rapidly progressive and life-threatening infection of the deeper skin layers and subcutaneous tissues that moves along the facial planes.*

*Objectives. We present the rare case of a patient with necrotizing fasciitis associated with high malignancy b-cell lymphoma. Our purpose is to investigate the probable connection between the two pathologies and evaluate the importance of early surgical intervention.*

*Case report. 51-year old Caucasian woman presented at the E.R. with history of a painful left thigh over a week and fever up to 38,4°C*

*over the last three days. Necrosis of the soft tissues and fascial planes were observed clinically. After the initial treatment and due to the patient's multiple organ dysfunction (septic shock), she was transferred to the ICU where she was intubated resuscitated with IV fluids and given IV antibiotics. 24 hours after the admission it was decided that the patient should undergo surgery and an extensive debridement of the necrotic area was performed. The antibiogram of the blood culture revealed streptococcus pyogenes and she was administered penicillin while intubated and monitored in the ICU until the seventh postoperative day. On the eighth post-day she was transferred back to the surgical department, hemodynamically normal and stable. She was discharged one month later and she was referred to a plastic surgery center for the final reconstruction surgery.*

*Conclusions. This case highlights that the high index of suspicion and the early aggressive surgical intervention seems to be very critical to improve survival of the patients with necrotizing fasciitis.*

KEY WORDS: Necrotizing fasciitis - Lymphoma - Surgical debridement.

### Introduction

Necrotizing fasciitis is a rapidly progressive inflammatory infection of the fascia with secondary necrosis of the subcutaneous tissue (1).

These infections are difficult to recognize in their early stage but they have an aggressive progress that can be often life threatening. Its presentation can occur anywhere in the body with the lower limb being most commonly affected. A fascial biopsy and histopathological analysis in numerous cases can be useful for the final diagnosis (2, 3).

The incidence of NF has been reported to be 0,40 cases per 100.000 adults (4). The mean age of the patients

with necrotizing fasciitis is middle aged and elderly patients (>50 years). Pediatric cases have also been reported. The male to female ratio is 2-3:1 (4, 7).

Necrotizing fasciitis was recognized in 500 BC by Hippocrates reported a complication of erysipelas disease similar to the current description of NF (4, 5).

Since 1883, more than 500 cases of necrotizing fasciitis have been reported in literature with an increased incidence in African and Asian countries. There are three recent collective reviews. The first was conducted by a team of surgeons in Portland, Oregon, in 2010, and included reference on the diagnosis and treatment of necrotizing fasciitis (6). The second, by Rausch and Foca (7), in 2011, reported these infections in pediatric patients. The third, by a Turkish team of surgeons and scientists in 2012, is a review on necrotizing fasciitis, which suggests that the early diagnosis of necrotizing fasciitis may be life saving (8).

All these collective reviews emphasize the importance of the early diagnosis, the difficulty of the final diagnosis, and that adjunctive therapies like hyperbaric oxygen can be useful in order to save these patients' lives.

Department of Surgery, General Hospital of Heraklion Crete, Venizelio, Greece

Corresponding author: Konstadinos G. Spiridakis, e-mail: spiridakisk@yahoo.gr

© Copyright 2017, CIC Edizioni Internazionali, Roma

## Case report

51-year old Caucasian woman presented at the E.R. with a painful left thigh and fever up to 38,2°C over the last three days. Her vital signs were BP: 100/50 mmHg, pulses: 95/min, SpO<sub>2</sub>: 99%, T:38,4°C. The clinical examination revealed extended edema and erythema of the left inner thigh which was warm and painful to touch. Besides the mild tachypnea, all other systems presented with no abnormal findings.

Left lower limb Doppler ultrasonography revealed significant edema of soft tissues in the inner thigh and no signs of deep vein thrombosis.

The patient was admitted to General Surgery Ward because of the suspected diagnosis of necrotizing fasciitis.

Her blood test results were: WBC: 6.100 (neu:88%/lym:4.7%), Hb: 10.1, Hct: 31.9%, PLT: 157.000, PT/INR: 16/1.4, APTT: 42.4, Glu: 107, Ur: 53, Cr: 2.94, SGOT/SGPT: 136/97, Na: 126, K: 3.8, CRP: 24.84.

Due to the patient's multiple organ dysfunction she was transferred to the ICU where she was intubated, resuscitated with IV fluids and given IV antibiotics (meropenem, clindamycin, daptomycin).

When the patient was re-evaluated by the General Surgeon's team the erythema has progressed and dusky patches had appeared. A small incision revealed yellowish necrotic fascia, and it was decided that the patient should

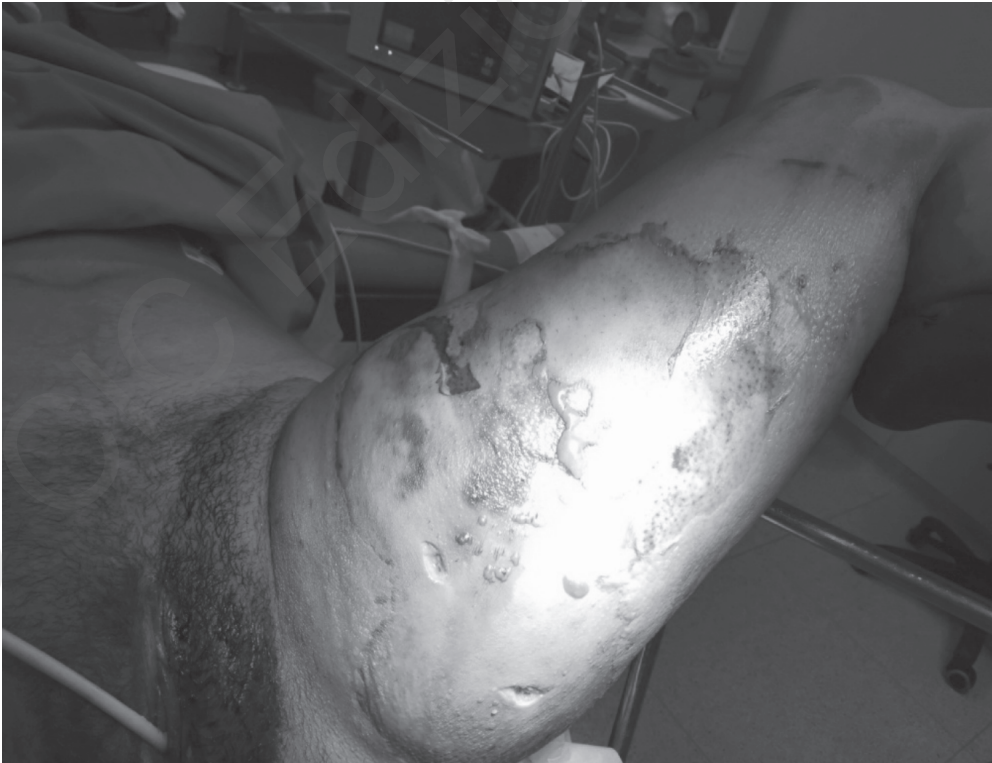undergo surgery (Figure 1). Extensive surgical debridement was performed, 24 hours after admission (Figure 2).

The antibiogram of blood culture revealed *Streptococcus pyogenes* and she was administered penicillin (24 mill units / 24h) while intubated and monitored in the ICU until 7<sup>th</sup> postoperative day. She was then, transferred back to the Surgical Ward with no ventilation support, hemodynamically normal with improved blood tests and general condition. The vacuum assisted closure system was helpful with its combined of continuous cleaning of the wound in the formation of granulation tissue.

She was discharged one month later, and she was referred to a Plastic Surgery Centre for reconstruction surgery. The histological examination of the specimen revealed high malignancy B cell lymphoma with the presence of light chain in G positive cells and diversion, a particularly uncommon finding in this type of lymphoma. Trauma cultivation confirmed group A *Streptococcus pyogenes* as the cause of the infection and the necrotizing fasciitis.

## Discussion

Necrotizing fasciitis was first described "in modern time" by a confederate Army surgeon, Josef Jones. In 1871, during the US civil war, he reported 2642 cases



**Figure 1 - Necrotizing fasciitis of the left thigh in a 51 years old woman. Cultures revealed *A streptococcus pyogenes* and the histological examination G(+) cells and diversion in high malignancy B cell lymphoma.**

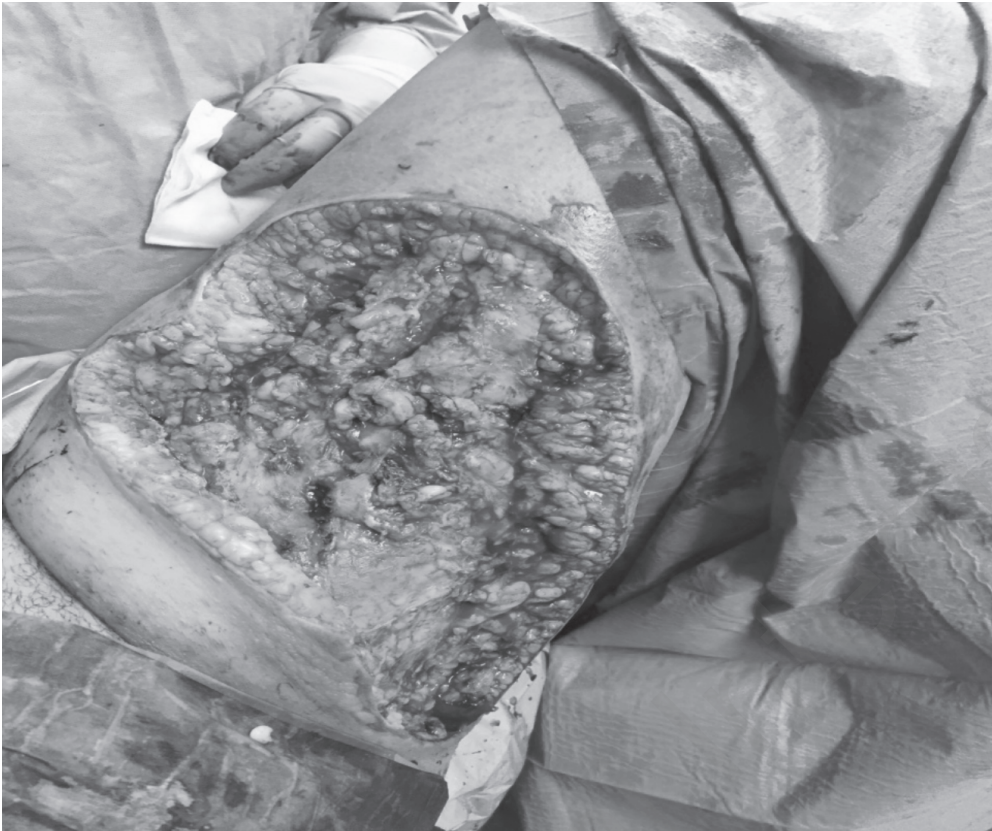


Figure 2 - Wound debridement. Note the significant amount of tissues resected, and the clean skin edges.

of gas gangrene treated in hospital with a mortality rate of 46% (9). In 1824, Meleny reported the first series of this disease from China (Beijing). He called the infection, “hematologic streptococcus gangrene”, because in most cases streptococcus was found in tissue cultures. These cases were described as Meleny’s gangrene, for several decades (10,11).

In 1952 Wilson proposed a more accurate description using the term “necrotizing fasciitis” without assigning a specific bacterium that caused the disease (12).

The most common causes of NF are related to trauma, diabetes, chronic wound infections, obesity, alcoholism, chronic liver disease, immune – suppression (13).

It can be caused by group A streptococcal infection often in combination with staphylococcus Aureus, it can also be polymicrobial including Clostridium, Klebsiella, Pseudomonas, Proteus, bacteroides (14).

It can present anywhere in the body but prevalence is at the lower limb, varying from 32% to 58% (1-3). A retrospective study by Cheng et al showed that upper extremity necrotizing fasciitis has a high mortality rate (about 35%) (15).

The reported mortality in patients with necrotizing fasciitis ranged from 20% to 80% (16, 17). Infection with certain streptococcal stains has been associated with very

poor prognosis. However, McHenry et al. found that monomicrobial infection with streptococcus pyogenes was not associated with an increased mortality. The same study reported that the average time between hospital admission and operation for the non-survivors was 90 hours, thus for survivors it was 25 hours. The early diagnosis and operation was associated with a decrease in mortality rates (17).

The usual presentation is pain in the inflamed area, accompanied with fever and in some cases septic shock. Most patients present with signs of systemic toxicity (tachycardia, tachypnea, and hypotension) and have a high white blood count, together with hypoalbuminemia.

The diagnosis of necrotizing fasciitis is very difficult in early stages, as it appears as mild cellulitis (18). The initial diagnosis depends on history and clinical evidence of necrotizing inflammation, together with signs of systemic toxicity.

Hematologic malignancies can be associated with, or accompanied by, cutaneous manifestations, known as paraneoplastic syndrome. B cell lymphomas may present as primary cutaneous large follicle center-cell lymphomas of the leg. Primary cutaneous large B-cell lymphoma of the leg (PCLBCL) positive for BCL-2 protein is rapidly progressive and has a poorer prognosis and a higher age of presentation (19, 20).



The neoplastic B-cells also express the B-cell associated antigen, CD20. The PCLBCL leg frequently develops extra-cutaneous disease, and the 5-year survival rate is 52% (21).

A study by Rouse et al. indicated that the early recognition and treatment of necrotizing fasciitis is essential. Eleven out of twelve patients included in the study, whose treatment was delayed, died (16).

The early diagnosis and aggressive surgical treatment as well as the initial management is essential for survival. Fluid resuscitation together with electrolytes, when needed, combined with antibiotic therapy (penicillin G and aminoglycoside) is the first line approach. Surgical intervention is necessary and should be performed as soon as possible (1, 4, 15, 17, 22). Surgical debridement necrosectomy and fasciotomy together with excision of all necrotic subcutaneous tissue fascia and skin has to be performed to the point that healthy bleeding tissue is encountered.

## Conclusion

A rare case of primary cutaneous diffuse large B-cell lymphoma (leg type) positive for BCL-2 protein that presents as necrotizing fasciitis is described.

This necrotizing fasciitis case study emphasizes the importance of early diagnosis, urgent treatment and ag-

gressive surgical management and will benefit the management of similar cases in the future.

## Consent

Written informed consent was obtained from the patient for publication of this case report and any accompanying images.

## Competing interests

The Authors declare that they have no competing interests.

## Authors' contributions

KGS and DSI analyzed and interpreted the patient data and were the major contributors to the writing of the manuscript. MEF and GEK participated in the design and coordination; EES, AVD, EKV, ER and MSC helped to draft the manuscript. All authors performed the surgical treatment and the post-surgery observation of the patient. All authors read and approved the final manuscript.

## Abbreviations

ER = EMERGENCY ROOM  
ICU = INTENSIVE CARE UNIT  
NF = NECROTIZING FASCIITIS  
BCL = B CELL LYMPHOMA

## References

1. McInerney NM, Power KT, Hussey AJ. Primary cutaneous diffuse B-cell lymphoma (leg type) presenting as necrotizing fasciitis. *Modern Plastic Surgery*. 2012;2:99-102.
2. Anaya DA, Dellinger EP. Necrotizing Soft-Tissue Infection: Diagnosis and management. *Clinical Infectious Diseases*. 2007;44(5):705-710.
3. Childers BJ, Potyondy LD, Nachreiner R, et al. Necrotizing fasciitis: A fourteen-year retrospective study of 163 consecutive patients. *The American Journal of Surgery*. 2002;68(2):109-116.
4. Misiakos EP, Bagias G, Patapis P, Sotiropoulos D, Kanavidis P, Machairas A. Current concepts in the management of necrotizing fasciitis. *Front Surg*. 2014 Sep 29;1:36.
5. Descamps V, Aitken J, Lee MG. Hippocrates on necrotizing fasciitis. *Lancet*. 1994 Aug 20;344(8921):556.
6. Edlich RF, Cross CL, Dahlstrom JJ, Long WB 3rd. Modern concepts of the diagnosis and treatment of necrotizing fasciitis. *J Emerg Med*. 2010 Aug 39(2):261-5.
7. Rausch J, Foca M. Necrotizing fasciitis in a pediatric patient caused by lancefield group g streptococcus: case report and review of the literature. *Case Rep Med*. 2011.
8. Vayvada H, Demirdover C, Menderes A, Karaca C. Necrotizing fasciitis: diagnosis, treatment and review of the literature. *Ulus Travma Acil Cerrahi Derg*. 2012 Nov. 18(6):507-13.
9. Jones J. *Surgical Memoirs of the war of the rebellion: investigation upon the nature, causes and treatment of hospital gangrene as prevailed in the confederate armies 1861-1865*. New York, NY:US Sanitary Commission;(1871).
10. Meleney FL. Hemolytic streptococcus gangrene. *Arch Surg*.1924;9:317-364.
11. Brewer GE, Meleney FL. Progressive gangrenous infection of the skin and subcutaneous tissues, following operation for acute perforative appendicitis: a study in symbiosis. *Ann Surg*. 1926;84:438-501.
12. Wilson B. Necrotizing fasciitis. *Am Surg*. 1952;18:416-31.
13. Marron CD. Superficial Sepsis, Cutaneous Abscess and Necrotizing Fasciitis. *Emergency Surgery*. Brooks A, Cotton BA., Tai N and Mahoney PF), Blackwell publishing, 2010. pp.115-123.
14. Sarani B, Strong M, Pascual J, Schwab CW. Necrotizing fasciitis: current concept and review of the literature. *J Am Coll Surg*. 2009;208(2):279-288.
15. Cheng NC, Su YM, Tai HC, Tang YB. Factors affecting the mortality of necrotizing fasciitis involving the upper extremities. *Surg Today*. 2008;38(12):1108-13
16. Rouse TM, Malangoni MA, Schulte WJ. Necrotizing fasciitis: a preventable disaster. *Surgery*. 1982 Oct. 92(4):765-70.
17. McHenry CR, Piotrowski JJ, Petrinic D, Malangoni MA. Determinants of mortality for necrotizing soft-tissue infections. *Ann Surg*. 1995 May. 221(5):558-63; discussion 563-5.

18. Urschel JD. Necrotizing soft tissue infections. *Postgraduate Medical Journal*. 1999;75(889):645-649.
  19. Willemze R, Kerl H, Sterry W, et al. EORTC Classification for Primary Cutaneous Lymphomas: A Proposal from the Cutaneous Lymphoma Study Group of the European Organization for Research and Treatment of Cancer. *Blood*. 1997;90(1):354-371.
  20. Geelen FA, Vermeer MH, Meijer CJ, et al. Bcl-2 Protein Expression in Primary Cutaneous Large B-Cell Lymphoma is Site-Related. *Journal of Clinical Oncology*. 1998;16(6):2080-2085.
  21. Grange F, Bekkenk MW, Wechsler J, et al. Prognostic Factors in Primary Cutaneous Large B-Cell Lymphomas: A European Multicenter Study. *Journal of Clinical Oncology*. 2001;19(16):3602-3610.
  22. Bilton BD, Zibari GB, McMillan RW, Aultman DF, Dunn G, McDonald JC. Aggressive surgical management of necrotizing fasciitis serves to decrease mortality: a retrospective study. *American Surgeon*. 1998;64(5):397-401.
-