

The coexistence of primary hyperparathyroidism and thyroid nodules: should the preoperative work-up of the parathyroid and the thyroid diseases be specifically adjusted?

G. SCERRINO¹, M. ATTARD², C. LO PICCOLO¹, A. ATTARD³, G.I. MELFA¹,
C. RASPANTI¹, M. ZARCONI⁴, S. BONVENTRE¹, S. MAZZOLA⁴, G. GULOTTA¹

SUMMARY: The coexistence of primary hyperparathyroidism and thyroid nodules: should the preoperative work-up of the parathyroid and the thyroid diseases be specifically adjusted?

G. SCERRINO, M. ATTARD, C. LO PICCOLO, A. ATTARD, G.I. MELFA,
C. RASPANTI, M. ZARCONI, S. BONVENTRE, S. MAZZOLA,
G. GULOTTA

Introduction and objectives. Primary hyperparathyroidism (PHPT) can be found in concomitance with thyroid disease (TD) in a high frequency of cases. In this context the diagnostic exams for localizing the enlarged parathyroid(s) gland(s) could be less reliable or non-conclusive. Moreover, the thyroid carcinoma seems to be more frequent compared to that isolated thyroid disease and, therefore, carefully investigated. The main goal of the present study is to evaluate which diagnostic tool (US, MIBI) is more reliable for localizing the site of the PTH hypersecretion and to confirm if it is always advantageous a combination of both exams. Besides, we evaluated the incidence of thyroid carcinoma in our series of patients.

Patients and methods. A review of available data of 73 patients who underwent total thyroidectomy + parathyroidectomy from 2003 and 2014 was performed. The preoperative workup included systematically US and MIBI whose results were considered true positive when at least the side (left/right) of the parathyroid affected were concordant with the surgical report, settled as the gold standard, according to the Cox non-nested model. The connection between the diagnostic results of US versus MIBI was calculated with the Cohen K index for evaluating their overlap. The average of the thyroid carcinoma were also calculated.

Results. The difference between respectively US versus surgical report (p value=0.73) and MIBI versus surgical report (p value=0.81) were not significant. The low Cohen K index showed that both US and MIBI are complementary. In 23 patients (32,9%) a thyroid carcinoma was found.

Conclusions. The association of MIBI and neck US is mandatory in the first evaluation of patients undergoing thyroidectomy and parathyroid excision simultaneously. The high prevalence of thyroid carcinoma in this specific context suggests a more aggressive diagnostic and surgical behaviour.

KEY WORDS: Primary hyperparathyroidism - Thyroid disease - MIBI.

Introduction

Primary hyperparathyroidism (PHPT) is the third most common endocrine disorder, after diabetes and thyroid diseases and affects up to 0.1% of the general population (1-6). As a rule, the diagnosis is simple, based on findings of increased serum calcium levels and parathyroid hormone (PTH) value abnormally elevated, or inappropriately near the upper bound (7). Thyroid

nodules are a very common entity instead, affecting nearly 50% of middle-aged people (5). As described in several series, PHPT is diagnosed in coincidence of a thyroid disease in an increasing number of patients (8-10). Approximately, 17-84% of patients suffering from PHPT have a concomitant thyroid disease (TD) (11-14), whereas in 3-5% of patients undergoing thyroidectomy, an enlarged and-or hyperfunctioning parathyroid gland is found, prior to surgery or during surgical neck exploration (15-16). As the treatment of the PHPT requires the complete excision of the parathyroid tissue responsible for the hyperproduction of PTH, the preoperative diagnosis should be conclusive for identifying not only the presence of this endocrine disease, but locating the enlarged gland(s) as well (16-19). In coexistence of both TD and PHPT, the interpretation of the usual diagnostic imaging such as neck ultrasound (US) and 99m-technetium sestaMIBI scan (MIBI) could be doubtful owing to the high rate of false positive and non-

¹ Unit of General and Emergency Surgery, Policlinico "P. Giaccone", Palermo, Italy

² Unit of Endocrinology, "V. Cervello" Hospital, Palermo, Italy

³ Section of General and Thoracic Surgery, Policlinico "P. Giaccone", Palermo, Italy

⁴ Unit of Clinical Epidemiology and Cancer Registry, Policlinico "P. Giaccone", Palermo, Italy

Corresponding author: Gregorio Scerrino, e-mail: gregorio.scerrino@tiscali.it

© Copyright 2016, CIC Edizioni Internazionali, Roma

conclusive findings (20, 21). Moreover, it should be considered that PHPT can coexist with thyroid carcinoma, especially the papillary form (PTC) (22-24). All considered, the presence of both pathologies simultaneously can lead to leave the hypercalcemia, a thyroid cancer or a toxic goiter untreated and can result in a reoperative approach (5). Although a protocol for the evaluation of patients with coexistent TD and PHPT has not get ready yet (12-13, 22), it is likely that the techniques of parathyroid localization should be used in combination and, on the other hand, the TD should not be underestimated.

The present study was undertaken to evaluate two different aspects of this coexistence: first of all, if the association of both US and MIBI, compared with each diagnostic exam separately is useful for improving our diagnostic protocol; moreover, we investigate the real impact of the thyroid carcinoma in this specific context and the relevant rising changes in evaluating thyroid nodules coexisting with PHPT.

Study design

The present institutional retrospective study involved a cohort of patients evaluated preoperatively for both diseases and scheduled for thyroidectomy *and* parathyroidectomy. The main goal were to evaluate which diagnostic tool (US, MIBI) is more reliable for localizing the parathyroid gland responsible for PTH hypersecretion and to confirm if it is always advantageous to combine systematically US and MIBI; secondly, if the intraoperative diagnostic tools (intraoperative PTH dosage, intraoperative scintigraphy) play a role, and in which measure; finally, the complication's rate of thyroidectomy and parathyroidectomy simultaneously performed.

We performed a review of available data of patients who underwent total thyroidectomy + parathyroidectomy from 2003 and 2014 including all patients with a diagnosis of PHPT *and* any thyroid disease (multinodular goiter [MNG], multinodular toxic goiter [MNTG], Plummer disease [PD], Grave's disease [GD], thyroid carcinoma, [TC]) with or without signs of auto-immunity, for whom medical records were completely available, from the preoperative assessment to the follow-up (≥ 6 months).

The patients that have previously undergone subtotal thyroidectomy, thyroid lobo-isthmusectomy, neck re-explorations for recurrent/persistent PHPT, the patients operated on for lymph node dissection (central and/or lateral) simultaneously or subsequently the thyroidectomy (25-26) and the patients suffering from secondary hyperparathyroidism were excluded from the study. The patients with a family history of multiple endocrine neoplasia or familial HPT, as well as the patients with incomplete records or lack of laboratory tests respect to

PHPT, US for thyroid/parathyroid disease or MIBI were also excluded. Finally, we did not include in the cohort the patients where the diagnosis of PHPT had been made during surgical exploration. Follow-up was carried out by outpatient consultation.

The ethical standards of Declaration of Helsinki (1964) and its later amendments were strictly observed.

Altogether 73 patients (59 women, 14 men) were enrolled in the present study. The mean age was 60 years (range: 26-81). The data were obtained from medical records available.

Patients and methods

Data collected included demographics (sex, age); serum calcium levels (mg/dl; normal range: 8.4-10); preoperative PTH value (pg/ml; normal range: 15-65); exams carried out for identifying the TD (US, fine-needle aspiration biopsy [FNAB]) and its exact diagnosis (MNG, MNTG, PD, GD, TC); results of preoperative parathyroid US and MIBI (concerning the localization of the enlarged gland); surgical report (localization of the parathyroid[s] responsible for the PHPT) and its accordance with preoperative US and MIBI; results of intraoperative PTH dosage; results of intraoperative scintigraphy (if made); final histologic findings (thyroid/parathyroid); complications (transient and definitive hypoparathyroidism; transient and definitive vocal fold palsy); follow-up (recurrence of hyperparathyroidism).

The preoperative workup included systematically US (performed a linear 7.5MHz probe) with the aim to identify enlarged parathyroid gland(s) and morpho-volumetric features of the thyroid (size, nodules, color Doppler pattern). In particular, the nodules were examined looking for its size, shape, echoic structure (hyper - normo - hypoechoic), intralesional calcifications, halo-sign, intralesional vascular signal. Any suspicious sign for carcinoma led us to perform a FNAB. Both US and tissue sampling for FNAB were performed by a surgeon (GS) experienced in neck US.

The MIBI technique was performed using the single tracer, double-phase protocol.

A dose of 370-450 MBq of ^{99m}Tc -MIBI was injected intravenously 15 minutes (early scan) and two hours (late scan) before the planar acquisition of the images of the head and mediastinum. The late acquisition showed the wash out of the radioactive tracer from the thyroid gland and the persistence in the parathyroid one.

The surgical exploration were always performed with a conventional "open" thyroidectomy (skin incision length: 3.5 - 5 cm). A wide, bilateral parathyroid exploration, needed to remove the enlarged gland(s) was always performed before the thyroid resection and, if needed, after its removal as well.

The i.o. PTH was then performed collecting blood samples: at the preoperative time; 5 minutes after excision; 20 minutes after excision. A PTH drop $\geq 50\%$ and at all events under the threshold limiting value (65 pg/ml) was considered successful. The three blood samples for each patient were carried by a resident carrier at the Clinical Analysis Institutional Service, where the PTH dosage was performed.

The intraoperative scintigraphy was performed only in 8 cases by means of the *Sentinella 102*[®] (GEM Imaging S.A., Valencia, Spain), a transportable high-definition Gamma Camera integrated to a specific software. An electromechanical arm allows a precise positioning of the gamma camera over the operative field. This device allows an accurate spatial mapping of the radioactivity of the tissues, producing images similar to a conventional scintigraphy and it is able to localize small radioactive areas.

Concerning the value of the diagnostic exams for parathyroid disease, the results of US and MIBI were considered true positive when at least the side (left/right) of the parathyroid affected were concordant with the surgical report, settled as the gold standard.

Statistical analysis

The Cox non-nested model was used to evaluate the statistical association between US or MIBI and surgical report that was considered the gold standard; a p value < 0.05 indicated the statistical significance. The Fisher's exact test was used to evaluate the connection between the diagnostic results of US *versus* MIBI; the Cohen K-index was used to evaluate the corresponding degree of its real concordance (Table 1).

We used the logistic regression between the variation rate of i.o. PTH and the dummy variable (recurrence/no recurrence). This relation was calculated with the regression coefficient.

The results of US and MIBI in identifying the side of the enlarged parathyroid gland and the complication's rate were expressed as average.

The data were collected in a dedicated database (Microsoft Excel[®], Microsoft Corporation, Redmond, WA, USA) and analyzed by a professional statistician.

The IDE RStudio (version: 0.98.945), with the

software R, version 3.1.0. (2014.04.10) was used for the statistical analysis.

Results

Regarding the parathyroid disease, in 26 cases (35.6%) US proved to be non-diagnostic; in 5 cases, it was discordant as regards the side, moreover in 2 patients a second enlarged contralateral gland was not identified. Altogether, US indicated an incorrect localization in 9.6%. In 40 patients (54.8%) US identified the exact side of the pathologic parathyroid, of which 32 underwent an exact diagnosis also concerning the level.

Concerning the MIBI, the exam was non-diagnostic in 9 cases (12.3%), discordant concerning the side in 13, and in 4 cases there were a second pathologic contralateral gland (total amount of incorrect localization: 17 = 23.3%). The identifications with MIBI were correct in 50 cases (68.5%), of which 11 only concerning the side but not the level. The Cox non-nested model showed a non-significant difference between respectively US *versus* surgical report (p value=0.73) and MIBI *versus* surgical report (p value=0.81). These results mean that both US and MIBI, since the p value resulted > 0.05 , are effective in identifying at least the side (left/right) of the hyperfunctioning parathyroid gland. The degree of real concordance between US and MIBI, calculated with the Cohen K index was respectively 0.825 (excellent) and 0.598 (moderate degree of relationship).

In this point of view the US seems more performant compared to the MIBI: nevertheless, we also calculated the significance of the relationship between non-diagnostic and diagnostic results of US and MIBI (p=0.007) and the degree of concordance between non-diagnostic results of US and MIBI: the value obtained (K = 0.265) should be considered low. These results allow to say that both exams have a narrow overlap, so they are complementary, at least in this specific context.

These results are summarized in Table 2.

The intraoperative scintigraphy, performed only 8 times, was totally concordant with the operative exploration.

The results concerning the i.o. PTH are schematized in the table 3: it shows a high concentration of successful procedures (0.0 = no recurrences) if the difference between the highest and the lowest value of the test was around 90% with a regression coefficient = 0.08. Unfortunately, this relation was not significant (p=0.09).

Concerning the TD, we observed 24 thyroid carcinomas (23 papillary, 1 follicular; 32.9%), and, in the context of the benign TD, 6 (8.2%) toxic goiters.

The complications observed were: 7 definitive hypoparathyroidism (9.6%) and 3 transient monolateral vocal fold palsy (4.1%). 7 PHPT recurrent or persistent

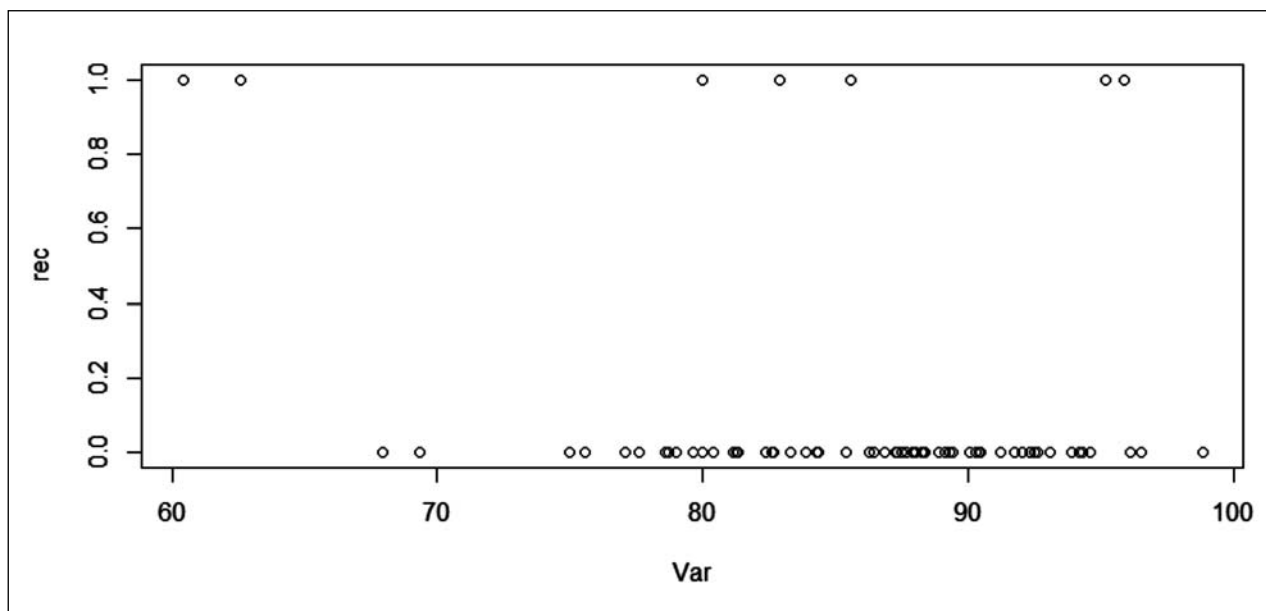
TABLE 1 - K VALUE INTERPRETATION.

| K value | Degree of relationship |
|-------------|------------------------|
| >0.01 | Null |
| 0.01 - 0.20 | Very low |
| 0.21 - 0.40 | Low |
| 0.41 - 0.60 | Moderate |
| 0.61 - 0.80 | Considerable |
| 0.81 - 1.00 | Excellent |

TABLE 2 - RESULTS.

| | | | |
|--|---------|-------|-------|
| US as regards PHPT | | | |
| non-diagnostic | | 26 | 35.6% |
| incorrect diagnosis | | 7 | 9.6% |
| discordant as regards the side | | 5 | |
| incomplete because of a second gland was forgotten | | 2 | |
| correct for side | | 40 | 54.8% |
| correct also for level | | 32 | |
| Cox non-nested model versus surgical report | p value | 0.73 | n.s. |
| Cohen K index | | 0.825 | |
| MIBI as regards PHPT | | | |
| non-diagnostic | | 9 | 12.3% |
| incorrect diagnosis | | 17 | 23.3% |
| discordant as regards the side | | 13 | |
| incomplete because of a second gland was forgotten | | 4 | |
| correct for side | | 50 | 68.5% |
| correct also for level | | 39 | |
| Cox non-nested model versus surgical report | p value | 0.81 | n.s. |
| Cohen K index | | 0.598 | |
| US/MIBI | | | |
| diagnostic/non-diagnostic results (relationship) | p value | 0.007 | <0.05 |
| degree of concordance | | 0.265 | |
| Thyroid carcinoma | | 24 | 32.9% |
| Complications | | | |
| definitive hypoparathyroidism | | 7 | 9.6% |
| vocal fold palsy (monolateral, transient) | | 3 | 4.1% |
| recurrent/persistent PHPT | | 7 | 9.6% |
| compressive hematoma | | none | |

TABLE 3 - LOGISTIC REGRESSION OF I.O. PTH VALUES.



rec= recurrence (0.0 = no recurrence; 1.0 = recurrence);
 Var = variation % of i.o. PTH value between the highest and the lowest result.

were described (9,6%). No compressive hematoma was described in this series.

Discussion

The coexistence of PHPT and TD is a well-known nosological entity (5). The prevalence of PHPT in patients suffering from a TD is 3 times the healthy subjects (28) and, on the other hand, the PHPT is very frequently associated with a TD (5). The only available guidelines are dedicated isolately to PHPT *or* TD, but not to the coincidental entities. Anyway, this association seems to be found increasingly. One of the pathogenic factors invoked is the exposition to ionizing radiations: in irradiated patients, if a PHPT was present, a coexisting thyroid nodule was found in 95% of cases with a high incidence of thyroid carcinoma (30). In non-irradiated patients, both PTH and high serum calcium levels have been implicated in the pathogenesis of the non-medullary thyroid carcinoma (31-33). Anyway, this cancer should be carefully investigated because of its high frequency (29, 30). In our series, a high prevalence of papillary thyroid carcinoma was found. Generally, the diagnosis was a consequence of a fine-needle aspiration biopsy in which a "follicular proliferation" was frequently evidenced. In this occurrence the total thyroidectomy is generally preferred (34, 35). According to our experience, an accurate interpretation of thyroid ultrasonographic findings and, if needed, a bioptic approach to suspicious nodules can help to obtain the diagnosis of malignancy.

The PHPT should be carefully investigated with the aim to highlight this endocrine disorder and to spot the enlarged gland(s) responsible. The low sensitivity and specificity of preoperative parathyroid localization techniques in coexisting thyroid disease is well known (36, 38): the MIBI false-positives could originate by accumulation of the radioactive tracer in thyroid nodules or nodular Hashimoto's thyroiditis, whereas the false negative ones seem to be the result of the low weight of the enlarged gland(s), superior adenomas or low rate of oxyphil cells (38, 39).

During US exploration, thyroid nodules, especially in multinodular goiters, can be mistaken for parathyroid glands; moreover, they can cause a posterior displacement of adenomas and change in ultrasound tissue penetration; posterior and/or exophytic thyroid nodules and enlarged lymph nodes can look like enlarged parathyroid glands (38, 39).

Finally, both US and MIBI have a poor diagnostic efficacy in the presence of intrathyroid parathyroid adenomas (40). In this specific case, the US-guided fine-needle aspiration biopsy could help to distinguish a thyroid nodule from a parathyroid adenoma, although the re-

liability of the cytology to identify the parathyroid cells is still controversial (41-43). Concerning this, the FNA-PTH assay seems to be more accurate (20, 42).

Given these assumptions, our study reported the following findings: 1) PHPT and TD are frequently associated; 2) the prevalence of thyroid cancer in this context (>32%) is very considerable; 3) the synergism of US and MIBI in improving the diagnostic efficacy seems at least advantageous, as assumed in different studies (14, 17).

Moreover, the correlation between i.o.PTH drop and cure rate was evaluated. Although a trend in favor of the systematic use of this test was found, no statistical significance was obtained in the sample examined. Anyway the i.o. PTH, in spite of the cost increase (44), if used with the aim to assure the completeness of parathyroid excision proved to be an efficacious tool for improving the success rate of surgery, likewise the treatment of the solitary PHPT, as commonly affirmed (45).

Even though we used the intraoperative minigamma-camera only 8 times, it showed to be efficacious in localizing the enlarged gland and in confirming the completeness of the surgical procedure, as previously affirmed (46). Nevertheless, a larger experience is needed to confirm these results.

As an overview of diagnostic implications, we esteem that, if both thyroidectomy and parathyroid excision are indicated simultaneously, the diagnostic tools available should be put into the field according to the experience and the skills of every working team, considering the poor diagnostic efficacy of a separate exam.

The question is not to perform a minimally invasive focused approach, but for avoiding a prolonged exploration with a doubtful outcome in terms of persistence/recurrence rate. In fact, in a context in which a wide exploration is mandatory, the focused surgical techniques are not feasible and only the minimally invasive video-assisted thyroidectomy and parathyroidectomy are indicated (moreover only in selected cases) because they allow a four-gland exploration (47, 48). The complications mainly consists in transient vocal fold palsy, and in the need of long-term calcium and vitamin D supplementation: the first one could be considered acceptable because its incidence do not differ from the data concerning the thyroidectomy alone reported in literature (49), the second one, with an incidence of less than 10%, should be compared to the large number of detected thyroid carcinomas. These results indicate that simultaneous surgical treatment of thyroid and parathyroid diseases is affordable compared to the two procedures performed separately, given the increase in complication's rate in case of neck re-exploration (16). Finally, the prevalence of thyroid carcinoma that we found in our series suggest to carefully evaluate any thyroid disease found during a work-up for PHPT.

When a contemporaneous thyroid surgery is indicated, the total thyroidectomy subject to the informed consent is the procedure of choice, considering that it is well tolerated and efficacious for a wide range of situations (50-53).

Conclusions

The suspicion of coexisting TD and PHPT should be kept prior to performing a thyroidectomy or a parathyroid excision alone. Given the high incidence of coexistent TD and PHPT and the relevant prevalence of non-medullary thyroid carcinoma, the thyroid nodules

should be carefully evaluated during the preoperative work-up of a PHPT, with the aim to identify a potential malignancy and, conversely, the PHPT should be always investigated in view of a thyroidectomy. According to the data emerging from our experience, it is allowed to state that both MIBI and neck US should be associated in the first evaluation of patients undergoing thyroidectomy and parathyroid excision simultaneously and, if available, each additional intraoperative diagnostic tool can improve the opportunity of localizing an enlarged parathyroid gland. Finally, we can affirm that the complication rate, that is similar to those of the thyroidectomy alone, should be compared with the morbidity of the redo neck surgery.

References

- Adami S, Marcocci C, Gatti D. Epidemiology of primary hyperparathyroidism in Europe. *J Bone Miner Res.* 2002;17 (suppl. 2):N18-N23.
- Wermers RA, Chosla S, Atkinson EJ, Achenbach SJ, Oberg AL, Grant CS, Melton LG III: Primary hyperparathyroidism in Rochester, Minnesota, 1993-2001: An update on the changing epidemiology of the disease. *J Bone Miner Res.* 2006;21:171-77.
- Eufrazino C, Veras A, Bandeira F. Epidemiology of primary hyperparathyroidism and its non-classical manifestations in the City of Recife, Brazil. *Clin Med Insights Endocrinol Diabetes.* 2013;6:69-74.
- Silverberg SJ, Bilezikian JP. Asymptomatic primary hyperparathyroidism: a medical perspective. *Surg Clin North Am.* 2004;84:787-801.
- Morita SY, Somervell H, Umbricht CB, Dackiw APB, Zeiger MA. Evaluation for concomitant thyroid nodules and primary hyperparathyroidism in patients undergoing parathyroidectomy or thyroidectomy. *Surgery.* 2008;144(6): 862-67.
- Scerrino G, Cocorullo G, Paladino NC, Salamone G, Gulotta G. Quantification of the risk of relapses after thyroid lobectomy for benign thyroid nodules. *Ann Ital Chir.* 2005;76(4):321-8; discussion 328-29.
- Bilezikian JP, Rubin M, Silverberg SJ. Hyperparathyroidism: diagnosis, evaluation, and treatment. *Cur Opin Endocrinol Diab.* 2004;11:345-52
- Regal M, Pàramo C, Luna Cano R, Pérez Méndez LF, Sierra JM, Rodríguez I, García-Mayor RV. Coexistence of primary hyperparathyroidism and thyroid disease. *J Endocrinol Invest.* 1999;22(3):191-97.
- Sidhu S, Campbell P. Thyroid pathology associated with primary hyperparathyroidism. *Aust N Z J Surg.* 2000;70:285-87.
- Sianesi M, Del Rio P, Arcuri MF, Iapichino G, Robuschi G. Hyperparathyroidism associated with thyroid pathology. *Am J Surg.* 2003;185: 58-60.
- Kairys JC, Daskalakis C, Weigel RJ. Surgeon-performed ultrasound for preoperative localization of abnormal parathyroid glands in patients with primary hyperparathyroidism. *World J Surg.* 2006;30:1658-63.
- Heizmann O, Viehl CT, Schmid R, Muller-Brand J, Muller B, Oertli D. Impact of concomitant thyroid pathology on preoperative workup for primary hyperparathyroidism. *Eur J Med Res.* 2009;14:37-41.
- Adler JT, Chen H, Schaefer S, Sippel RS. Does routine use of ultrasound result in additional thyroid procedures in patients with primary hyperparathyroidism? *J Am Coll Surg.* 2010;211:536-39.
- Spanheimer PM, Weigel RJ. Management of patients with primary hyperparathyroidism and concurrent thyroid disease: an evolving field. *Ann Surg Oncol.* 2012;19:1428-29.
- Helme S, Lulsegg A, Sinha P. Incidental parathyroid disease during thyroid surgery: should we remove them? *ISRN Surgery.* 2011; doi: 10.5402/2011/962186. Epub 2011.
- Murray S, Sippel RS, Chen H. The incidence of concomitant hyperparathyroidism in patients with thyroid disease requiring surgery. *J Surg Res.* 2012;178(1): 264-67.
- Del Rio P, Arcuri MF, Bezer L, Cataldo S, Robuschi G, Sianesi M. Association with primary hyperparathyroidism and thyroid disease: role of preoperative P.T.H. *Ann Ital Chir.* 2009;80(6):435-38.
- Al-Fehaily M, Clark OH. Persistent or recurrent primary hyperparathyroidism. *Ann Ital Chir.* 2003;74(4):423-34.
- Lumachi F, Zucchetta P, Tregnaghi A, Marzola MC, Cecchin D, Marchesi P, Bui F, Iacobone M. Noninvasive parathyroid imaging in primary hyperparathyroidism. *Ann Ital Chir.* 2003;74(4):385-88.
- Boi F, Lombardo C, Cocco MC, Piga M, Serra A, Lai ML, Calò PG, Nicolosi A, Mariotti S. Thyroid diseases cause mismatch between MIBI scan and neck ultrasound in the diagnosis of hyperfunctioning parathyroids: usefulness of FNA-PTH assay. *Eur J Endocrinol.* 2013;168: 49-58.
- Erbil Y, Barbaros U, Yanik BT, Salmasioglu A, Tunaci M, Adalet I, Bozboru A, Ozarmagan S. Impact of gland morphology and concomitant thyroid nodules on preoperative localization of parathyroid adenomas. *Laryngoscope.* 2006;116:580-85.
- Leitha T, Staudenherz A. Concomitant hyperparathyroidism and nonmedullary thyroid cancer, with a review of the literature. *Clin Nucl Med.* 2003;28(2):113-17.
- Montenegro FLM, Smith RB, Castro IV, Tavares MR, Cordeiro AC, Ferraz AR. Association of papillary thyroid carcinoma and primary hyperparathyroidism. *Rev Col Bras Cir.* 2005;32(3):115-19.

24. Lee YS, Nam KH, Chung WY, Chang HS, Park CS. Coexistence of parathyroid adenoma and papillary thyroid carcinoma. *J Korean Surg Soc*. 2011;81:316-20.
25. Scerrino G, Attard A, Melfa GI, Raspanti C, Di Giovanni S, Attard M, Inviati A, Mazzola S, Modica G, Gulotta G, Bonventre S. Role of Prophylactic Central Neck Dissection in CN0-Papillary Thyroid Carcinoma: Results from a High-Prevalence Area. *Minerva Chir*. 2015, Jun, 05 [Epub. ahead of print].
26. Scerrino G, Di Giovanni S, Salamone G, Melfa GI, Inviati A, Raspanti C, Gulotta G. Surgical complication in prophylactic central neck dissection: preliminary findings from a retrospective cohort study. *Min Chir*. 2014;69 (suppl. 2):131-34.
27. Wagner B, Bergic-Karup S, Raber W, Schneider B, Waldhausl W, Vierhapper H. Prevalence of primary hyperparathyroidism in 13387 patients with thyroid diseases, newly diagnosed by screening of serum calcium. *Exp Clin Endocrinol Diabetes*. 1999;107:457-61.
28. Wang TS, Sanziana AR, Cox H, Air M, Sosa JA. The management of thyroid nodules in patients with primary hyperparathyroidism. *J Surg Res*. 2009;154:317-23.
29. Wilson SD, Doffek KM, Wang TS, Krzywda EA, Evans DB, Yen TWF. Primary hyperparathyroidism with a history of head and neck irradiation: the consequences of associated thyroid tumors. *Surgery*. 2011;150(4):869-76.
30. McCarty MF. Parathyroid hormone may be a cancer promoter-an explanation for the decrease in cancer risk associated with ultraviolet light, calcium and vitamin-D. *Med. Hypotheses*. 2000;54:475-82.
31. Lee YS, Nam KH, Chung WY, Chang HS, Park CS. Coexistence of parathyroid adenoma and papillary thyroid carcinoma. *J Korean Surg Soc*. 2011;81:316-20.
32. Lin SY, Lin WM, Lin CL, Yang TY, Sun FC, Wang YH, Kao CH. The relationship between secondary hyperparathyroidism and thyroid cancer in end stage renal disease: a population-based cohort study. *Eur J Intern Med*. 2014;25:276-80.
33. Conzo G, Calò PG, Gambardella C, Tartaglia E, Mauriello C, Della Pietra C, Medas F, Santa Cruz R, Podda F, Santini L, Troncione G. Controversies in the surgical management of thyroid follicular neoplasms. Retrospective analysis of 721 patients. *Int J Surg*. 2014;12 (Suppl. 1):s29-34.
34. Conzo G, Avenia N, Bellastella G, Candela G, De Bellis A, Esposito K, Pasquali D, Polistena A, Santini L, Sinisi AA. The role of surgery in the current management of differentiated thyroid cancer. *Endocrine*. 2014;47:380-88.
35. Lombardi CP, Bellantone R, De Crea C, Paladino NC, Fadda C, Salvatori M, Raffaelli M. Papillary thyroid microcarcinoma: extrathyroidal extension, lymph node metastases and risk factors for recurrence in a high prevalence of goiter area. *World J Surg*. 2010;34(6):1214-21.
36. Krausz Y, Lebensart PD, Klein M, Weininger J, Blachar A, Chislin R, Shiloni E. Preoperative localization of parathyroid adenoma in patients with concomitant thyroid nodular disease. *World J Surg*. 2000;24:1573-78.
37. Gómez-Ramírez J, Sancho-Insenser JJ, Pereira JA, Jimeno J, Munné A, Sitges-Serra A. Impact of thyroid nodular disease on 99Tc-Sestamibi scintigraphy in patients with primary hyperparathyroidism. *Langenbecks Arch Surg*. 2010;395:929-33.
38. Kwon JO, Kim EK, Lee HS, Moon HS, Kwak JY. Neck ultrasonography as preoperative localization of primary hyperparathyroidism with an additional role of detecting thyroid malignancy. *Eur J Radiol*. 2013;82:e17-e21.
39. Barbados U, Erbil Y, Salmashoglu A, Issever H., Aral F, Tunaci M, Özarmagan S. The characteristics of concomitant thyroid nodules cause false-positive ultrasonography results in primary hyperparathyroidism. *Amer J Otolaryngol-Head Neck Med Surg*. 2009;30:239-43.
40. Ros S, Sitges-Serra A, Pereira JA, Jimeno J, Prieto R, Sancho JJ, Pérez-Ruiz L. Intrathyroid parathyroid adenoma: right and lower. *Cir Esp*. 2008;84(4):196-200.
41. Kwak JY, Kim EK, Moon HJ, Kim MJ, Ahn SS, Son EJ, Sohn YM. Parathyroid incidentalomas detected on routine ultrasound-directed fine-needle aspiration biopsy in patients referred for thyroid nodules and the role of parathyroid hormone analysis in the samples. *Thyroid*. 2009;19:743-48.
42. Kim HS, Choi BH, Park JR, Hahm JR, Jung JH, Kim SK, Kim S, Kim KY, Chung SI, Jung TS. Delayed surgery for parathyroid adenoma misdiagnosed as a thyroid nodule and treated with radiofrequency ablation. *Endocrinol Metab*. 2013;28:231-35.
43. Lieu D. Cytopathologist-performed ultrasound-guided fine-needle aspiration of parathyroid lesions. *Diagn Cytopathol*. 2010;38:327-32.
44. Conzo G, Perna A, Avenia N, De Santo RM, Della Pietra C, Palazzo A, Sinisi AA, Stanzione F, Santini L. Evaluation of the "putative" role of intraoperative intact parathyroid hormone assay during parathyroidectomy for secondary hyperparathyroidism. A retrospective study on 35 consecutive patients. *Endocrine*. 2012;42:606-11.
45. Cho E, Chang JM, Yoon SY, Lee GT, Ku YH, Kim HI, Lee MC, Lee GH, Kim MJ. Preoperative localization and intraoperative parathyroid hormone assay in Korean patients with primary hyperparathyroidism. *Endocrinol Metab*. 2014;29:464-69.
46. Scerrino G, Castorina S, Melfa GI, Lo Piccolo C, Raspanti C, Richiusa P, Costa RP, Gulotta G. The intraoperative use of the minigamma-camera (MGC) in the surgical treatment of primary hyperparathyroidism: technical report and immediate results from the initial experience. *Ann Ital Chir*. 2015;86(3):212-8.
47. Scerrino G, Paladino NC, Di Paola V, Morfino G, Inviati A, Amodio E, Gulotta G, Bonventre S. Minimally invasive video-assisted thyroidectomy: four-year experience of a single team in a General Surgery Unit. *Min Chir*. 2013;68:307-14.
48. De Crea C, Raffaelli M, Traini E, Giustozzi E, Oragano L, Bellantone R, Lombardi CP. Is there a role for video-assisted parathyroidectomy in regions with high prevalence of goitre? *Acta Otorhinolaryngol Ital*. 2013;33:388-92.
49. Riss P, Kammer M, Selberherr A, Scheuba C, Niederle B. Morbidity associated with concomitant thyroid surgery in patients with primary hyperparathyroidism. *Ann Surg Oncol*. 2014; DOI 10.1245/s 10434-014-4283-4.
50. Scerrino G, Salamone G, Farulla MA, Romano G, Salamone S, Pompei G, Buscemi G.: Non-toxic multinodular goitre: which surgery? *Ann Ital Chir*. 2001;72(6):647-51; discussion 652. Article in Italian.
51. Scerrino G, Paladino NC, Cocorullo G, Salamone G, Scarpinata R, Gulotta G. Informed consent in thyroid and parathyroid surgery. *Ann Ital Chir*. 2005;76(3):287-90. Article in Italian.
52. Scerrino G, Cocorullo G, Paladino NC, Salamone G, Gulotta G. Quantification of the risk of relapses after thyroid lobectomy for benign thyroid nodules. *Ann Ital Chir*. 2005;76(4):321-8; discussion: 328-9. Article in Italian.
53. Scerrino G, Morfino G, Paladino NC, Di Paola V, Amodio E, Gulotta G, Bonventre S. Does thyroid surgery for Graves' disease improve health-related quality of life? *Surg Today*. 2013;43(12):1398-405.