

Intraoperative identification of the facial nerve by needle electromyography stimulation with a burr

N.N. KHAMGUSHKEEVA, I.A. ANIKIN, A.A. KORNEYENKOV

SUMMARY: Intraoperative identification of the facial nerve by needle electromyography stimulation with a burr.

N.N. KHAMGUSHKEEVA, I.A. ANIKIN, A.A. KORNEYENKOV

The purpose of this research is to improve the safety of surgery for patients with a pathology of the middle and inner ear by preventing damage to the facial nerve by conducting intraoperative monitoring of the facial nerve by needle electromyography with continuous stimulation with a burr.

Patients and Methods. The clinical part of the prospective study was carried out on 48 patients that were diagnosed with suppurative otitis media. After the surgery with intraoperative monitoring, the facial nerve with an intact bone wall was stimulated electrically in the

potentially dangerous places of damage. Minimum (threshold) stimulation (mA) of the facial nerve with a threshold event of 100 μ V was used to register EMG events. The anatomical part of the study was carried out on 30 unformalinized cadaver temporal bones from adult bodies. The statistical analysis of obtained data was carried out with parametric methods (Student's t-test), non-parametric correlation (Spearman's method) and regression analysis.

Results. It was found that 1 mA of threshold amperage corresponded to 0.8 mm thickness of the bone wall of the facial canal. Values of transosseous threshold stimulation in potentially dangerous sections of the injury to the facial nerve were obtained.

Conclusion. These data lower the risk of paresis (paralysis) of the facial muscles during otologic surgery.

KEY WORDS: Intraoperative - Electromyography - Temporal - Temporal bone - Facial nerve - Nervous system.

Introduction

Despite the existing possibilities of using modern surgical equipment and modern diagnostic techniques, there is still a risk of damaging the facial nerve during otological surgery (1, 2).

This is caused by the anatomic proximity of the facial nerve to the structures of the middle and inner ear (3-5). The facial nerve becomes more vulnerable to injury during repeated (sanifying) surgery on the middle ear, with the presence of dehiscence in the Fallopian canal, during the removal of masses in the middle ear (2,6), in cases of malformation of the middle or inner ear (7, 8).

Many scientific works study the anatomy of the facial nerve (3-5). Most of them provide a general description of the microtopographic characteristics of the facial canal and, at the same time, lack information on the thickness of its bone walls.

Intraoperative damage causes paresis (paralysis) of the facial muscles, which leads to a degradation of the patients' quality of life. According to literary sources, during original surgery, the risk of dysfunction of the facial nerve is 0.6-3.7% of cases (9, 10). During repeated invasive surgery, the risk rises up to 4-10% of cases (1, 11, 12).

The appearance of intraoperative facial nerve monitoring allowed identifying the nerve throughout the entire surgery (13-15), since this method of studying the neuromuscular system registers fluctuation of the electric potential of muscles in response to nerve stimulation.

Despite considerable success in the development of machines for intraoperative monitoring of the facial nerve, the most important restriction remained, which was related to the fact that the system could not warn surgeons if they were operating near the facial nerve, whi-

Saint-Petersburg Research Institute of Ear, Throat, Nose and Speech,
Saint Petersburg, Russia

Corresponding Author: Nataliia Nikolaevna Khamgushkeeva,
e-mail: nataliyalor@gmail.com

© Copyright 2016, CIC Edizioni Internazionali, Roma

le EMG-responses could only be found when the damage to the facial nerve was already done. The first attempt of using stimulating cutters was made by H. Silverstein in 1990. He used a pneumatic burr with an adapter for continuous stimulation, while the response was registered by strain gauge sensors in the form of a pin, located at the corner of the patient's mouth (16, 17).

Nowadays, there are state-of-the-art stimulating burrs. D. Bernardeschi and his team studied patients with acoustic nerve neuroma with the Nerve Integrity Monitor (Nim-3.0) system, which provides for continuous facial nerve stimulation with a burr (StimBurGard). In their paper, they recommended using 1 mA to drill safely near the facial nerve through translabyrinthine approach (18).

Modern literature does not provide information regarding the study of electric stimulation of the facial nerve with a burr during otological surgery, which opens new possibilities for ear microsurgery. According to studies, computed tomography of the temporal bone and surgical macroscopic assessment of the facial nerve are insufficient to verify the integrity of the Fallopian canal (15, 19), which confirms the value of using intraoperative facial nerve monitoring during middle and inner ear surgery.

Thus, the stimulation of the facial nerve with a burr during middle and inner ear microsurgery dictates new demands to the technique of conducting intraoperative facial nerve monitoring.

The purpose of the paper is to improve the safety of surgical treatment of patients with a pathology of the middle or inner ear by preventing damage to the facial nerve by using intraoperative facial nerve monitoring by intramuscular electromyography with continuous stimulation with a burr.

Patients and methods

Forty-eight patients with chronic suppurative otitis media were examined and operated with the use of intramuscular electromyography at the Saint Petersburg Research Institute of Ear, Throat, Nose and Speech of the Ministry of Health of Russia from November 2011 till December 2014.

Intraoperative facial nerve monitoring was conducted by intramuscular electromyography. Bipolar needle electrodes were used to register muscular impulses from facial muscles. Electrodes were inserted subcutaneously in the m. frontalis, m. mentalis, m. orbicularis oculi, m. orbicularis oris zone, and fixed with adhesive tape. The grounding electrode was set in the area of the sternum. The anode was inserted 5 cm from the grounding electrode. Facial nerve stimulation was performed with a burr (Figure 1).

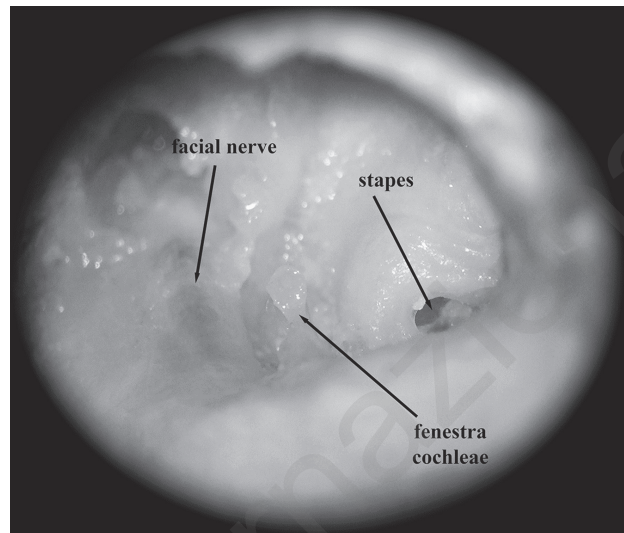


Fig. 1 - Cadaver right temporal bone. The catheter that administers the contrast agent shows through the upper bone wall of the tympanic part of the facial nerve.

An electric current was supplied to the cutters with the STIM head that was fixed on the burr. The STIM head was connected to the EMG-monitor by connection leads between the electric drive device of the burr (IPS system) and the interface block of the EMG-monitor. Electric current was supplied to the cutters continuously throughout the operation of the burr in accordance with the frequency set in the monitor settings.

The parameters during the setting of electric stimulation were as follows: pulse duration – 0.1 ms, stimulus frequency – 7 Hz, event threshold – 100 microvolt (μV).

After the radical surgery, electric stimulation with a burr was carried out in potentially dangerous places of facial nerve damage: the oval window niche, the tympanic sinus, the pr. pyramidalis, the posterior semicircular canal, and the stylomastoid foramen, in order to determine the threshold amperage (mA). The threshold amperage was determined as the first magnitude of amperage, which, when being applied to the nerve, causes minimum EMG activity (20) in at least one of the four registering canals. With minimum amperage (threshold), a depolarization of a part of nerve fibers occurs, while the response amplitude that appears during threshold stimulation is lower, compared to the maximum (suprathreshold) amplitude, and safer.

The anatomic part of the work was conducted on 30 unformalized cadaver temporal bones in order to study the thickness of the Fallopian canal bone wall. The material for the study had no destructive changes and was a homogenous research object.

Measurements were carried out with a probe, a micromillimeter ruler, a digital caliper for internal and ex-

ternal measurements, and a CT scan of the temporal bones with contrast enhancement of the facial nerve.

An extensive mastoidectomy with the exposure of the sigmoid sinus and the dura mater of the mesocranial fossa was conducted to study the facial canal. The malleus and incus were removed to access the front segment of the tympanic part of the facial nerve. The facial canal was skeletonized from the geniculate ganglion to the stylomastoid foramen. A flexible metal conductor with a diameter of 0.6 mm was inserted in the stylomastoid foramen up to the pr. pyramidalis; then a catheter with a diameter of 0.8 mm was installed along the conductor up to the geniculate ganglion (Figure 1). The contrast agent was administered through the canals. The morphology of the tympanic part and the mastoid process of the facial nerve was carried out by a CT scan of the temporal bones with a 0.6 mm scanning pitch. Data obtained from CT sections were studied in Syngo FastView.

The Fallopian canal was studied with a digital caliper and a probe in the following places: the oval window niche, the pr. pyramidalis, the tympanic sinus (fenestra cochleae), and the stylomastoid foramen. The upper wall of the tympanic cavity was removed to measure the thickness of the facial canal walls. Ceramic cutters were used to cut the Fallopian canal down to its lower wall in the following areas: pr. pyramidalis, tympanic sinus, and stylomastoid foramen (Figure 2). The bone wall in the oval window niche (tympanic part) was easily broken off with micro-tools.

Then, the micro-tool (probe) with divisions drawn on its surface was set up in places where the facial nerve bone wall was cut and measured with a millimeter ruler to measure the canal wall thickness (Figure 3). The length of the instrument was 14 cm; the diameter of the tip was 0.5 mm.

To ensure the accuracy of the study, obtained fragments of bone walls of the mastoid process and the bone plates of the tympanic part of the facial nerve were measured with a digital caliper. The caliper was also used for external measurements to study the diameter of the canal in the oval window niche, pr. pyramidalis, tympanic sinus (fenestra cochleae), and the stylomastoid foramen.

Results

According to research results, the facial canal had no destructive changes; it was a homogenous research object in all 30 examinations. In 26 cadaver temporal bones, the Fallopian canal was located typically and the integrity of its bone walls was preserved. In three cases, the tympanic bone wall had singular dehiscences, the area of which varied from 1 to 4 mm². Dehiscences were located primarily in the medial wall, in the oval window niche. The absence of the facial canal upper wall from

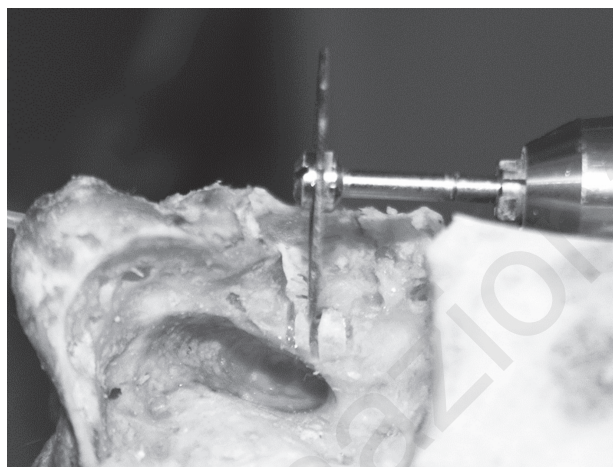


Fig. 2 - Cutting the bone walls of the facial canal with ceramic cutters in the pr. pyramidalis, tympanic sinus, and the stylomastoid foramen.

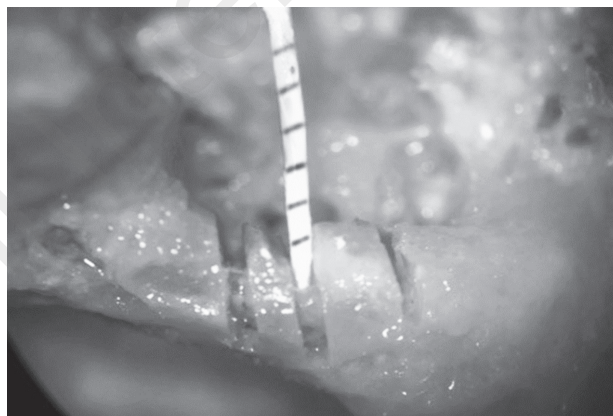


Fig. 3 - Measuring the thickness of the facial canal bone wall with a micro-tool.

the geniculate ganglion to the pr. pyramidalis was found in one case. The thickness of the bone wall in the tympanic part of the facial nerve in all preparations did not exceed 0.1 mm (0.06 ± 0.01 mm). In the mastoid process, it was as follows: 0.8 ± 0.1 mm in the pr. pyramidalis; 0.9 ± 0.2 mm in the tympanic sinus; 1.6 ± 0.2 mm in the stylomastoid foramen.

The diameter of the facial canal towards the stylomastoid foramen increased in size: 1.1 ± 0.1 mm in the oval window; 2.5 ± 0.2 mm in the pr. pyramidalis; 3.0 ± 0.2 mm in the posterior semicircular canal; 4.6 ± 0.4 mm in the stylomastoid foramen.

The CT scan of 15 micro-preparations of temporal bones by administering a contrast agent along the facial canal provided the following data (Figure 4):

- 1) The thickness of the facial canal bone wall in the oval window was 0.4 ± 0.1 mm.
- 2) The thickness of the facial canal bone wall in the pr. pyramidalis was 0.8 ± 0.1 mm.

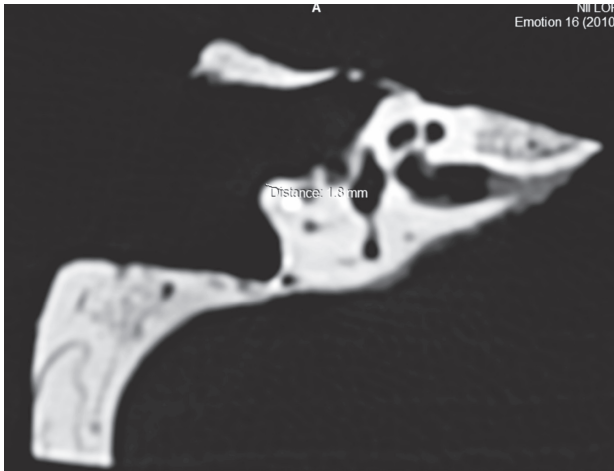


Fig. 4 - Axial projection of the CT of the right cadaver temporal bone with contrast enhancement. The tympanic bone wall of the facial nerve is intact; its thickness in the stylomastoid foramen is 1.8 mm.



Fig. 5 - Axial projection of the CT of the right cadaver temporal bone with contrast enhancement (magnified image of the facial nerve tympanic part). The bone wall thickness was 0.3 mm.

TABLE 1 - COMPARATIVE ANALYSIS OF RESULTS OF MEASURING THE THICKNESS OF BONE WALLS OF THE FACIAL NERVE OBTAINED THROUGH DISSECTION AND COMPUTED TOMOGRAPHY.

Facial canal	Statistical values of thickness of facial nerve bone walls (mm) $\bar{X} \pm m\bar{x}$		p
	Dissection (n=26)	CT (n=15)	
Tympanic part	0.06±0.01	0.4±0.1	3.3 *10 ⁻¹⁹
Pr. pyramidalis	0.8±0.1	0.8±0.1	0.2
Tympanic sinus	0.9±0.2	0.9±0.2	0.5
Stylomastoid foramen	1.6±0.2	1.7±0.1	0.1

P is the confidence level of differences in values (Student's t -test), N is the number of examinations, \bar{X} is the mean value, $m\bar{x}$ is the standard deviation.

- 3) The thickness of the facial canal bone wall in the tympanic sinus was 0.9±0.2 mm.
- 4) The thickness of the facial canal bone wall in the stylomastoid foramen was 1.7±0.1 mm.

Results obtained from measuring the thickness of bone walls of the Fallopian canal with a digital caliper and a probe match the data obtained with a CT scan with contrast enhancement of the facial nerve when examining the mastoid process ($p>0.05$) and have statistically significant differences in the tympanic part index ($p<0.05$) (Table 1).

Considering the characteristics of a computer tomograph, where the scanning pitch is 0.6 mm, and the "enhancement" of tympanic bone walls of the facial nerve with the contrast agent (Figure 5), the values that were obtained when measuring the tympanic part of the facial nerve with a caliper were considered a standard and

were used, together with the values of bone wall thickness, to determine the depth of passage of current.

Forty-eight radical surgeries were performed with intramuscular stimulatory EMG of the facial nerve. Solution of continuity of the facial nerve bony canal (dehiscence) was found during surgery in six patients. The average values of threshold electric stimulation of the facial canal with an intact bone wall in the tympanic part was 0.6±0.2 mA; in the mastoid process: 1.1±0.3 mA in the area of the pr. pyramidalis, 1.0±0.3 mA in the area of the tympanic sinus, and 3.1±0.2 mA in the area of the stylomastoid foramen.

The authors estimated the area of the Fallopian canal cross-section in the area of the tympanic part (0.8±0.2 mm²), the pr. pyramidalis (1.1±0.3 mm²), the tympanic sinus (1.1±0.2 mm²), and the stylomastoid foramen (1.8±1.0 mm²) according to the following formula:

$$S = 3.14 \times \left(\frac{d}{2} - t \right)^2$$

where d is the outside diameter of the facial canal, t is the thickness of the facial canal bone wall.

The obtained data on the cross-section area and transosseous facial nerve stimulation allowed determining the current density in various parts of the Fallopian canal (Table 2):

$$J = \frac{I}{S}$$

where I is the amperage (mA), S is the cross-section area (mm²)

As seen in the statistical diagram (Figure 6), the density of the threshold amperage, applied in various parts of the Fallopian canal ($p>0.05$), is identical across the

TABLE 2 - CURRENT DENSITY VALUES IN THE BONY CANAL DURING FACIAL NERVE STIMULATION.

Facial canal	N	Statistical indicators of current density (mA/mm ²) $\bar{X} \pm m\bar{x}$
Tympanic part	26	1.0 \pm 0.2
Pr. pyramidalis	30	1.1 \pm 0.4
Tympanic sinus	30	1.0 \pm 0.2
Stylomastoid foramen	12	1.2 \pm 0.3

N is the number of examinations, X is the mean value.

entire cross-section of the facial nerve. Consequently, this experiment allows assuming the possibility of comparing results, obtained from cadaver temporal bones (thickness of the Fallopian canal bone walls), with intraoperative results (threshold amperage).

The analysis of obtained results proved a positive linear relationship between the amperage thresholds

(mA) and the thickness of the facial canal bone walls (mm): Spearman's correlation coefficient $r_s = 0.78$ with a $p=0.03$ significance level. Figure 7 shows a scatter diagram with a regression model of amperage changes during transosseous electric stimulation of the tympanic part and mastoid processes of the facial canal, depending on the thickness of its bone walls. The R^2 coefficient of determination has a value of more than 0.5, which indicates a high informational value of the regression model. Proceeding from the obtained regression equation, $y=1.2x+0.2411$, it is possible to conclude that with the growth of the bone wall by 1 mm, the mean value of the amperage (mA) increases by 1.2 mA. At that, the threshold amperage of 1 mA = $1 \div 1.2 = 0.8$ mA.

Discussion

Accurate identification of the facial nerve in the temporal bone is necessary to improve the safety of the sur-

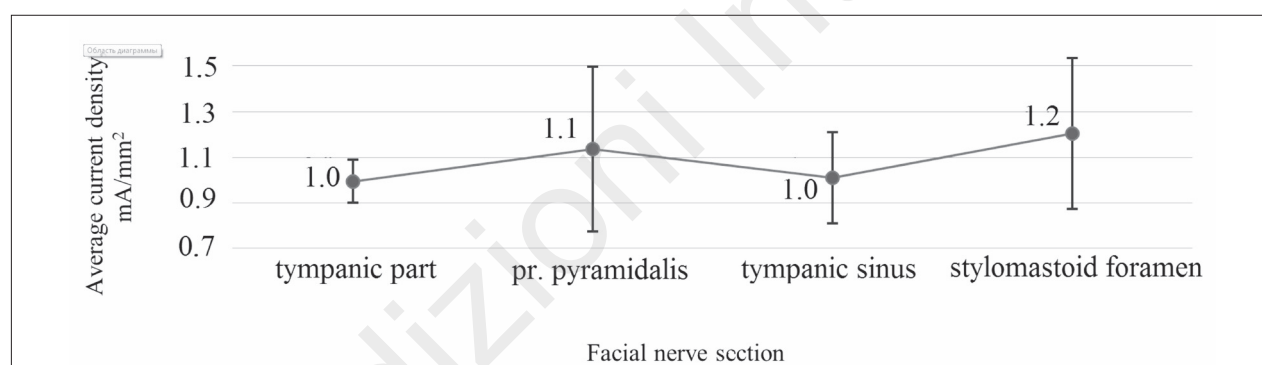


Fig. 6 - Correlation between mean values of current density in various parts of the facial canal (mA/mm²).

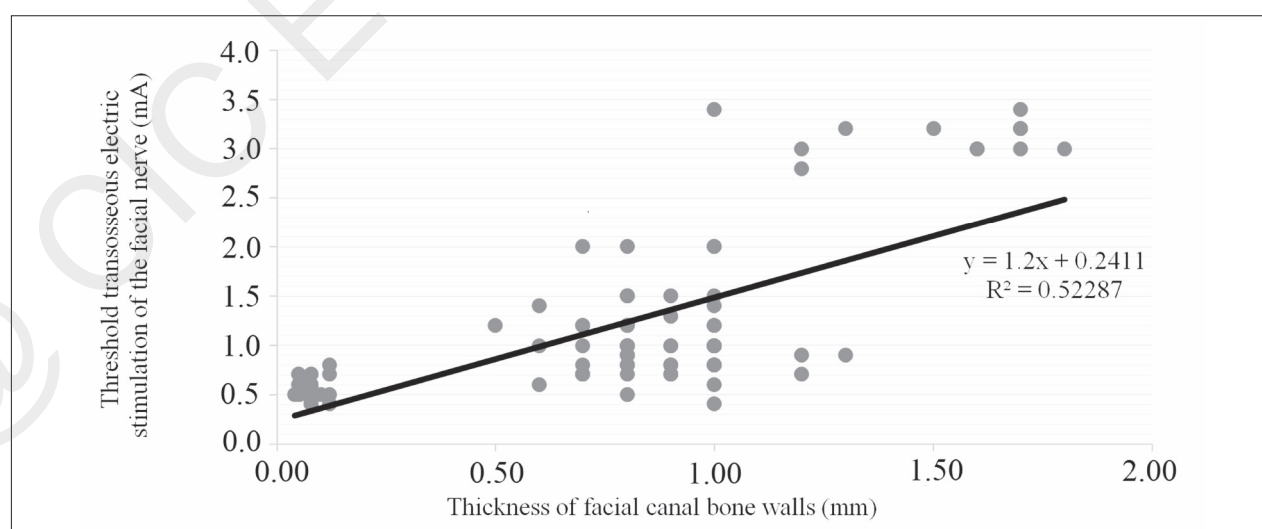


Fig. 7 - Regression dependence of amperage (mA) on the thickness of bony canal walls in the facial nerve (mm).

gical treatment of patients with a pathology of the middle and inner ear. The stimulating burr allows performing intraoperative monitoring of the facial nerve throughout the entire surgery (16-18). This system is safe and simple, and saves time during middle and inner ear surgery (18). Furthermore, the advantage of using the suggested technique of intraoperative diagnostics of the facial nerve is especially obvious in cases, when the anatomy of the middle ear is distorted by previous surgery, as well as in cases of malformation of the facial nerve (2, 6-8).

In order to determine the depth (mm) of the facial nerve, located in the bony canal, with the help of neuromonitoring, the authors conducted a comparative analysis of the thickness of the Fallopian canal bone wall (in mm), obtained during the dissection of cadaver temporal bones, with the data on threshold transosseous facial nerve stimulation in mA, carried out after a radical operation on patients with an intact Fallopian canal bone wall. Threshold amperage values were used as the amperage for the facial nerve stimulation to obtain M-responses with an amplitude of 100 μ V in one of the four canals of EMG-activity registration, since in this condition, depolarization of a part of nerve fibers occurs, engaging its surrounding tissues. A statistically significant regression model was obtained (Figure 7), where the mean value of amperage increased by 1.2 mA with the growth of the bone wall by 1 mm. Thus, the threshold amperage of 1 mA corresponds to 0.8 mm of facial canal bone wall thickness. Obtained results are in line with the results of the study by H. Silverstein et al., where 1 mm of Fallopian canal bone wall thickness corresponded to 1 mA amperage, and can be recommended for predicting the approximate distance to the facial nerve when operating with a stimulating burr, which will ensure the safe removal of the bone tissue that surrounds the nerve (17). This statement is approximate and can be used only under strict observance of the methods of performing intraoperative monitoring of the facial nerve.

In addition, the authors studied the density of the threshold amperage (mA/mm²), applied to the facial nerve bony canal. The analysis showed a lack of statistically significant discrepancies in current densities between points of facial canal stimulation ($p>0.05$). Therefore, the technique of intraoperative facial nerve monitoring that is described in this paper is correct, while the experiment was conducted in approximately identical conditions.

Intraoperative monitoring of the facial nerve can help young surgeons be more confident when surgically exposing structures of the middle and inner ear, while for surgeons who are more experienced its application can reduce significantly the time of surgery. Nonetheless, this method of functional identification of the facial nerve

does not replace anatomical knowledge, but is a useful addition for carrying out surgery on the middle and inner ear.

Conclusion

Solution of continuity of bone walls of the facial canal could result from carious and destructive changes with chronic suppurative otitis media, in particular, with a complication of cholesteatoma; abnormal development of the facial canal with congenital malformation of the ear; injury of the Fallopian canal in cases of temporal bone fracture or removal of the bone shelf over the facial nerve with a burr; arrested development of the Fallopian canal; presence of masses in the temporal bone (1-3, 6-9, 11, 12, 15). The situation can be aggravated by pathological tissues, most often – fragments of the cholesteatoma matrix that conceal the defect in the facial canal wall (2, 9, 11, 12), which increases the risk of damaging it and may cause dysfunction of the facial nerve that manifests as paresis (paralysis) of facial muscles (1-3, 9). Only several papers have been published to date regarding the use of intraoperative electromyography monitoring of the facial nerve with a burr; these papers mostly concern the safe removal of the acoustic nerve neuroma (13, 16, 18). Therefore, the problem of preserving the anatomical and functional integrity of the facial nerve with available surgical and diagnostic techniques is still relevant. This predetermines the necessity of studying the intraoperative monitoring of the facial nerve by needle electromyography with continuous stimulation with a burr.

M-responses were received to threshold stimulation of the facial nerve during intraoperative monitoring of the facial nerve in patients with chronic suppurative otitis media. In this research, the amperage values that caused M-responses at 100 μ V in one of the four registered canals were considered threshold stimulation. The integrity of the bony canal was preserved in all examinations. Amperage values for threshold transosseous stimulation of the facial nerve were as follows: 0.6 ± 0.2 mA in the tympanic part; in the mastoid process – 1.1 ± 0.3 mA in the pr. pyramidalis, 1.0 ± 0.3 mA in the tympanic sinus, and 3.1 ± 0.2 mA in the stylomastoid foramen.

The microtopographic anatomy of the Fallopian canal was examined during the morphometric study of 30 cadaver temporal bones. The thickness of the bone wall in the tympanic part of the facial nerve in all preparations did not exceed 0.1 mm (0.6 ± 0.01 mm), while in the mastoid process, it was as follows: 0.8 ± 0.1 mm in the pr. pyramidalis; 0.9 ± 0.0 mm in the fenestra cochleae (tympanic sinus); 1.6 ± 0.2 mm in the stylomastoid foramen. The area of the cross-section of the Fallopian canal was as follows: 0.8 ± 0.2 mm² in the tym-

panic part; $1.1 \pm 0.3 \text{ mm}^2$ in the pr. pyramidalis; $1.1 \pm 0.2 \text{ mm}^2$ in the tympanic sinus; $1.8 \pm 1.0 \text{ mm}^2$ in the stylomastoid foramen. The diameter of the facial canal was as follows: $1.1 \pm 0.1 \text{ mm}^2$ in the oval window; $2.5 \pm 0.2 \text{ mm}^2$ in the pr. pyramidalis; $3.0 \pm 0.2 \text{ mm}^2$ in the posterior semicircular canal; $4.6 \pm 0.4 \text{ mm}^2$ in the stylomastoid foramen. In the case of measurement of the bone wall thickness in the tympanic part of the Fallopian canal by CT scan of temporal bones with contrast enhancement of the facial nerve, the respective value was $0.44 \pm 0.1 \text{ mm}$; when measuring it with a caliper, the value was $0.06 \pm 0.00 \text{ mm}$. Comparative analysis showed statistically significant differences ($p < 0.05$) in the thickness of tympanic bone walls obtained with different measurement techniques. Considering the characteristics of a computer tomograph, where the scanning pitch is 0.6 mm , and the "enhancement" of tympanic bone walls of the facial nerve with the contrast agent (Figure 5), the values that were obtained when measuring the tympanic part of the facial nerve with a caliper were considered a standard and were used, together with the values of bone wall thickness, to determine the depth of passage of current. Thus, the thickness of the bone wall of the facial canal was as follows: $0.06 \pm 0.01 \text{ mm}$ in the oval window; $0.84 \pm 0.15 \text{ mm}$ in the pr. pyramidalis; $0.9 \pm 0.14 \text{ mm}$ in the fenestra cochleae (tympanic sinus); $1.76 \pm 0.3 \text{ mm}$ in the stylomastoid foramen.

After comparing the results of studies, it was found that 1 mA of threshold amperage corresponded to 0.8 mm thickness of the bone wall of the facial canal.

It was also noted that using burrs that were connected to the EMG machine had certain advantages, since th-

roughout the operation of the burr, electric current was supplied to the cutters, which gave the surgeon an understanding of the approximate thickness of the bone wall that surrounded the nerve, which enabled choosing a safer approach to the middle and inner ear. All EMG events were accompanied with an audio signal, which ensured that surgical manipulations near the nerve were more careful. In addition, the removal of bone tissue from the medial surface of the Fallopian canal was safer – in this place, the facial nerve is often damaged by the sides of cutters, while the removal of the bony mass is controlled by intraoperative monitoring of the facial nerve within safe EMG values. These values of transosseous threshold stimulation in potentially "dangerous" places of damage in the facial nerve were determined in the present research; said values confirm the integrity of the Fallopian canal.

Thus, the research with the use of stimulation needle four-channel EMG proves the expediency of its use in otological surgery.

Acknowledgements

The Authors would like to thank the Saint-Petersburg Research Institute of Ear, Throat, Nose and Speech for providing premises and equipment for this research.

Conflict of interest

No conflicts of interests are observed. All the authors confirm that the study was conducted at the expense of personal funds and deny any external interference, which could affect research results.

References

1. Green JD, Shelton C, Brackmann DE. Iatrogenic facial nerve injury during otologic surgery. *Laryngoscope*. 1994 Aug;104(8 Pt 1):922-6.
2. Asma A, Marina MB, Mazita A, Fadzilah I, Mazlina S, Saim L. Iatrogenic facial nerve palsy: lessons to learn. *Singapore Med J*. 2009 Dec;50(12):1154-7.
3. Kalina V, Shuster M. *Peripheral facial palsy*. Moscow: Meditsina; 2003.
4. OV S. *Clinical anatomy of ear*. Saint Petersburg: Spe Lit; 2004. 271 p.
5. Proctor B. The anatomy of the facial nerve. *Otolaryngol Clin North Am*. 1991 Jun;24(3):479-504.
6. Dew LA, Shelton C. Iatrogenic facial nerve injury: prevalence and predisposing factors. *Ear Nose Throat J*. 1996 Nov;75(11):724-9.
7. Jahrsdoerfer RA, Lambert PR. Facial nerve injury in congenital aural atresia surgery. *Am J Otol*. 1998 May;19(3):283-7.
8. Swartz J, Faerber E. Congenital malformations of the external and middle ear: High-resolution CT findings of surgical importance. *Am J Neuroradiol*. 1985;501-6.
9. Schuring AG. Iatrogenic facial nerve injury. *Am J Otol*. 1988 Sep;9(5):432-3.
10. Nilssen EL, Wormald PJ. Facial nerve palsy in mastoid surgery. *J Laryngol Otol*. 1997 Feb;111(2):113-6.
11. Selesnick SH, Lynn-Macrae AG. The incidence of facial nerve dehiscence at surgery for cholesteatoma. *Otol Neurotol*. 2001 Mar;22(2):129-32.
12. Wang H-M, Lin J-C, Lee K-W, Tai C-F, Wang L-F, Chang H-M, et al. Analysis of mastoid findings at surgery to treat middle ear cholesteatoma. *Arch Otolaryngol Head Neck Surg*. 2006 Dec;132(12):1307-10.
13. Delgado TE, Bucheit WA, Rosenholtz HR, Chrissian S. Intraoperative monitoring of facila muscle evoked responses obtained by intracranial stimulation of the facila nerve: a more accurate technique for facila nerve dissection. *Neurosurgery*. 1979 May;4(5):418-21.
14. Roland PS, Meyerhoff WL. Intraoperative electrophysiological

- monitoring of the facial nerve: Is it standard of practice? *Am J Otolaryngol.* 1994 Jul;15(4):267-70.
15. Prass RL. Iatrogenic facial nerve injury: the role of facial nerve monitoring. *Otolaryngol Clin North Am.* 1996 Apr;29(2):265-75.
 16. Silverstein H. Adaptor for continuous stimulation (SACS) with the WR-S8 monitor-stimulator. *Otolaryngol neck Surg.* 1990 Sep;103(3):493-6.
 17. Silverstein H, Smouha E, Jones R. Routine identification of the facial nerve using electrical stimulation during otological and neurotological surgery. *Laryngoscope.* 1988 Jul 3;98(7):726-30.
 18. Bernardeschi D, Meskine N, Otaibi N Al, Ablonczy R, Kalamarides M, Grayeli AB, et al. Continuous facial nerve stimulating burr for otologic surgeries. *Otol Neurotol.* 2011 Oct;32(8):1347-51.
 19. Khamgushkeeva N. The effectiveness of use of intraoperative facial nerve monitoring and computed tomography of the temporal bone in diagnosis of integrity facial canal. *Russ Otorhinolaryngol.* 2015;3(76):141-5.
 20. Randolph GW, Dralle H, Abdullah H, Barczynski M, Bellantone R, Brauckhoff M, et al. Electrophysiologic recurrent laryngeal nerve monitoring during thyroid and parathyroid surgery: international standards guideline statement. *Laryngoscope.* 2011 Jan;121 Suppl:S1-16.
-