

## Efficacy of preoperative computed tomography imaging to reduce negative appendectomies in patients undergoing surgery for left lower quadrant abdominal pain

N. KONTOPODIS<sup>1</sup>, A. KOURAKI<sup>1</sup>, G. PANAGIOTAKIS<sup>1</sup>, M. CHATZIOANNOU<sup>2</sup>, K. SPIRIDAKIS<sup>1</sup>

**SUMMARY:** Efficacy of preoperative computed tomography imaging to reduce negative appendectomies in patients undergoing surgery for left lower quadrant abdominal pain.

N. KONTOPODIS, A. KOURAKI, G. PANAGIOTAKIS, M. CHATZIOANNOU, K. SPIRIDAKIS

**Background.** Clinical assessment of acute appendicitis can be challenging due to atypical presentation. Computed-tomography can reduce negative appendectomies but not without adverse effects. We report our experience with preoperative CT-scan in patients with suspected acute appendicitis.

**Patients and methods.** During 3-years, 257 adult patients underwent appendectomy. We retrospectively reviewed clinical information, CT-scans, histological data. Patients were divided in four groups: Group I: low clinical probability without CT-scan; Group II: low clinical

probability with CT-scan; Group III: high clinical probability without CT-scan; Group IV: high clinical probability with CT-scan.

Negative appendectomies were determined from histological examination. Negative appendectomy rate was compared between groups of the same clinical probability differing on whether a pre-operative CT scan was performed or not (Group I vs II, Group III vs IV).

**Results.** Groups I,II,III,IV included 12.4%, 18.2%, 54.5% and 14.8% of patients, respectively. The corresponding negative appendectomy rates were 18.7%, 4.3%, 4.2% and 2.6%. Odds ratio of negative appendectomy for patients without CT-scan was 5.2 (95% CI: 1.2-27.7) when there was low clinical probability and 1.6 (95% CI: 0.2-14.2) for high clinical probability.

**Conclusion.** Patients with low clinical probability of acute appendicitis benefit the most from preoperative CT while this does not apply to patients with high clinical probability.

**KEY WORDS:** Acute abdominal pain - Imaging modalities - Clinical evaluation - Appendicitis - CT scan - Negative appendectomy rate - Alvarado score.

## Background

Appendicitis is one of the most common causes of acute abdominal pain for which patients seek medical assistance in surgical emergency departments. Approximately 250,000 cases of appendicitis occur annually in the United States accounting for an estimated 1 million hospital days per year. A life table model suggests that the lifetime risk of appendicitis is 8.6% for males and 6.7% for females while the lifetime risk of appendectomy is 12.0% and 23.1% respectively (1, 2).

Early diagnosis and surgical intervention are essential for the successful management of this condition. This is not always straightforward since clinical evaluation such as history, physical examination and laboratory tests can be misleading in the same that the differential diagnosis includes conditions with similar presentation which require medical treatment. It has been reported that the accuracy of clinical diagnosis for acute appendicitis ranges from 71% to 97% and scoring tests have been developed to assist the clinician in the evaluation of such a condition, the most widely accepted being Alvarado's score (2-4). This includes clinical presentation, physical findings and laboratory examinations (5). To avoid morbidity and mortality associated with appendiceal rupture, it would have been acceptable decades ago to remove healthy appendixes at a rate of 20% based on physical examination (6). In the same time the consequences of a negative appendectomy include intra-abdominal adhesions, negative effects of anesthesia, increase of cost etc. while complications after a negative appendectomy occur in 6% and reoperation is needed in 2% of patients (7).

<sup>1</sup> Venizeleio General Hospital of Heraklion, Surgical Department, Heraklion Crete, Greece

<sup>2</sup> Venizeleio General Hospital of Heraklion, Radiology Department, Heraklion Crete, Greece

Corresponding Author: Nikolaos Kontopodis, e-mail: kontopodisn@yahoo.gr

© Copyright 2014, CIC Edizioni Internazionali, Roma

Since late 1990s, imaging modalities have increasingly become popular for the diagnosis of acute appendicitis as an adjunct to physical examination. Rao et al. reported an accuracy of 93%-98% for CT scan, in the assessment of patients with suspected acute appendicitis, while ultrasonography has been proven to be inferior for this task (8-10). In the literature there is a controversy whether CT should be routinely used for the evaluation of patients with suspected acute appendicitis. In the same time that most authors note a decrease in negative appendectomy rate (NAR) with the use of CT, there is a concern about increased exposure to radiation, adverse effects of contrast agents and appropriate use of health resources (11-13). The current study attempts to present our experience with the use of CT scan in patients with right lower quadrant abdominal pain. The main endpoint of the analysis was NAR and how it is influenced by the usage of preoperative CT scan for patients with low compared to those with high clinical probability of acute appendicitis.

## Patients and methods

### *Study participants*

We conducted a retrospective analysis which included the adult patients ( $\geq 18$  years old) that presented to the emergency department of our hospital complaining about acute abdominal pain and subsequently underwent appendectomy for suspected acute appendicitis. During a 3-years period, from February 2009 till January 2012, 257 such patients were reviewed.

### *Study design*

Ethical approval for this study was obtained by the local scientific board of the Venizeleio General Hospital of Heraklion. Patient's data were retrospectively reviewed. This regarded the clinical presentation at the time of admission in the emergency department including signs, symptoms and laboratory results, and calculation of Alvarado score which were routinely recorded in hospital's medical records. All patients were evaluated by a surgical resident initially and subsequently by a supervisor consultant surgeon who decided which patients would undergo imaging with the use of ultrasonography or CT scan and also further management. Regarding imaging techniques, generally CT was preferred over ultrasonography for patients without contraindications to radiation exposure and contrast agents whereas the later was mainly reserved for cases with dubious clinical presentation in the presence of such contraindications. The use of CT scan / ultrasonography and concomitant findings were also recorded. Radiographically, a positive diagnosis of acute appendicitis was made with visual iden-

tification of an abnormal appendix or the presence of periappendiceal inflammatory changes. Finally the histological results were also reviewed and the negative appendectomy rates were calculated. A negative appendectomy was defined as a case in which the appendix was removed for suspected acute appendicitis that was not confirmed on histological examination. Additionally the presence of appendiceal perforation was also recorded for every case under evaluation.

The patients were divided according to high (Alvarado score  $\geq 5$ ) or low (Alvarado score  $< 5$ ) clinical suspicion of acute appendicitis as it has been described elsewhere (5, 14). Specifically previous research has suggested that an Alvarado score of 5 or 6 indicated possible appendicitis; 7 or 8, probable appendicitis; and 9 or 10, very probable appendicitis (5). Subsequently other studies considered a score of 5 or higher as positive whereas 4 or less as negative for acute appendicitis (14). We followed the same kind of classification.

Moreover they were divided depending on whether a CT scan was performed or not. This finally resulted in four groups of patients that underwent appendectomy:

- Group I: low clinical suspicion without a preoperative CT scan;
- Group II: low clinical suspicion with a preoperative CT scan;
- Group III: high clinical suspicion without a preoperative CT scan and
- Group IV: high clinical suspicion with a preoperative CT scan.

The utility of CT scan as a diagnostic adjunct, in the evaluation of patients with suspected appendicitis was determined by documenting the rate of negative appendectomies in each of the aforementioned group of patients and comparing between groups that shared the same clinical probability for acute appendicitis. Odds ratios were calculated. Pearson  $\chi^2$ -test was applied to determine statistical significance of differences. Appendiceal perforation was also recorded and compared between groups.

Furthermore, data regarding factors that could have affected observed results, like demographic information (i.e. age, gender, pregnancy) and additional ultrasound imaging have been recorded and compared between groups. Statistical significance of differences have been assessed using Pearson  $\chi^2$ -test for qualitative data. For quantitative data Analysis of Variance (ANOVA) was applied if data were normally distributed and Kruskal Wallis test if they were not.

## Results

During a 3-years period from February 2009 till January 2012, 257 adult patients underwent appendectomy

due to suspected acute appendicitis in our surgical department. One-hundred nine patients were male (42%) whereas 148 were female (58%). The mean age of patients was 34 years old. In our study population there were 10 pregnant patients. Out of 257 patients the majority was surgically managed based on the clinical and laboratory findings alone (172 patients- 67%), whereas only 85 patients underwent preoperative CT scan (33%). Women were more likely to undergo CT scan as 40.5% of female patients and only 23% of male patients had a preoperative evaluation with CT and this difference was statistically significant (Pearson  $\chi^2$  test, p-value=0.03).

Thirty-two patients (12.4%) were installed to Group I. They had not been evaluated with a CT scan in spite of the poor clinical signs mainly because of contraindications to intravenous contrast agents such as allergy or renal insufficiency and contraindications to exposure to radiation i.e. because of pregnancy. These patients underwent appendectomy after a period of observation due to clinical worsening in the absence of an alternative diagnosis. There were forty-five patients (18.2%) in Group II. The majority of patients were installed at group III (one hundred and forty patients - 54.5%) whereas Group IV included thirty eight patients (14.8%). Age, gender and pregnancy rate were not significantly different between groups. Ultrasonography was mainly used in patients of group I (those with low clinical suspicion without a pre-operative CT scan) and specifically it was employed in 16/32-50% of these patients. In patients of groups II, III and IV it was rarely used (group II: 4/47-8.5%, group III: 15/140-11%, group IV: 4/38-11%). The four groups of patients along with demographic information and use of other imaging modalities (ultrasound) as well as statistical significance of differences are presented in Table 1.

Total number of negative appendectomies was 15 out of 257 appendectomies performed (5.8%). There were significant differences when comparing these parameters between the four groups of patients. In group I out of 32 appendectomies, there were 6 negative (18.7%). In group II there were 47 appendectomies performed, 2 of which were characterized as negative (4.2%). In Group

III the corresponding values were 6 negative appendectomies between 140 patients with a rate of 4.3%. Finally in Group IV there was only 1 case of negative appendectomy among 38 appendectomies (2.6%). Among patients with low clinical probability of appendicitis (groups I and II) odds ratio for a negative appendectomy was 5.2 more in those that did not have a preoperative CT scan and this was statistically significant (Pearson  $\chi^2$  test, 95% CI: 1.2-27.7). Among patients with high clinical probability of appendicitis (groups III and IV) odds ratio for negative appendectomy was 1.6 more in those without a preoperative CT scan but difference was statistically insignificant (Pearson  $\chi^2$  test, 95% CI: 0.2-14.2). Figure 1 presents the negative appendectomy rate (NAR) for the four groups of patients.

Regarding appendiceal perforation there were no cases in groups I and II to be identified. This is expected since patients assigned to those groups had an Alvarado score <5 which means a dubious clinical presentation and a low probability for acute appendicitis. On the contrary in group III there were 42/140 cases (30%) while in group IV there were 14/38 cases (37%) where pathology examination indicated a perforated appendix. The difference between those groups was not statistically significant (Pearson  $\chi^2$  test, p-value=0.436).

## Discussion

Acute appendicitis is the most common surgical pathology of patients presenting in the emergency department complaining about abdominal pain while early and accurate diagnosis, along with surgical intervention is considered the mainstay of treatment to avoid complications. Clinical assessment alone was used in the past for the evaluation of patients and the Alvarado score is probably the most widely used scoring system for the diagnosis of acute appendicitis. It uses 8 different parameters with regard to clinical history, physical examination and laboratory values giving a total score of 10. A total of 93% accuracy was reported for the diagnosis of appendicitis in the presence of a score 7 or higher (5). However, others repor-

TABLE 1 - PROPORTION OF PATIENTS IN THE FOUR GROUPS DEPENDING ON CLINICAL PROBABILITY OF ACUTE APPENDICITIS AND USAGE OF A PREOPERATIVE CT SCAN.

Group	Clinical probability	CT scan	Population number	Age	Gender (M/F) (%F)	Pregnancy	US
I	Low (Alvarado Score <5)	-	32 (12.4%)	37	22/10 (68%)	3 (10%)	16 (50%)
II	Low (Alvarado Score <5)	+	47 (18.2%)	32	28/19 (59%)	0	4 (8.5%)
III	High (Alvarado Score $\geq$ 5)	-	140 (54.5%)	33	75/65 (53%)	7 (5%)	15 (11%)
IV	High (Alvarado Score $\geq$ 5)	+	38 (14.8%)	34	23/15 (60%)	0	4 (11%)

Age did not significantly differ between groups (ANOVA, p-value=0.08) which was also valid for gender (Pearson's  $\chi^2$  test, p-value=0.43) and pregnancy (Pearson's  $\chi^2$  test, p-value=0.091). Ultrasound imaging was significantly more common in group I (Pearson's  $\chi^2$  test, p-value<0.001). M: Male, F: Female, US: Ultrasound.

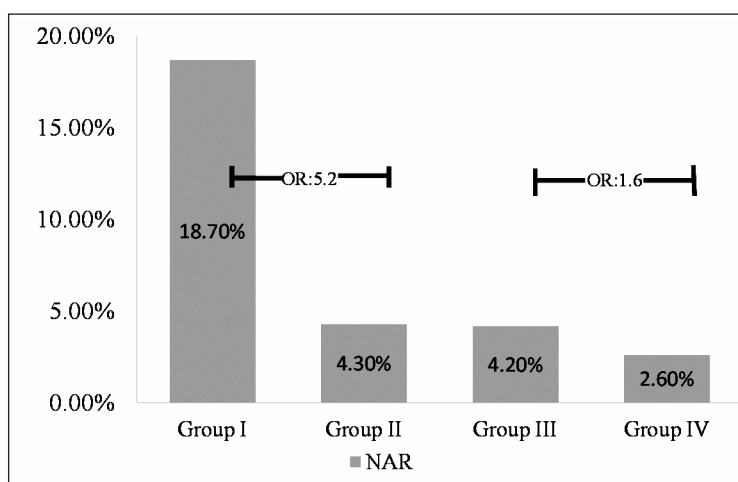


Fig. 1 - Negative appendectomy rate (NAR) for the four groups of patients. Odds Ratios (OR) are displayed.

ted lower diagnostic accuracy of clinical diagnosis for acute appendicitis and suggested the concurrent use of imaging techniques in patients with suspected appendicitis (2-4). Rao et al. reported a high accuracy of focused non-enhanced CT scan for this purpose (93% to 98%), in the same time that studies comparing the results of CT scan and ultrasonography report a sensitivity of 90%-100% and a specificity of 95%-97% for the former with sensitivity and specificity of 92% and 85% respectively for the latter (8, 9, 14-16). These results in favor of CT scan make it the imaging technique of choice for patients with suspected appendicitis. Computed tomography is thought to reliably diagnose appendicitis by visualization of an abnormal appendix and periappendiceal inflammatory changes. A diameter greater than 6mm is considered to be inflamed as well as appendolith and thickened wall. Fat stranding, periappendiceal fluid, mass, abscess, air bubbles and adenopathy are other indications of acute appendicitis (17-20).

Many studies demonstrate the effectiveness of CT in reducing the negative appendectomy rate (NAR). A 18-year retrospective institutional review by Raja et al that included 1608 appendectomies report a reduction in NAR from 1990 to 2007 from 23% to only 1.7%. In the same time the proportion of patients that underwent appendectomy having had a preoperative CT increased impressively from 1% to 97.5% meaning that in some centers, currently almost all patients with suspected appendicitis undergo CT scan (12). Another retrospective multicenter comparative study that was conducted to determine the association between CT use and negative appendectomy rates at three different medical centers presented similar results. A total of 10.6% of the patients were found to have negative appendectomies. The CT group had a significantly lower negative appendectomy rate than the non-CT group (6.6% vs. 20.6%, respectively). The three centers had significant

ly different rates of CT utilization for diagnosing acute appendicitis (86.9%, 66.4%, and 13.3%) and this correlated well with significantly different negative appendectomy rates (2.5%, 16.8%, and 23.3%, respectively). The study concluded that the rate of negative appendectomies was inversely related to the rate of CT imaging before exploration in Emergency Department for patients with suspected appendicitis (21). Furthermore a study of 215 patients found a sensitivity of 90.1% and a specificity of 94.1% of CT scan alone in the evaluation of patients with suspected acute appendicitis which approached 98.3% and 95.8% respectively when it was combined with positive clinical examination (14). Subsequently the rate of negative appendectomy has been decreasing within the past 2 decades from more than 20% to less than 10% due to the wide use of preoperative CT scan.

However, the rate of CT has also been increasing from less than 20% to more than 90%. It is even observed that the use of CT scans has increased medical costs 10-fold within the past 2 decades (11-13). Moreover exposure to radiation is a serious concern when a CT scan is performed. The effective dose may be 50 to 1000 times as high as that of plain radiography, depending on the target organs (22). Adverse effects of contrast agents are usually mild but in rare cases there are serious adverse reactions. The incidence of anaphylactic shock due to contrast agents, according to various studies, is approximately 0.04% to 0.2% whereas approximately 1% to 4% of patients have experienced discomfort, including nausea, vomiting, dizziness, or a burning sensation (23, 24). Therefore physicians' current objective should be to take advantage of CT's potential for the diagnosis of acute appendicitis as well as minimizing its use only in patients that could benefit the most. For this task we attempted to examine the efficacy of CT scan when performed in patients with high clinical probability in comparison to

patients with low clinical probability with regard to negative appendectomy rate.

Regarding appendiceal perforation our results indicate that this can be easily ruled out with clinical examination alone since an Alvarado score  $<5$  excluded it in 100% of cases. Others have suggested that overall CT sensitivity for this task may be poor since unless abscess or extraluminal gas is present, CT cannot enable the diagnosis of perforation (25). On the other hand, taking into account acute appendicitis as a whole, with concern to all of its pathological stages, accurate diagnosis seems to be affected by the exploitation of imaging modalities. Specifically our results indicate that while in patients with low clinical suspicion of acute appendicitis clinical assessment alone resulted in a NAR of 18.7% a preoperative CT scan reduced this to 4.2%. These results may be confounded by the fact that a greater proportion of patients in the former group had an abdominal ultrasonography pre-operatively but it is expected that this should have lowered NAR. Subsequently the observed difference probably would be even greater if management of patients with low clinical suspicion of acute appendicitis was largely determined based on clinical assessment without the use of ultrasonography. Therefore for patients with low clinical probability there was an odds ratio of 5.2 to have a negative appendectomy for those without preoperative imaging compared to those that underwent CT and this was statistically significant. On the other hand patients with high clinical probability that underwent appendectomy based on clinical criteria alone had a NAR of 4.3% compared to 2.6% for those with preoperative CT. Therefore for patients with high clinical suspicion of acute appendicitis there was an odds ratio of only 1.6 to have a negative appendectomy for those that did not have preoperative imaging to those that had and this was not statistically significant. Subsequently patients with low clinical probability of acute appendicitis as it is expressed by an Alvarado score of less than 5 have a high NAR when surgical intervention is based only on clinical criteria whereas preoperative CT scan could reduce NAR significantly in these patients. For patients with high clinical suspicion of acute appendicitis as it is expressed by an Alvarado score of 5 or more, appen-

dectomy based only in clinical presentation, physical examination and laboratory values results in low NAR and preoperative CT scan usually is not necessary.

Limitations - The current study has been performed using retrospectively collected data and therefore it is subject to specific limitations of such a design. Therefore, this analysis may be prone to selection and recall bias but also to confounding by various factors (26, 27). Regarding our data, gender, pregnancy as well as usage of other imaging modalities may relate to clinical presentation and diagnosis of acute appendicitis and could have influenced observed results. Nevertheless, despite the fact that gender and pregnancy differed between groups, this difference did not reach statistical significance. Moreover, although use of ultrasound was significantly more often in group I, this would have been expected to lower NAR in this group, which was not the case in our study population. In other words in the absence of ultrasound imaging one can assume that differences would be even greater than those recorded here. In summary, the current analysis is subject to drawbacks inherent in all retrospective studies, but this limitation is unlikely to significantly influence obtained results.

## Conclusions

In conclusion, despite the diagnostic value of preoperative CT scan during evaluation of patients with suspected acute appendicitis, which is depicted by the significant reduction in negative appendectomy rate, CT is not without adverse reactions. Therefore its routine use should be discouraged and the decision of preoperative imaging should be based on clinical criteria. Patients with low clinical probability of acute appendicitis benefit the most from CT scan, in the same time that patients with high clinical probability can be safely managed based on clinical assessment alone without preoperative imaging.

---

### *Conflict of interest statement*

The authors declare they have no conflict of interest.

## References

1. Addiss DG, Shaffer N, Fowler BS, Tauxe RV. The epidemiology of appendicitis and appendectomy in the United States. *Am J Epidemiol.* 1990;132:910-925.
2. Graffeo CS, Counselman FL. Appendicitis. *Emerg Med Clin North Am.* 1996;14:653-671.
3. Andersson RE, Hugander A, Ravn H, Offenbartl K, Ghazi SH, Nystrom PO. Repeated clinical and laboratory examinations in patients with an equivocal diagnosis of appendicitis. *World J Surg.* 2000;24:479-485.
4. John H, Neff U, Kelemen M. Appendicitis diagnosis today: clinical and ultrasonic deductions. *World J Surg.* 1993;17:243-249.
5. Alvarado A. A practical score for the early diagnosis of acute appendicitis. *Ann Emerg Med.* 1986;15:557-564.
6. Flum DR, Morris A, Koepsell T, Dellinger EP. Has misdiagnosis of appendicitis decreased over time? A population-based analysis. *JAMA.* 2001;286:1748-1753.

7. Bijnen CL, Van dern Broek WT, Bijnen AB, de Ruiter P, Gouma DJ. Implications of removing a normal appendix. *Dig Surg.* 2003;20:215-221.
8. Rao PM, Rhea JT, Novelline RA, Mostafavi AA, McCabe CJ. Effect of computed tomography of the appendix on treatment of patients and use of hospital resources. *N Engl J Med.* 1998;338:141-146.
9. Rao PM, Rhea JT, Rattner DW, Venus LG, Novelline RA. Introduction of appendiceal CT: impact on negative appendectomy and appendiceal perforation rates. *Ann Surg.* 1999;229:344-349.
10. Doria AS, Moineddin R, Kellenberger CJ, Epelman M, Beyene J, Schuh S, Babyn PS, Dick PT. US or CT for diagnosis of appendicitis in children and adults? A meta-analysis. *Radiology.* 2006;241:83-94.
11. Coursey CA, Nelson RC, Patel MB, Cochran C, Dodd LG, DeLong DM, Beam CA, Vaslef S. Making the diagnosis of acute appendicitis: do more preoperative CT scans mean fewer negative appendectomies? A 10-year study. *Radiology.* 2010;254:460-468.
12. Raja AS, Wright C, Sodickson AD, Zane RD, Schiff GD, Hanson R, Baeyens PF, Khorasani R. Negative appendectomy rate in the era of CT: an 18-year perspective. *Radiology.* 2010;256:460-465.
13. Schreiner M, Spazier M, Wayand W. Diagnosis of acute appendicitis over two decades -effects of increasing number of imaging procedures on costs, preoperative reliability and patient outcome. *Zentralbl Chir.* 2010;135:336-339.
14. Gwynn LK. The diagnosis of acute appendicitis: Clinical versus computed tomography evaluation. *Journal of Emergency Medicine.* 2001;21:119-123.
15. Irvin TT. Abdominal pain: a surgical audit of 1190 emergency admissions. *Br J Surg.* 1989;76:1121-1125.
16. Balsano N, Cayten CG. Surgical emergency of the abdomen. *Emerg Med Clin North Am.* 1990;8:399-410.
17. Balthazar EJ, Megibow AJ, Siegel SE, Birnbaum BA. Appendicitis. Prospective evaluation with high resolution CT. *Radiology.* 1991;180:21-24.
18. Lane MJ, Katz DS, Ross BA, Cloutice-Engle TL, Mindelzun RE, Jeffrey RB. Unenhanced helical CT for suspected appendicitis. *AJR Am J Roentgenology.* 1997;168:405-409.
19. Rao PM, Wittenberg J, McDowell RK, Rhea JT, Novelline RA. Appendicitis. Use of arrowhead sign for diagnosis at CT. *Radiology.* 1997;202:363-366.
20. Rao PM, Boland GWL. Imaging of acute right lower abdominal quadrant pain. *Clin Radiol.* 1998;53:639-649.
21. Kyuseok K, Lee CC, Song KJ, Kim W, Suh G, Singer AJ. The impact of helical computed tomography on the negative appendectomy rate: a multi-center comparison. *The Journal of Emergency Medicine.* 2008;34:3-6.
22. Brenner DJ, Hall EJ. Computed tomography - an increasing source of radiation exposure. *N Engl J Med.* 2007;357:2277-2284.
23. Singh J, Daftary A. Iodinated contrast media and their adverse reactions. *J Nucl Med Technol.* 2008;36:69-74.
24. Bush WH, Swanson DP. Acute reactions to intravascular contrast media: types, risk factors, recognition, and specific treatment. *AJR Am J Roentgenol.* 1991;157:1153-1161.
25. Bixby SD, Lucey BC, Soto JA, Theysohn JM, Ozonoff A, Varghese JC. Perforated versus nonperforated acute appendicitis: accuracy of multidetector CT detection. *Radiology.* 2006;241:780-6.
26. Sedgwick P. What is recall bias? *BMJ.* 2012;344:3519.
27. Sedgwick P. Case-control studies: advantages and disadvantages. *BMJ.* 2013;348:7707.