

## Isolated splenic metastasis of ovarian cancer. Case report and literature review

G. RESTA, L. VEDANA, S. MARINO, L. SCAGLIARINI, M. BANDI, G. ANANIA

**SUMMARY:** Isolated splenic metastasis of ovarian cancer. Case report and literature review.

G. RESTA, L. VEDANA, S. MARINO, L. SCAGLIARINI, M. BANDI, G. ANANIA

*Splenic metastasis is extremely rare and are usually found in conjunction with metastasis of other organs. In addition, late recurrence even after 10 years of operation is very unusual. The most common*

*sources of splenic metastasis are lung, colorectal, melanoma, breast and ovarian carcinoma. We present a case of 67 year old woman who was admitted to our department with a solitary splenic metastases after hysterectomy with bilateral salpingo-oophorectomy for ovarian carcinoma 10 years ago. In conclusion, solitary splenic metastasis are very rare and the incidence of the reported cases in the medical literature is increasing. The treatment of choice is laparoscopic splenectomy that must be followed by chemotherapy in order to prevent the development of other possible micrometastases.*

**KEY WORDS:** Splenic metastasis - Laparoscopy - Ovaric cancer.

### Background

Splenic metastases from non-hematologic malignancies are infrequent, with an incidence of 0.6%-1.1% in populations with carcinoma according to a large clinicopathologic study (1). In a recent review of 6,137 patients with metastatic malignant tumors, only 59 (0.96%) involved the spleen. Commonly they are from breast, lung, ovarian, colorectal cancers and melanomas. These deposits are usually located on the splenic capsule and signify disseminated disease with a grim prognosis (2). When the deposits are solitary in the spleen, invade the parenchyma only and metastasize via the haematogenous route with a better prognosis (3). They usually present after a characteristic latent period; months to years after curative surgery for the initial tumor. They may present with painful splenomegaly or may be completely asymptomatic only discoverable by relevant imaging dur-

ing follow-up. The cure accepted worldwide is a classic splenectomy followed by post operative chemotherapy (4). Laparoscopic splenectomy is now considered to be the gold standard for treatment of benign haematologic disease. However, evidence for its use in malignant disease of the spleen remains limited (5).

### Case report

A 67 year old female presented with a history of total hysterectomy with bilateral salpingo-oophorectomy and adjuvant chemotherapy for ovarian cancer 10 years before. Abdominal ultrasound was ordered by her primary tumor, for control, and this showed multiple masses within the spleen which were suspicious for malignancy. A computed tomography scan of her abdomen was ordered to complete and revealed an enhancing 10x6x8 cm necrotic lesion, without lymphadenomegaly or distant metastases. The patient was completely asymptomatic. A hematologic control was done to evaluate the nature of the spleen lesion with research of high serum levels of carcinoembryonic antigen.

A laparoscopic splenectomy was performed with a diagnosis of splenic metastasis (Figures 1, 2). The spleen was delivered *en bloc* and without evidence of rupture. The specimen weighed 4,1 Kg, measured 17x10,3x5,8

"Sant'Anna" University Hospital, Ferrara, Italy  
General and Thoracic Surgery Unit, Department of Morphology,  
Surgery and Experimental Medicine

Corresponding Author: Lucia Scagliarini, e-mail: lucia.scagliarini82@gmail.com

© Copyright 2014, CIC Edizioni Internazionali, Roma

cm and had a intact capsule. There was a necrotic area measured 7,5x5,5 cm. Neoplastic cells showed positive immunohistochemical staining for CK7 (Figure 3), estrogen receptor and were negative for progesterone receptor and CK20 (Figure 4). This immunophenotype is indicative of a primary ovarian adenocarcinoma (Figure 5). No post-operative complications were reported. Our patient has performed adjuvant chemotherapy and she has been disease-free for nearly one year after splenectomy with a good performance status.

## Discussion

Most splenic metastases are accompanied by multi-visceral tumor dissemination (6). Solitary splenic metastasis is very uncommon and close to 100 such cases have been reported in the literature. Half of these are from the female genital tract; most commonly from ovarian malignancies (more than 30 cases) and the remainder from endometrial (13 cases), cervical (6 cases) and tubal carcinomas (1 case) (3). The rarity of splenic metastases might be explained by the following reasons: (1) the poorly developed lymphoid system of the spleen, especially the lack of afferent lymphatic vessels, prevents the spleen from receiving metastatic tumor cells *via* the lymphatic route; (2) the sharp angle of splenic artery branching from the celiac trunk inhibits large clumps of tumor cells from passing through; and (3) the microenvironment of the spleen may hinder the growth of micrometastatic foci (2). A review has shown 33% of solitary splenic metastasis were discovered on routine examination while they were completely asymptomatic (2). However, some patients harboring splenic metastases complain of fatigue, weight loss, fever, abdominal pain, splenomegaly, anemia, or thrombocytopenia (2). La Fianza and Madonia retrospectively compared US and CT in detection of splenic metastasis after curative surgery; both provided high accuracy, sensitivity and specificity however the micronodular pattern of splenic involvement gave false positive findings at US (7). It is the prudent and regular use of these imaging modalities during follow-up that has increased the number of case reports reported in the last decade. Generally, when an isolated splenic lesion is found during the oncologic follow-up, a metastatic origin should be suspected. In this regard, it is sometimes difficult to distinguish the suspected splenic metastases from primary splenic lesions such as lymphoma, vascular tumor, or infectious disorder. Serum levels of carcinoembryonic antigen and carbohydrate antigen 19-9 have been reported to be of predictive value in detecting the appearance of isolated splenic metastases in advance of imaging identification (8). It has been reported that  $^{18}\text{F}$ -FDG positron emission tomography was of value in distin-

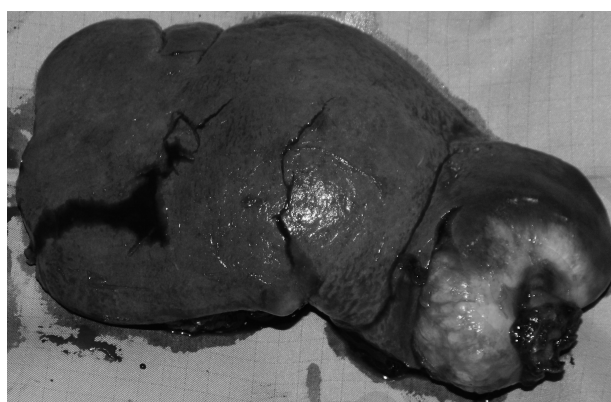

Fig. 1 - Macroscopic splenic metastasis.




Fig. 2 - Section of spleen showing intraparenchymal masses.


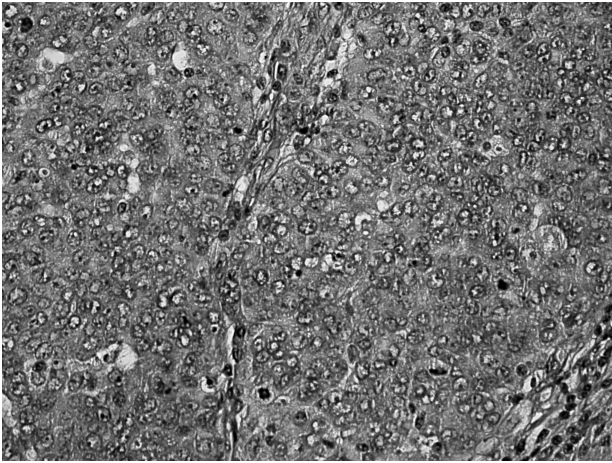


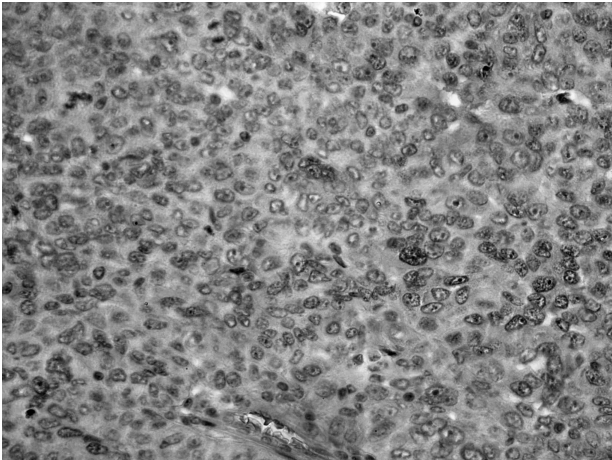
Fig. 3 - Neoplastic cells shown by immunohistochemical (positive estrogen receptor). CK7.

guishing benign from malignant masses of the spleen (9) however it is preferable to obtain a tissue diagnosis for confirmation. As a highly vascular organ, the spleen is often considered an inappropriate target for fine-





**Fig. 4 -** Neoplastic cells shown by immunohistochemical (negative progesterone receptor). CK20.



**Fig. 5 -** Representative section of ovary stained with hematoxylin and eosin (20X) demonstrating morphology irregular nests of large anaplastic cells were arranged in an alveolar or duct like structure with a large nucleus.

needle aspiration (FNA) due to the potential risk of bleeding. Nevertheless, Cavanna et al reported a series of 160 patients who underwent biopsy of the splenic mass by FNA with an overall accuracy rate of 98.1% and with no complications, showing that the technique is safe and effective (10). Normally, the presence of splenic metastasis in a patient with widespread disseminated disease carries no importance due to their grave prognosis. However, isolated splenic metastasis like in our patient points to a favorable prognosis. Today, splenectomy provides a possible means of radical treatment in patients with isolated splenic metastases; it should be decided with caution as a splenic metastatic lesion which is supposed to be “isolated” sometimes may represent an initial clinical manifestation of systemic metastases at multiple sites. Splenectomy decreases chances of spread of the tumor to distal areas from the

spleen and provides the potential for cure or extended survival (11). Splenectomy for metastatic splenic lesions is generally indicated also to prevent complications such as splenic vein thrombosis, painful splenomegaly, and splenic rupture. In a review of 13 cases of splenic metastasis from lung carcinoma, Ando et al. report that out of 6 patients who did not undergo splenectomy, 4 (67%) went on to have splenic rupture with associated poor outcomes (12). Laparoscopic splenectomy (LS) has become the standard treatment for benign and malignant haematological disorders requiring splenectomy (5). However, there is a lack of evidence for the use of LS in the management of isolated malignant tumors of the spleen, most likely due to the rarity of the condition. The generic benefits of a laparoscopic approach to abdominal pathology apply to splenic surgery with a reduction in wound morbidity, shorter hospital stay and recovery times, and improved quality of life. The advantage of a laparoscopic approach is particularly beneficial in cases of malignancy as the associated shorter recovery times allow an earlier introduction of chemotherapeutic agents. Makrin et al. report their experience with LS in the treatment of 28 isolated splenic tumors and advocate its use in most cases of splenectomy for solid tumors, except in the case of substantial splenomegaly (13). All 28 cases were treated successfully with no postoperative mortality. However, 4 cases required conversion to an open procedure to allow removal of an enlarged spleen. In cases where an enlarged spleen is encountered, a hand-assisted laparoscopic approach can also be employed to allow easier mobilization of the spleen and resection of adjacent organs or tissues where needed (14). Typically the tumors from the female genital tract are CK7, CA-125 positive and CK20 negative (15-17). Our patient had a similar immunohistochemical profile. Splenic metastases have 3 major macroscopic patterns: macronodular, micronodular and diffuse (18). The cancer lesions usually affect the upper or lower pole, the hilum of the spleen and rarely infiltrate the capsule (19). Capsular metastasis is usually due to disseminated disease and commonly from breast, ovarian or melanoma malignancies (2). An interesting fact about solitary splenic metastasis is that they characteristically present after a period of clinical latency; the literature describes cases with a range of presentation times for relapse from 11 months to 120 months with a mean time of 34.8 months. This phenomenon has been postulated to be due to growth of early blood borne disseminated cancer cells within the spleen (2).

## Conclusion

In conclusion, although metastatic involvement of the spleen from solid tumor is rare, it is still a potential site

for disease asylum. The reported cases are increasing due to advancements in imaging modalities and more vigilant patient follow-up.

These patients need prolonged follow-up with serial imaging to identify recurrence because of long clinical latency after primary tumor's surgery and that the patients remain asymptomatic until the tumor creates complications.

Once the lesion is diagnosed, splenectomy followed

by adjuvant chemotherapy is the treatment of choice. In addition it is important to stress that laparoscopic splenectomy is a safe alternative to open resection in the treatment of solid organ tumors involving the spleen (20) when performed by experienced surgeons because it is possible have diagnosis and curative act with mini-invasive approach. In conclusion, our patient has been disease-free for nearly one year after splenectomy with a good performance status.

## References

1. Lam KY, Tang V. Metastatic tumors to the spleen: a 25-year clinicopathologic study. *Arch Pathol Lab Med*. 2000;124:526-530 [PMID: 10747308].
2. Comp  rat E, Bardier-Dupas A, Camparo P, Capron F, Charlotte F. Splenic metastases clinicopathologic presentation, differential diagnosis, and pathogenesis. *Arch Pathol Lab Med*. 2007;131:965-969.
3. Piura E, Piura B. Splenic metastases from female genital tract malignancies. *Harefuah*. 2010;149:315-320. 335, 334.
4. Adnan Arif, Zain Ul Abideen, [...], and Asif Zafar Malik . Metastatic involvement of the spleen by endometrial adenocarcinoma; a rare asylum for a common malignancy: a case report *BMC Res Notes*. 2013;6:476.
5. Sharma D, Shukla VK. Laparoscopic splenectomy 16 years since delaitre with review of current literature. *Laparoscopy Endoscopy & Percutaneous Techniques*. 2009;19(3):190-194.
6. Yi-Ping Zhu, Yi-Ping Mou, [...], and Guan-Yu Wang. Isolated splenic metastases from gastric carcinoma: A case report and literature review. *World J Gastroenterol*. 2013 August 21;19(31):5199-5203.
7. La Fianza A, Madonia L. Splenic metastases in gynaecologic cancer: clinical considerations, US, and CT diagnostic results. *Radiol Med*. 2003;106:36-43.
8. Opocher E, Santambrogio R, Bianchi P, Cioffi U, De Simone M, Vellini S, Montorsi M. Isolated splenic metastasis from gastric carcinoma: value of CEA and CA 19-9 in early diagnosis: report of two cases. *Am J Clin Oncol*. 2000;23:579-580 [PMID: 11202800 DOI: 10.1097/00000421-200012000-00009].
9. Metser U, Miller E, Kessler A, Lerman H, Lievshitz G, Oren R, Even-Sapir E. Solid splenic masses: evaluation with 18F-FDG PET/CT. *J Nucl Med*. 2005;46:52-59 [PMID: 15632034 DOI:10.1053/j.sult.2006.06.005].
10. Cavanna L, Lazzaro A, Vallisa D, Civardi G, Artioli F. Role of image-guided fine-needle aspiration biopsy in the management of patients with splenic metastasis. *World J Surg Oncol*. 2007;5:13 [PMID: 17274814 DOI: 10.1186/1477-7819-5-13].
11. Piura B, Rabinovich A, Apel-Sarid L, Shaco-Levy R. Splenic metastasis from endometrial carcinoma: report of a case and review of literature. *Arch Gynecol Obstet*. 2009;280:1001-1006.
12. Ando K, Kaneko N, Yi L, et al. Splenic metastasis of lung cancer. *Nihon Koky  uki Gakkai zasshi*. 2009;47(7):581-584.
13. Makrin V, Avital S, White I, Sagie B, Szold A. Laparoscopic splenectomy for solitary splenic tumors. *Surgical Endoscopy and Other Interventional Techniques*. 2008;22(9):2009-2012.
14. Yano H, Nakano Y, Tono T, et al. Hand-assisted laparoscopic splenectomy for splenic tumors. *Digestive Surgery*. 2004;21(3):215-222.
15. Lagendijk JH, Mullink H, van Diest PJ, Meijer GA, Meijer CJ. Immunohistochemical differentiation between primary adenocarcinomas of the ovary and ovarian metastases of colonic and breast origin. Comparison between a statistical and an intuitive approach. *J Clin Pathol*. 1999;52:283-290.
16. Lagendijk JH, Mullink H, Van Diest PJ, Meijer GA, Meijer CJ. Tracing the origin of adenocarcinomas with unknown primary using immunohistochemistry: differential diagnosis between colonic and ovarian carcinomas as primary sites. *Hum Pathol*. 1998;29:491-497.
17. Albarracin CT, Jafri J, Montag AG, Hart J, Kuan SF. Differential expression of MUC2 and MUC5AC mucin genes in primary ovarian and metastatic colonic carcinoma. *Hum Pathol*. 2000;31:672-677.
18. Berge T. Splenic metastases: frequencies and patterns. *Acta Pathol Microbiol Scand*. 1974;82:499-506.
19. Zhang ZX, Fang Z, Ye JP, Tao C, Yi M, Lu H. Diagnosis and clinicopathologic features of metastatic carcinoma to the spleen. *Chin J Surg*. 2002;40:585-588.
20. Balmforth D. et al. Laparoscopic Management for Carcinoid Metastasis to the Spleen. *HPB Surg*. 2011;2011:346507.