

Seat belt syndrome, a new pattern of injury in developing countries. Case report and review of literature*

M. TORBA¹, S. HIJAZI², A. GJATA³, S. BUCI³, R. MADANI¹, K. SUBASHI¹

SUMMARY: Seat belt syndrome, a new pattern of injury in developing countries. Case report and review of literature.

M. TORBA, S. HIJAZI, A. GJATA, S. BUCI, R. MADANI, K. SUBASHI

Background. Classically, seat belt syndrome appears with seat belt marks on the body, bowel perforations, and lumbar spine fractures. However the symptoms are not limited to those previously mentioned, and organ damage can vary greatly.

Case report. A 34-year-old female passenger, was admitted to our hospital after a motor vehicle crash. The physical examination revealed an ecchymosis across the chest, a transverse abdominal abrasion, and

fractures of the left humerus, the left femur, and the right tibia. The laparotomy revealed multiple jejunal perforations, such as a seromuscular tear of the hepatic and splenic flexure of the colon and a defect of the abdominal wall. The primary suture of jejunum, resection with end to end anastomosis of jejunum, suture of a seromuscular tear of the colon, and primary repair of the abdominal wall defect procedures were performed. On the fifth day, the patient underwent osteosynthesis.

Conclusion. The abdominal pain in the polytraumatized patients with seat belt syndrome may be dominated by the pain caused by extra-abdominal injuries. The presence of a seat belt mark across the abdomen increases suspicion of abdominal injuries.

KEY WORDS: Seat belt syndrome - Motor vehicle crash - Lumbar spine fracture - Injuries.

Introduction

Classically, seat belt syndrome appears with seat belt marks on the body, bowel perforations, and lumbar spine fractures; but the spectrum of organs damaged by seat belts include many possible combinations (1-3). Seat belt syndrome is a result of the pressure that the belt causes along its course. Mechanical forces from seat belt cause different types of injuries in a car accident, so the types of signs and symptoms may differ (4).

In our country, this type of injury was unknown until the 1990's. This gap was related to the lack of seat belts in motor vehicles, the small number of motor vehicles

on the road, and poor road infrastructure for driving at high speeds. With the democratic changes that occurred in 1992 and the introduction of western motor vehicles, vehicles travelling at high-speeds caused an increase in fatalities from car accidents. According to the state police reports, in our country there were over 897 car accidents per year with 407 victims, 1066 injured with temporary disabilities, and 99 injured with a permanent disability. We have 110 deaths per million inhabitants every year due to traffic accidents, while Europe has only 65 deaths per million inhabitants every year. However, the use of seat belt by citizens remain rare in general. In 1998, the government declared the use of seat belts in traffic mandatory. After this law was enacted, the first cases of seat belt syndrome began. Unfortunately, the level of compliance with safety rules while driving is still low in our country. Even though nowadays, injuries and deaths related to road accidents are a major problem worldwide.

A recent perspective study reported that the use of seat belts while driving reduced the severity of injury, length of hospital stay, and the number of operations needed on the injured patients (5). The use of seat belts is strongly recommended for pregnant women (6). Correct use of seat belts lead to the reduction of maternal and fetal morbidity and mortality. Further legal enfor-

¹ Service of General Surgery, Trauma University Hospital, Lapraque, Tirana, Albania

² Department of Urology, Göttingen University, Göttingen, Germany

³ Department of Surgery, UHC "Mother Teresa", Tirana, Albania

* Presented at the "16th Annual Meeting of the European Society of Surgery", November 22, 2012, Istanbul, Turkey

Corresponding Author: Myftar Torba, e-mail: myftartorba@yahoo.com

© Copyright 2014, CIC Edizioni Internazionali, Roma

cement of seat belt laws are absolutely necessary in order to reduce the risk of serious injury in traffic accidents (7).

Case report

A 34-year-old female passenger, who was wearing her seat belt correctly, was involved in a car accident. The patient was hemodynamic and respiratory unstable when admitted to the local hospital. One hour later after first aid was given, the patient was sent to receive specialized treatment in our hospital due to her deteriorating condition. She had mild alterations in consciousness

(Glasgow Coma Scale score of 13-14) and complained of severe pain throughout the body. The patient was hemodynamically unstable with a blood pressure of 85/55 mmHg, heart rate of 120 bpm, respiratory rate of 30 breaths / min, and body temperature of 36.1°C.

The blood test revealed a red blood cell count of 2.4 million/mm³, a hemoglobin level of 7.2 g/dl, hematocrit 24.4%, and leukocytosis (22,000/mm³). The Injury Severity Score (ISS) was on a value scale of 50. Clinical examination revealed an abrasion on the chest wall and cross-abdominal, abdominal guarding, disability of both the lower extremity and the upper left extremity (Figure 1 a, b, c, d). A focused abdominal sonography for trauma (FAST) revealed free fluid in abdominal cavity.

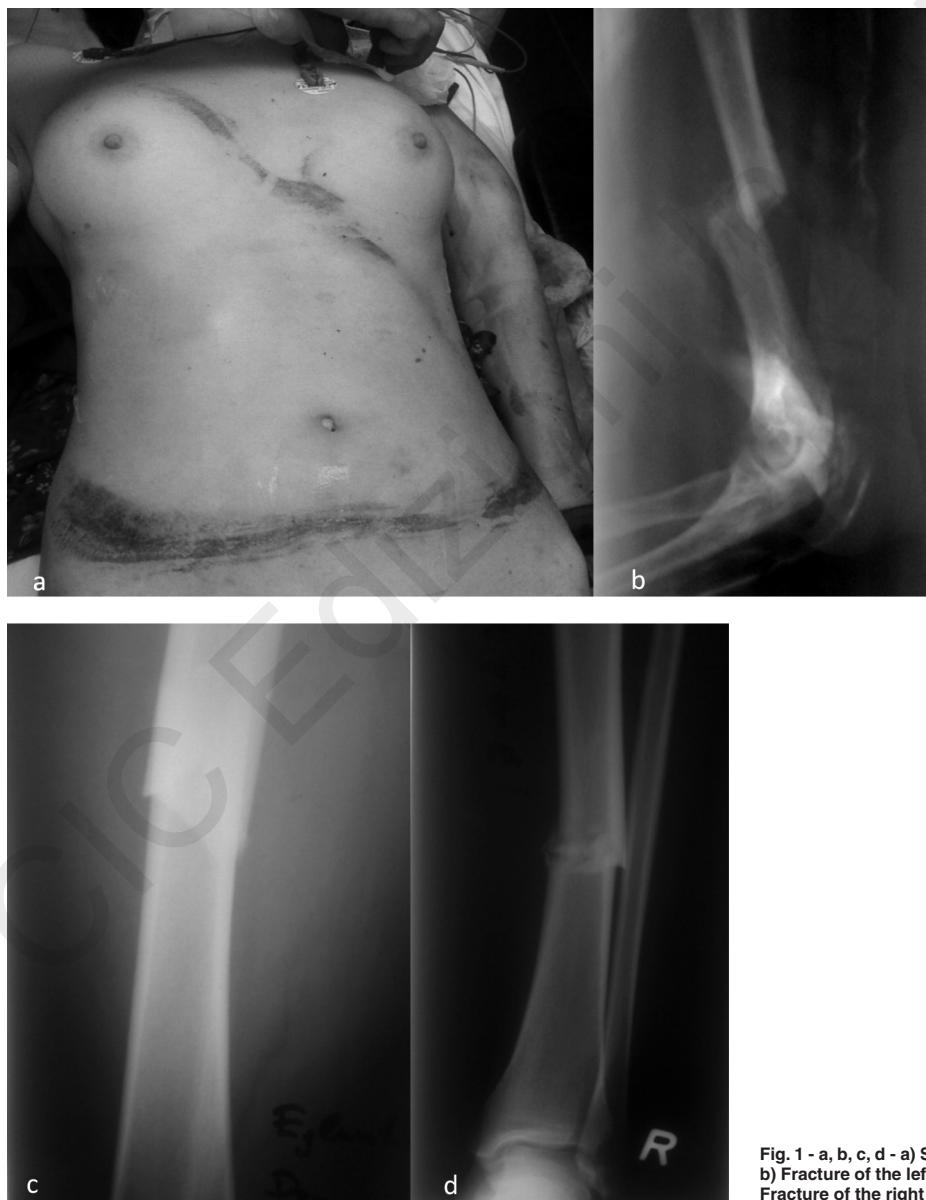

Fig. 1 - a, b, c, d - a) Seat belt signs in the thorax and abdomen. b) Fracture of the left humerus. c) Fracture of the left femur. d) Fracture of the right tibia.

The chest x-ray was normal, while X-rays of the extremities showed a fracture of the left humerus, fracture of the left femur, and fracture of the right tibia.

The patient underwent an immediate exploratory laparotomy. It showed multiple jejunal perforations, a seromuscular tear of the hepatic and splenic flexures of the colon, as well as a traumatic hernia of the anterior inferior abdominal wall (Fig. 2 a, b). We performed primary closures of the jejunum perforations, a segmental resection with end to end anastomosis of jejunum, a sero-

muscular suture of the colon, and a primary repair of the abdominal wall defect. During the surgical intervention, the patient was given 4 units of blood, fresh frozen plasma, and a crystalloid transfusion (1:1:1). She was treated for 5 days with empirical broad spectrum antibiotics (amikacin, ceftazidime, metronidazole). The immediate postoperative period was uneventful. On the fifth day, the patient underwent osteosynthesis (Fig. 3 a, b, c). After the 15th postoperative day, the patient was discharged from the hospital.

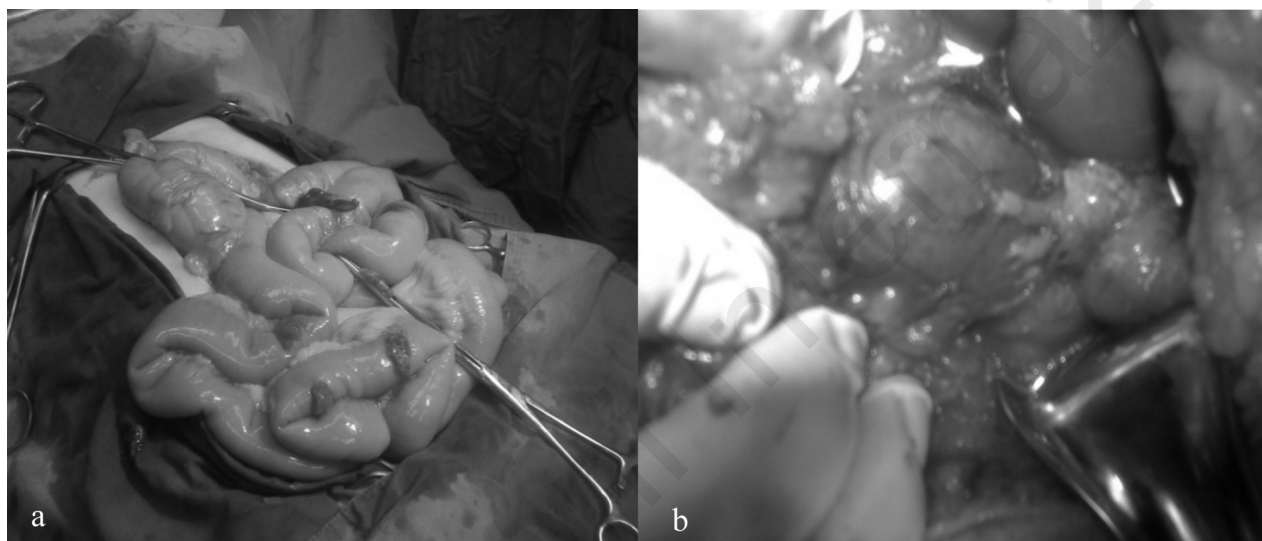


Fig. 2 a, b - Intraoperative findings. a) Multiple jejunal perforation; b) Seromuscular tear of the splenic flexure.

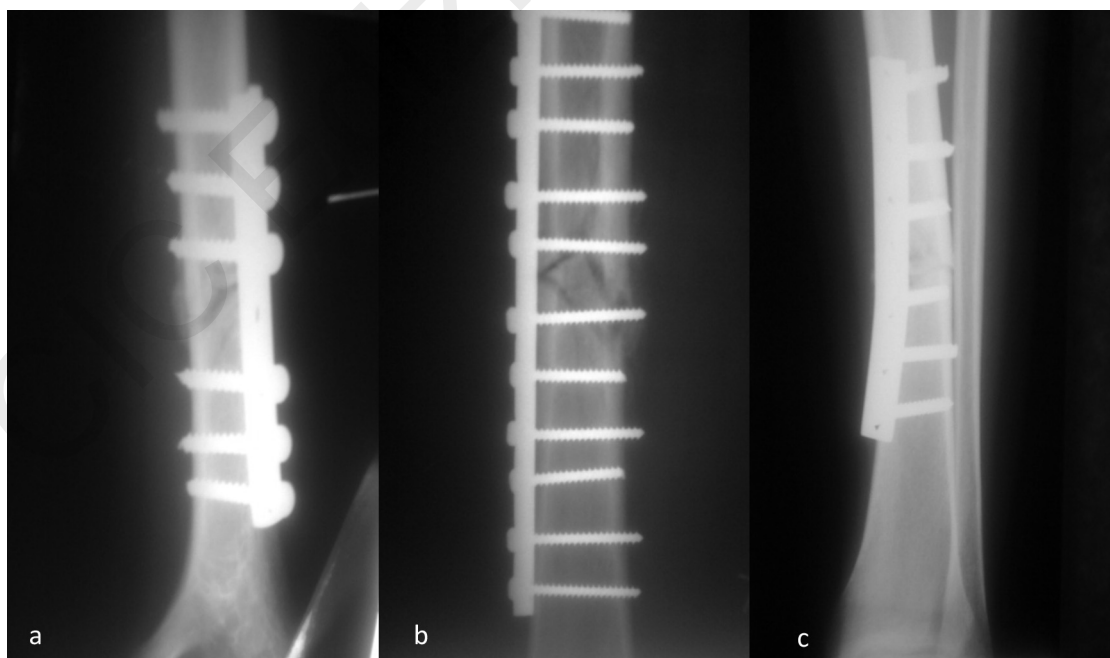


Fig. 3 a, b, c - Osteosynthesis. a) Left humerus; b) left femur; c) right tibia.

Discussion

The clinical presentation of seat belt syndrome is often non-specific, which leads to delays in diagnosis and therapy. Typical symptoms include abrasions on the chest and on the abdomen as a seat belt mark. The presence of a seat belt mark on the patient's body indicates that the possibility of injury to the chest and abdomen to be four and eight times more respectively than without these signs (8).

The symptoms associated with this syndrome depend on the injured organ. In the case where the hollow organs are injured peritoneal signs may appear. While in the case of parenchymal or vascular injuries, hypovolemic signs dominate the clinical picture. Peritoneal signs may be hidden by the presence of rectus muscle spasm or by the presence of serious extraperitoneal injury. Repeated examinations of the abdomen are essential since the possibility exists that the peritoneal symptoms can be hidden, especially with children when they are hospitalized (9).

Depending on the clinical condition of the patient, chest and abdominal X-rays, FAST, and computed tomography scans (CT) with contrast agents are recommended. In suspected cases, repeated CT scans are recommended after 8 hours. This can help in the early diagnosis of intestinal injuries (10). The diagnosis of hollow organ injuries in children is often difficult, even with CT scans. Only a strict clinical follow-up may help to

diagnose children who have sustained these injuries. Based on clinical data, radiological findings, and laboratory data, have to decide on the strategy of treatment.

The treatment of seat belt syndrome is not standard. Treatment is dependent on the injured organ, as well as the general condition of the patient, and can range from conservative to surgical. Hollow organ injuries require mostly surgical intervention, while parenchymal and vascular injuries can be treated conservatively or surgically. The prognosis is mainly related with the injured organ and its degree of damage.

Conclusion

The diversity of the organ injuries due to seat belts include all possible combinations. The attending physician must take into account the full spectrum of injuries that are usually encountered in this syndrome, in particular if the patient has seat belt marks. The abdominal pain in polytrauma patients due to seat belt syndrome may be hidden by pain caused by extra-abdominal injuries. The presence of seat belt marks on the body must be regarded with suspicion, meriting further examination for intra-abdominal injuries.

Disclosure

The Authors declare they have no conflict of interest.

References

1. Tanaka T, Kawashita Y, Kawahara D, et al. Complete dissection of a hepatic segment after blunt abdominal injury successfully treated by anatomical hepatic lobectomy: report of a case. *Case Rep Gastroenterol.* 2011;5:125-31.
2. Gill SS, Dierking JM, Nguyen KT, et al. Seatbelt injury causing perforation of the cervical esophagus: a case report and review of the literature. *Am Surg.* 2004;70:32-4.
3. Guanà R, Sangiorgio L, Tessitore P. Traumatic duodenal lesions in children due to two-point seat-belt: the seat-belt syndrome. *Minerva Pediatr.* 2012;64:47-53.
4. Freni L, Barbeta I, Mazzaccaro D, et al. Seat belt injuries of the abdominal aorta in adults. Case report and literature review. *Vasc Endovascular Surg.* 2013;47:138-47.
5. Abu-Zidan FM, Abbas AK, Hefny AF, et al. Effects of seat belt usage on injury pattern and outcome of vehicle occupants after road traffic collisions: prospective study. *World J Surg.* 2012;36:255-9.
6. Motozawa Y, Hitosugi M, Abe T, et al. Effects of seat belts worn by pregnant drivers during low-impact collisions. *Am J Obstet Gynecol.* 2010;203:62.e1-8.
7. Conner KA, Xiang H, Smith GA. The impact of a standard enforcement safety belt law on fatalities and hospital charges in Ohio. *J Safety Res.* 2010;41:17-23.
8. Velmahos GC, Tatevossian R, Demetriades D. The "seat belt mark" sign: a call for increased vigilance among physicians treating victims of motor vehicle accidents. *Am Surg.* 1999;65:181-5.
9. Santschi M, Echavé V, Laflamme S, et al. Seat-belt injuries in children involved in motor vehicle crashes. *Can J Surg.* 2005;48:373-376.
10. Brofman N, Atri M, Hanson JM, et al. Evaluation of bowel and mesenteric blunt trauma with multidetector CT. *Radiographics.* 2006;26:1119-31.