

Rare cases reports of gastrointestinal stromal tumour (GIST)

M. AMENDOLARA^{1,2}, S. RAMUSCELLO¹, A. BROGGIATO¹, A. ANDREOTTI², G. STEVANATO¹,
M. BONFIGLIO¹, M. BERNARDI³, D. PARINI², F. GALEOTTI², M. RIZZO¹

SUMMARY: Rare cases reports of gastrointestinal stromal tumour (GIST).

M. AMENDOLARA, S. RAMUSCELLO, A. BROGGIATO, A. ANDREOTTI, G. STEVANATO, M. BONFIGLIO, M. BERNARDI, D. PARINI, F. GALEOTTI, M. RIZZO

The GISTs are rare tumours but even rarer is the localization in some districts. We reported two GISTs of the duodenum, two of the

omentum and peritoneum, one of the rectum and one of a Meckel's diverticulum. These exceptional locations are confirmed by the relative difficult diagnosis, obtained in some cases only by the surgical treatment despite the CT and MR. The endoscopy is useful in hemorrhagic and duodenum forms, only for the diagnosis and for the control of blood loss. Surgical treatment in all cases was decisive without the need to make use of adjuvant therapy, with positive long-term results, which excluded the disappearance of relapses or secondary lesions.

KEY WORDS: Gastrointestinal Stromal Tumour (GIST) - Wedge Resection (WR) - Cajal's cells.

Introduction

Gastrointestinal stromal tumours (GISTs) are the most common mesenchymal tumours of the gastrointestinal tract, and represent the 0,1-3% of all the gastrointestinal tumours (1).

Their localizations vary; the most frequent ones are in the stomach (60%) and small bowel (25%) (2) more rarely in the duodenum (5%), omentum and peritoneum (3), outstanding is the localization in the Meckel's diverticulum (4).

The GIST is clinically manifested by gastrointestinal haemorrhage, with melena or hematemesis or with chronic anaemia, if the diameter exceeds 2 cm (5), while if the size is smaller, the clinical sign is characterized by a painful chronic or it is totally asymptomatic.

The Authors have a clinical review of some rare forms of GIST observed.

Case reports

N.R. ♀ Yrs 51 admitted in Gynaecology Department for pain to the hipogastrium for ovarian dermoid cyst; the CT and MR indicate an expansive lesion of 8 cm wide, hypodense, with dense internal nodules (Figure 1).

The laparoscopy, confirmed the cystic lesion, mobile, a smooth surface in contact with the ileum antimesenteric margin, with Ø of 0,4 cm. The difficult interpretation, at laparoscopic vision, indicated the laparotomic exploration and ileal resection for the Meckel's diverticulum; the macroscopical examination noted multiple vegetations of reddish colour, with hemorrhagic areas.

The histological diagnosis reported a GIST to spindle cells, epithelioid, with widespread cellular atypia and mitotic activity (HPFs) medium-low. Ten days after admission, the patient was discharged in good hemodynamic compensation (Figure 2).

We performed a one-year cycle of adjuvant therapy with imatinib despite the low mitotic index, in relation to the diffusion observed at the surgical treatment. After one year CT control, showed no recurrence.

O.A. ♀ Yrs 26 hospitalized for occasional diagnosis

¹ U.O.A. General Surgery (Director: S. Ramuscello), Surgery Department (Director: M. Rizzo), Chioggia, Italy

² U.O.C. Rovigo General Surgery (Director: F. Galeotti), Surgery Department (Director: F. Galeotti), Rovigo, Italy

³ U.O.A. Pathological Anatomy (Director: M. Zucchelli), Chioggia, Italy

Corresponding author: M. Amendolara, e-mail: drmauroa@gmail.com

of extramucosal neoformation of the mucosa of the rectum showed at colonoscopy; the MR confirmed a neoformation of the recto-vaginal septum, cleavable from the rectum, the vagina and the perineal muscular area. The surgical treatment was performed with endoscopic exploration of the rectal mucosa, and removal of all the tumour, with incision of the mucosa. The tumour was in the regular margin with integrity of the recto-vaginal septum. The histological diagnosis confirmed a GIST of rectal mucosa of \varnothing 3 cm, with low mitotic index. The instrumental follow-up, with radiological control, confirmed the absence of recurrence and secondary lesions of the disease.

R.L. ♂ Yrs 64 hospitalized for pain in the epigastric and right side, the CT of the abdomen showed an expansive lesion between the stomach and the pancreas of 8cm diameter with a moderate metabolic activity, to the PET. The laparoscopic exploration confirmed the radiological signs of the neoformation deployed in the retrocavity of the epiploon.

In view of the localization and of the size of the tumour we performed a laparotomy and excision with mechanical WR. The histological result reported a GIST well encapsulated, with widespread calcific foci and mitotic index <1750 HPFS, from omentum. The subsequent follow-up did not require adjuvant therapy, but only instrumental follow-up.

M.R. ♀ Yrs 69 admitted for abdominal pain associated to epigastria chronic swelling, and chronic anaemia; the CT showed the presence of a neoformation with \varnothing of 30-40 cm to the omentum and peritoneum with local infiltration of the gastric serosa. The surgical procedure confirmed the radiological diagnosis, so a surgical excision of the tumour was performed, along with the WR of the anterior wall of the stomach affected by cancer: histology reported a spindle cell and epithelioid GIST with omental infiltration of the muscular wall of the gastric body and low mitotic index (<1 x 50 HPFS). The PET, performed after six months, didn't reveal areas of abdominal accumulation, while the CT didn't show any repetitive injury or secondary; 4 years after surgical treatment, the patient is free from secondary cancers.

P.V. ♀ Yrs 77 admitted for hematemesis and melena, the gastroscopy showed a bloody lesion to the second duodenal portion, which proceeded to local infiltration of adrenaline with partial stop of the bleeding (Figure 3); the CT confirmed the lesion at the II portion of the duodenum with \varnothing of 6 cm, bleeding; so selective angiography was performed, with evidence of abnormal spraying vascular from a branch of right colic and some peripheral branches of gastroduodenal; we performed a pancreatic artery embolization, which further reduced bleeding. How-

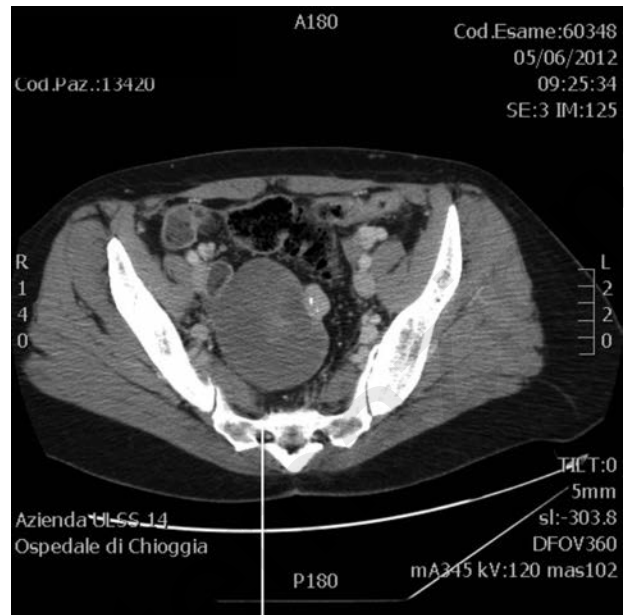


Fig. 1 - CT Meckel's GIST.

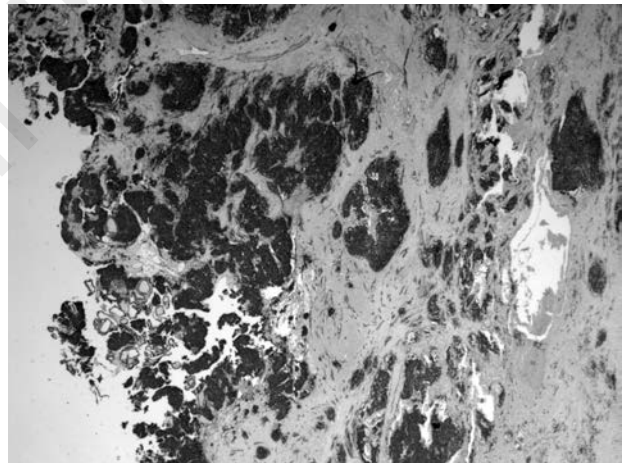


Fig. 2 - Histological report Meckel's GIST.

ever, the worsening of anaemia, posed indication to surgical treatment with a duodenal resection and anastomosis by Roux-y duodenum-jejunostomy; the patient was discharged on the 6th day. The histology reported a GIST of the duodenum, without mitosis, then for the low risk needed only an instrumental follow-up.

N.S. ♀ Yrs 80 patient hospitalized for asthenia and chronic anaemia; the CT showed a lesion of the II front wall portion of the duodenum by 2 cm of \varnothing , confirmed at the gastroscopy which revealed vegetating lesion; the biopsy reported a GIST. The patient was monitored from the instrumental standpoint with serial endoscopy, because the patient declined the consent to the surgical treatment.

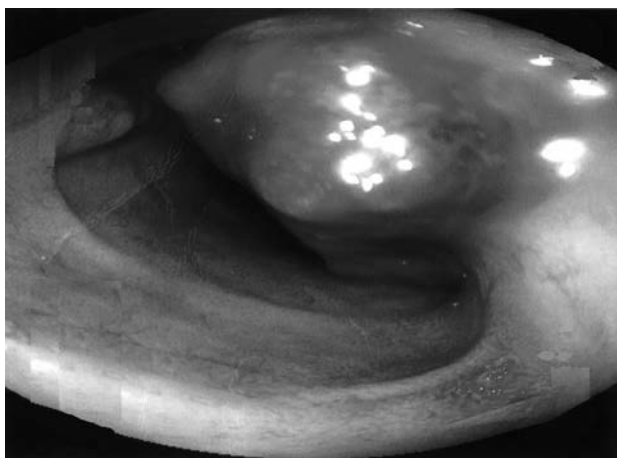


Fig. 3 - Endoscopic vision the GIST of duodenum.

Results

The rare forms of GIST observed and reported revealed a benign aspect of lesions, confirmed by low to medium mitosis index, with instrumental follow-up only and remote execution of CT and MR, resulting in all cases negative for recurrence of pathology. The GIST of Meckel requested, for the development of the clinical signs of the disease a one-year adjuvant treatment with imatinib. The surgical resection in all patient surgically treated was resolute; the use of laparoscopy was necessary only in two cases where the preoperative diagnosis was difficult to interpret, while in a GIST of duodenum, the patient preferred a conservative treatment with following controls.

Discussion

GIST is a cancer of the gastrointestinal tract that originates from multipotential stromal cells of Cajal (pacemaker cell of gastrointestinal tract) that can develop and differentiate into smooth muscle cells or neurons that control gastrointestinal motility (1, 5, 6). These tumours represent a percentage of 1% of all the gastrointestinal system cancers, with localization in the stomach (70%) and the small intestine (25%), while the involvement of the rectum is more rare (10%) (7), as well as more rarely seen at omentum and peritoneum (5%) only 54, cases have been reported in the literature (8-10). The GISTs of Meckel's diverticulum are extremely rare, especially if you consider that only 2% of the population has this kind of diverticulum (4, 11, 12) as confirmed by autoptic studies, with a percentage that varies between 0,4 and 4, 5% (13).

The GIST of the duodenum is rarer than the one on

the other side of the small intestine (3-5%) and has been characterized by the high risk of bleeding (14).

The actual rarity of some GIST forms has been confirmed in our experience, based on a total of 40 GIST cases observed in the last four years: 18 cases (45%) interested the stomach; 10 cases (25%) the small intestine, while the data relating to omentum and duodenum differed from the literature (3-5%), with higher percentage, respectively, 8% and 6%.

GISTs of the stomach and small intestine appear between 60 and 70 years, while the duodenum appear to be involved at the age of 80 years, contrarily to the peritoneal lesions which appear at early age around the V-VI decade.

The common and frequent symptoms of GIST vary: asthenia, weight loss, chronic anaemia or asymptomatic as in 35% of GIST of the stomach (15) and is often identified to the surgical procedure (33%) (16). The most frequent symptom is gastro-intestinal bleeding related to the size of the tumour, with diameter of 2 cm and ulceration of the gastric-duodenal mucosa (2, 17), while at the Meckel's diverticulum it is due to ectopic localization of the gastric mucosa (18). The cause of bleeding is determined by a superficial necrosis of the mucosa and relative ulceration for the development of GIST at the sub mucosal which determines compression of the surface layers (5, 14). The growth of the tumour is progressive, circumscribed, well encapsulated (8), sometimes the symptoms are of secondary liver metastases to the liver, to the lymphatic infiltration and they are diagnosed with casual CT, MR or during surgical treatment, for the primary lesion (6).

The GISTs with gastrointestinal bleeding, more obviously to the duodenum and stomach are diagnosed at the endoscopy, while lesions in the small intestine are identified by conventional radiology of digestive tract, or better by CT, MR or PET, the last one for the recognition of lesions distant from the primary localization (3). The limits of the endoscopy are due to the development of neoplasia in the submucosa wall which elevate the risk of bleeding during the biopsy because of a difficult control, so the performance of the endoscopic test with biopsy is only a preliminary step to surgical treatment (19).

The selective angiography allows a localization of bleeding and the simultaneous embolization of the vessels that causes hemorrhagic damage (8, 11). The angiography is mainly indicated in GIST which originates by duodenum, jejunum and Meckel's diverticulum because the embolization reduces the blood supply, with slowing of tumour growth, with minimal bleeding risks. The preoperative angiography in the case of tumour of the duodenum reported, allowed the embolization arch pancreatic duodenal, improvement of anaemia and reducing the size of GIST with a safety surgical treatment.

The FNAB provides a histological diagnostic frame-

work for the research of the encapsulated margins of neoplastic masse, for an adequate adjuvant therapy: it must be carried out with echo or radio-guided technique (3, 7). The X ray is useful in cases of bleeding duodenal tumour localized near the papilla that may be confused with hemobilia (14).

The surgical treatment varies depending on the kind of tumor. The purpose of the surgery is to keep harmless the capsule that covers the GIST, even if it is in an advanced stage or with the secondary lesions or peritoneal diffusion (3, 19). Surgical therapy may be limited to small resections, wedge resections (WR) or enlarged. The WR is reserved for cases with active bleeding or in large GIST to reduce the growth; the laparoscopic technique of the gastric GIST allows a transgastric resection or an extra mucosal excision (20). Laparoscopy is indicated for GIST smaller than 8 cm (3), although with larger demolitions is possible to obtain better results and a more long-term survival (5).

The GIST of the duodenum may only need WR in the absence of the lymph node lesions, or a wide resection like the duodenocephalopancreasectomy with or without gastrectomy in block (2). The WR differs according to the site of the lesion, the longitudinal WR is reserved for lesions development of the wall in the I-II-III part, the involvement of the papilla involves resection with Roux γ - duodenojejunostomy (21), the treatment of GIST of omentum is not standard and should be modulated in relation to the clinical evolution of the disease. According to our experience and to our studies of the literature, the validity of treatment for the GIST with WR without recourse to subsequent adjuvant therapy is confirmed (22).

The minimally invasive surgery treatment has a diagnostic role for GIST, especially for the rare forms with difficulty preoperative evaluation, also for gastric cancer of the anterior wall with encapsulated lesion that ensures a complete mechanical resection maintaining the margins of oncological safety (23). Although the role of technology is still controversial for the presence of any recurrence at the point of insertion of the trocar (24). The laparoscopic treatment of GIST of Meckel's diverticulum presents limitations linked to the risk of residuals of the neoplastic lesion to the ectopic mucosa or to the base of a diverticulum.

The laparoscopy is indicated in cases in which the Meckel is extended in length because the GIST is localized to the distal extremities, while for diverticula with more reduced dimensions is preferred resection with open technique (25).

The adjuvant treatment of GIST is related to mitotic index; if the HPFs are low or medium, between 2-50, a therapeutic adjuvant support is not required. The evaluation of the mitotic index expresses the degree of malignancy of the tumour, reported in HPFs (High-pow-

er fields), considering that the range 0-4 mitosis in 50 HPFs, while a number between 2-4 expresses an index of intermediate malignancy (16) that allows a follow-up observation with CT or CR. The adjuvant treatment is imposed by the use of KIT/PDGFR tyrosine kinase INHIBITOR (imatinib) for GIST with secondary or metastatic lesions that warrant a partial or complete remission of the tumour (1). We performed exclusively the adjuvant treatment in GIST of Meckel not so much for the index of mitosis (medium-low), but for a modest neoplastic diffusion of the abdominal washing. The number of mitosis is not the single index capable of expressing the level of malignancy but it must be considered also in relation to the size, in order to be able to define the GIST as: *low risk*, for the presence of a low number of mitoses < 5 and diameter < 2 cm; *medium risk*, with diameter between 5 and 2 cm, but with mitosis between 6-10 HPFs, or in case of diameter between 5-10 cm and HPFs < 5, at *high risk* of malignancy; GIST with diameter > 5 cm and mitosis > 5 HPFs or eventually all tumours with diameters 10 cm and mitosis > 10 HPFs, regardless of their contemporaneity, also because the prognosis is greatly dictated the primary epithelial cancer rather than the GIST's adjuvant therapy should be focused primarily on the more aggressive disease.

Conclusion

The gastric and jejunum GIST are not rare, while the localization to the duodenum, the omentum and peritoneum rarer and the discovery of the Meckel's diverticulum is an exceptional feedback. The diagnosis is radiological with CT and MR; the endoscopy is useful for gastric and duodenal localizations.

The biopsy should be reserved only to low risk bleeding cases, and should be performed in a protected environment or, in the GIST with encapsulated margins, under the CT guide in order to avoid secondary diffusions. The hemorrhagic lesions need a selective angiography which has proven to be helpful for diagnostic identification of the hemorrhagic site, and for the therapeutic one, because embolization slows the growth of the tumour so as to allow the surgical treatment in more suitable conditions.

The malignancy index of this rare typed of GIST resulted medium or low with the mitosis index of 5 HPFs. In all cases described the surgical treatment has proven to be resolute and radical, with only an instrumental follow-up, except for the GIST of the Meckel's diverticulum for which it was considered more appropriate a 1 year adjuvant treatment with imatinib, and the term results confirmed the validity of the therapeutic approach adopted.

References

1. Miettinen M, Lasota J. Gastrointestinal stromal tumors. Review on morphology, molecular pathology, prognosis and differential diagnosis. *Arch Pathol Med.* 2006;130:1466-78.
2. Hoepfner J, Kulemann B, Marianovic G, Bronsert P, Hopt UT. Limited resection for duodenal gastrointestinal stromal tumors: surgical management and clinical outcome. *World J Gastrointestinal Surg.* 2013;27:5(2):16-21.
3. Roggin KK, Posner MC. Modern treatment of gastric- gastrointestinal stromal tumors. *World J Gastroenterology Cl.* 2012, 14;18(46):6720-28.
4. Chandramohan K, Agarwal M, Grjara G, Gatti RC. Gastrointestinal stromal tumours in Meckel's diverticulum. *World J Surg Oncol.* 2007;5:50-55.
5. Connolly EM, Gaffney E, Reynolds JV. Gastrointestinal stromal tumours. *Br J Surg.* 2003;90:1178-1186.
6. De Matteo RP, Lewis J-J, Leung D, Mudan SS, Woddruff JM, Brennan MF. Two hundred gastrointestinal stromal tumours, recurrence patterns and prognostic factors for survival. *Am Surg.* 2000;23:51-58.
7. Demetri GD, Von Mehren, Antonescu CR, De Matteo RP, Ganjoo KN, Pisters PW. NCCN Task force report: update on the management of patients with gastrointestinal tumors. *J Natl Compr Canc New.* 2010;8-Suppl. 21-41.
8. Fagkrezos D, Toulonmis Z, Gramilla M, Pemidis C, Paparaskas K, Triantopoulou: Extra-gastrointestinal stromal tumor of omentum: a rare case report and review of the literature. *Rare Tumors.* 2012;26:43-44.
9. Goh BK, Chow PK, Kesavan SM. A simple – institution experience with eight CD 117- positive primary extragastrointestinal stromal tumors: critical appraisal and a comparison with their gastrointestinal counterparts. *J Gastroint Surg.* 2009;13:1094-8.
10. Sukurai S, Hishima T, Takazawa Y. Gastrointestinal stromal tumors and kit-positive mesenchymal cells in the omentum. *Path Int.* 2001;51:524-31.
11. Sharma RK, Jain VK. Emergency surgery for Meckel's diverticulum. *W J Emerg Surg.* 2008;2:27.
12. Hager M, Maier H, Eberwein M, Klingler P. Perforated meckel's diverticulum presenting as a gastrointestinal tumor: a case report. *J Gastrointest Surg.* 2005;9:809-811.
13. Dumper J, Mackenzie S, Mitchell. Complications of Meckel's diverticula in adults. *Can J Surg.* 2006;49:353-7.
14. Lin C, Chang Y, Zhang Y, Zuo Y, Ren R. Small duodenal gastrointestinal stromal tumor presenting with acute bleeding misdiagnosed as hemobilia: Two case reports. *Oncol Lett.* 2012;4:1069-71.
15. Kawanowa K, Sakuma Y, Sakurai S. High incidence of microscopic gastrointestinal tumors in the stomach. *Hum Pathol.* 2006;37:1527-35.
16. Chan CHF, Larigue JC, Mactis V, Fredman LS, Ferri LE. The impact of incidental gastrointestinal tumours on patients undergoing resection of upper gastrointestinal neoplasms. *Can J Surg.* 2012;55:366-70.
17. Hepworth CC, Menzies D, Maston RW. Minimally invasive surgery for posterior gastric stromal tumors. *Surg Endosc.* 2000;14:349-353.
18. Val Loo S, Van Thieleu J, Caols P. Gastrointestinal bleeding caused by GIST of Meckel's diverticulum: a case report. *Acta Chir Belg.* 2010;110:365-366.
19. Gold JS, De Matteo RP. Combined surgical and molecular therapy: the gastrointestinal stromal tumor model. *Am Surg.* 2006;244:176-184.
20. Schubert D, Kuhn R, Nestler G, Kahl S, Ebert MP, Malfettertheiner P, Lippert H, Pross M. Laparoscopic- endoscopic resection upper gastrointestinal tumors. *Dig Dis.* 2005;23:106-112.
21. Goh BK, Chow HS, Oug HS, Wong WK. Gastrointestinal stromal tumor involving the second and third portion of the duodenum treatment by partial duodenotomy and Roux-en-duodenoduodenostomy. *J Surg Oncol.* 2005;91:273-275.
22. Raynoso D, Trent JC. Neoadjuvant and adjuvant imatinib treatment in gastrointestinal stromal tumor: current status and recent development. *Curr Opin Oncol.* 2010;22:330-5.
23. Otani Y, Ohgami M, Igarushhi N, Kimata M, Kubata T. Laparoscopic wedge resection of gastric submucosal tumors. *Surg Laparosc End Percut Technique.* 2000;10:19-23.
24. Neuhans SJ, Texler M, Hawett PJ, Waston DI. Port-site metastases following laparoscopic surgery. *Br J Surg.* 1968;85:735-741.
25. Varcoe RH, Wong SW, Taylor CF, Newstead GL. Diverticulectomy is inadequate treatment for short Meckel's diverticulum with heterotopic mucosa. *ANZ J. Surg.* 2004;74(10):869-72.