

Totally laparoscopic resection of a very large gastric GIST

G. ANANIA, L. DELLACHIESA, N. FABBRI, L. SCAGLIARINI,
G. FERROCCI, A. PEZZOLI, G. RESTA

SUMMARY: Totally laparoscopic resection of a very large gastric GIST.

G. ANANIA, L. DELLACHIESA, N. FABBRI, L. SCAGLIARINI,
G. FERROCCI, A. PEZZOLI, G. RESTA

Laparoscopic approach was safely performed for the diagnosis and

treatment of the submucosal tumors of the stomach because it is associated with low morbidity, mortality, and sound oncologic outcomes.

However, no report on the long-term safety and efficacy of this surgery for large sized gastric GISTs has been published to date. We present a 63-year-old female case of a large gastric GIST of 19 cm removed by laparoscopic wedge resection.

KEY WORDS: GIST - Stomach - Laparoscopy - Wedge resection.

Introduction

The term of GIST was introduced by Mazur et al. in 1983 in order to indicate a distinct heterogeneous group of mesenchymal neoplasms characterized by spindle or epithelioid cells with varying differentiation. GISTs represent a wide clinical spectrum from benign to highly malignant tumors. Although they may arise throughout the gut, the commonest sites are stomach and small intestine (1).

Recently, the origin of GISTs has been proposed to be the interstitial cell of Cajal, which is the pacemaker cell of the gastrointestinal system. Most GISTs have activating mutations of the c-kit protooncogene (CD117), a transmembrane tyrosine kinase receptor protein, that have been implicated in their tumorigenesis. These mutations lead to constitutive expression of KIT protein. The majority of GISTs are positive for CD117 (94%), CD34 (60%-70%) (2), a hematopoietic progenitor cell antigen, variably positive for smooth-muscle actin, and usually negative for desmin and S100 protein (3).

The preoperative diagnosis of GIST is relatively dif-

ficult to make, endoscopy often failed to detect submucosal and extraluminal GIST, and a biopsy specimen is often negative. Recently, fine-needle aspiration (FNA), performed under the guidance of ultrasound or computed tomography, have been developed as reliable methods to obtain tumor cells, and have allowed the preoperative diagnosis of GIST by histological examinations with immunohistochemistry (4,5).

However, resection of the tumor is generally necessary, from both the diagnostic and the therapeutic aspects. Lymphadenectomy is not necessary, because gastric GISTs rarely metastasize to the lymph nodes (6).

The development of endoscopic stapling devices and the evidence that laparoscopic resection of GISTs is effective with minimal morbidity and no reported mortality (7) has made laparoscopic wedge resection a valid alternative to the conventional open approach. However, there has been controversy regarding tumor size in laparoscopic surgery for gastric GISTs (8). Recent reports show that laparoscopic or laparoscopic-assisted resection may be used for small gastric GISTs (9). However, there is no report on the long-term safety and efficacy of this surgery for large-sized gastric GISTs.

For the treatment of unresectable, metastatic, or recurrent GIST and for the treatment of residual lesions after first-line surgical therapy is indicated Imatinib Mesylate, a signal transduction inhibitor, a new class of anticancer agents targeting tumor-specific molecular abnormalities (10). Imatinib inhibits the growth of GISTs

"S. Anna" University Hospital, Ferrara, Italy

© Copyright 2013, CIC Edizioni Internazionali, Roma

and extends the survival of patients, but complete surgical resection is the only curative treatment of GISTs (11).

However, even for patients whose tumour was completely removed with clear margins there is still a high probability of local recurrence (12). Tumor recurrence has been shown to be dominated primarily by factors of mitotic index, size, and tumor location (gastric location associated with more favorable outcomes) (13).

Case report

A 63 year old female patient was admitted to our Department of General and Thoracic Surgery, "S. Anna" University Hospital in Ferrara, Italy for epigastric discomfort, dyspepsia and bilious vomiting. Physical examination showed no abnormalities. Blood biochemistry was normal.

The ultrasounds (US) showed an oval and heterogeneously mass of 13x9 cm, in the left hypochondrium. The endoscopy found hiatal hernia, chronic gastritis and esophagitis (grade B LA).

CT scan revealed an extraluminal inhomogeneous oval mass of 13x10x10 cm with some calcifications, occupying the left upper abdomen, probably originating from the wall of the gastric fundus with exophytic development. There weren't signs of malignancy, such as liver metastases, peritoneal dissemination and ascites. Intravenous contrast agents allowed clearer contrast between tumors and the surrounding tissues and organs.

The patient also underwent us-guided needle biopsy, which allowed a preoperative cytological evaluation, i.e.: spindle cell tumor with <1x10 mitosis HPF, no necrosis and no cytological atypia. Immunohistochemical staining was positive for CD117, CD34 and Actin but negative for S-100 and Desmin.

The patient underwent gastric resection with wide negative margins (R0) by a completely laparoscopic approach.

During laparoscopic exploration, an extramural pedunculated mass was located in the gastric fundus.

Laparoscopic wedge resection of the gastric lesion was performed with endoGIA linear stapler (EndoGIA 60 staple, three green cartridges) and a gastric fibrosis band attached to the spleen was resected. There was no tumor rupture during surgery. The tumor specimen was extracted using an endocatch bag, through minilaparotomy service according to Pfannenstiel.

The operation time was 180 min. The postoperative course was uneventful and the patient was discharged 5 days later.

The GIST was pathologically confirmed. The extramural mass (19x11x9 cm) was confirmed as a stromal tumor with a high level of mitotic activity (7 mitoses per 50 HPF, H&E stain). Immunohistochemical staining was positive for CD117, DOG 1, and Actin but negative for S-100 and Desmin.

Discussion and conclusion

Surgical resection with negative margins without lymphadenectomy has been the treatment of choice of gastric GISTs up to now (14). Histologically, a 1 to 2 cm margin has been thought to be necessary for adequate resection (15,16). Simple wedge resection, when feasible, has become the recommended surgical approach in the gastric GISTs, because it carries a lower risk of com-

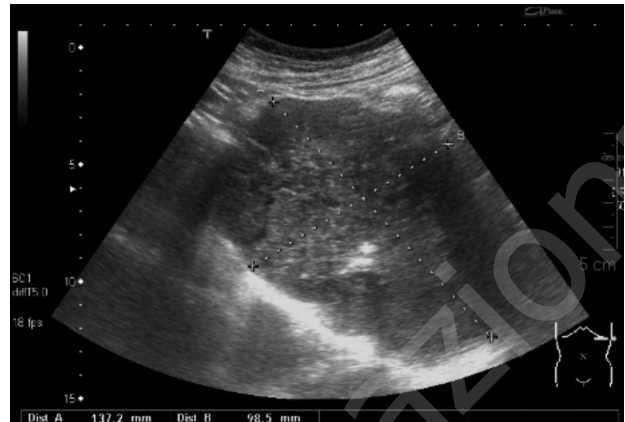

Fig. 1 - Ultrasounds showed an oval and heterogeneous mass of 13x10 cm in the left hypochondrium.

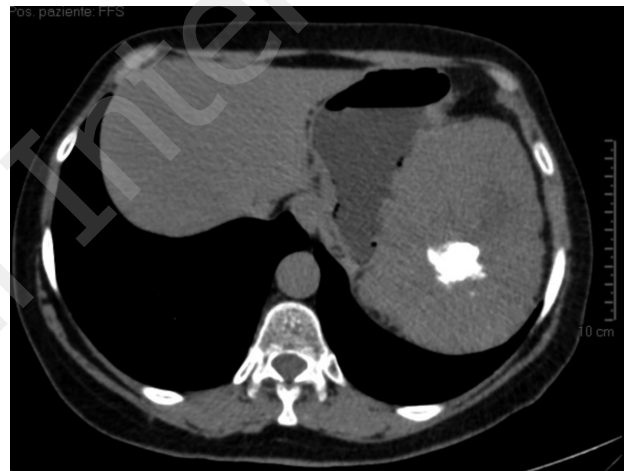


Fig. 2 - Unenhanced CT image: inhomogeneous tumor mass invading the left upper abdomen with irregular calcified inclusions, approximately in the center of the mass. Isodense appearance compared with the normal liver parenchyma.

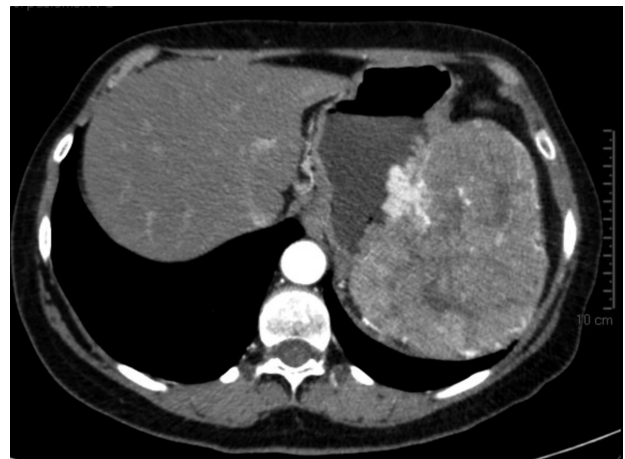

Fig. 3 - Contrast-enhanced CT image: inhomogeneous, extraluminal, tumor mass with irregular shape.

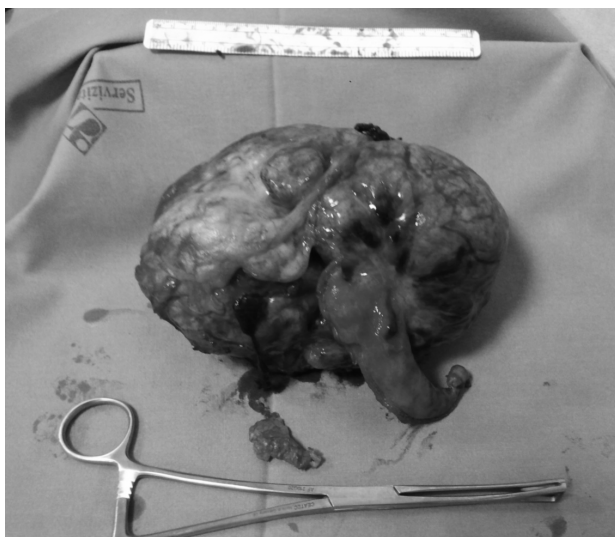


Fig. 4 - The large gastric GIST (19x10x10 cm).

plications, faster recovery, less pain, and better cosmesis (13). Laparoscopic surgical techniques became more difficult in cases with bigger gastric GISTs, and there was a possibility that tumor cells would spread due to the rupture of the capsules. Therefore, with bigger tumors, special attention should be paid to the prevention of capsular rupture.

Recent reports from the National Comprehensive Cancer Network (NCCN) GIST Task Force and the GIST Consensus Conference under the auspices of The European Society for Medical Oncology (ESMO) state that laparoscopic or laparoscopic-assisted resection may be used for small gastric GISTs (that is, those < 2 cm in size) (9). The size limit for laparoscopic GIST resection is continuously being modified (17) and Ronellenfitsch et al. stated that the tumor size did not determine the feasibility of laparoscopic wedge resection, and the lo-

cation of the gastric GISTs did not directly affect the indication for laparoscopic wedge resection (18). Ronellenfitsch et al. (18) and Huguet et al. (19) reported its feasibility for tumors bigger than 10 cm in diameter. The Japanese clinical practice guidelines for GIST suggest that laparoscopic resection of gastric GISTs smaller than 5 cm appears safe when performed by a skillful surgeon who is thoroughly familiar with the neoplastic characteristics of gastric GISTs (20). Larger tumor becomes more predisposed to peritoneal seeding by spreading out of the tumor by way of higher intratumor pressure or loosened tumor cellular adhesion. In terms of the possibility of capsular rupture during further manipulations, should be performed, giving timely conversion to the open method whenever necessary (24). In our case we tried to grasp the stomach and normal tissues around the tumor for the prevention of tumor spread during laparoscopic surgery.

The size of the tumor shows significant correlation with survival in gastric GIST and could be considered an indicator for adjuvant therapy (21). The size of the tumor represents a negative prognostic factor, while R0 resection is one of the most important factors predicting good prognosis (22). We corroborate the experience of Sokolich et al. who demonstrated that the laparoscopic approach appears to offer excellent therapeutic outcomes, also for resection of large tumors. This study has shown that large GIST can be resected safely, while obeying the cancer principles that are paramount to treating this disease (2). Nishimura et al. confirm the feasibility and safety of laparoscopic surgery for gastric GISTs of various sizes and locations and to assess its long-term oncologic outcome (23).

We think that laparoscopic surgery would be a good alternative to open surgery for the treatment of large gastric GIST bigger than 5 cm in size, however a prospective randomized controlled study of tumors larger than 5 cm is necessary.

References

1. Yi-Ping Mou, Xiao-Wu Xu, Kun Xie, Wei Zhou, Yu-Cheng Zhou, Ke Chen. Laparoscopic wedge resection of synchronous gastric intraepithelial neoplasia and stromal tumor. *World J Gastroenterol* 2010 October 21;16(39):5005-5008.
2. Sokolich J, Galanopoulos C, Dunn E, Linder JD, Jeyarajah DR. Expanding the Indications for Laparoscopic Gastric Resection for Gastrointestinal Stromal Tumors. A case report. *JSL* 2009;13:165-169.
3. Dematteo RP, Heinrich MC, Wa'el M. El-Rifai, Demetri G. Clinical Management of Gastrointestinal Stromal Tumors: Before and After STI-571. *Human Pathology* 2002 May;Volume 33;N.5.
4. Toshirou Nishida, Seiichi Hirota, Akio Yanagisawa Yoshinori Sugino, Manabu Minami Yoshitaka Yamamura, Yoshihide Otani Yasuhiro Shimada, Fumiaki Takahashi, Tetsuro Kubota. Clinical practice guidelines for gastrointestinal stromal tumor (GIST) in Japan: English version. *Journal of Clinical Oncology* 2008 October;vol. 13, Issue 5:416-430.
5. Lozano MD, Rodriguez J, Algarra SM, Panizo A, Sola JJ, Pardo J. Fine-Needle Aspiration Cytology and Immunocytochemistry in the Diagnosis of 24 Gastrointestinal Stromal Tumors: A Quick, Reliable Diagnostic Method. *Diagnostic Cytopathology* 2003;Vol 28, N.3:131.
6. Heinrich MC, Corless CL. Gastric GI stromal tumors (GISTs): the role of surgery in the era of targeted therapy. *J Surg Oncol* 2005;90:195-207.

7. Sanjoy Basu Æ Sam Balaji Æ David H. Bennett Æ Nick Davies. Gastrointestinal stromal tumors (GIST) and laparoscopic Resection. *Surg Endosc* 2007;21:1685-1689.
8. Otani Y, Furukawa T, Yoshida M, Saikawa Y, Wada N, Ueda M, Kubota T, Mukai M, Kameyama K, Sugino Y, Kumai K, Kitajima M. Operative indications for relatively small (2-5cm) gastrointestinal stromal tumor of the stomach based on analysis of 60 operated cases. *Surgery* 2006;139:484-492.
9. Blay JY, Bonvalot S, Casali P, Choi H, Debiec-Richter M, Dei Tos AP, Emile JF, Gronchi A, Hogendoorn PC, Joensuu H, Le Cesne A, Mac Clure J, Maurel J, Nupponen N, Ray-Coquard I, Reichardt P, Sciort R, Stroobants S, van Glabbeke M, van Oosterom A, Demetri GD. GIST consensus meeting panelists: Consensus meeting for the management of gastrointestinal stromal tumors. Report of the GIST Consensus Conference of 20-21 March 2004, under the auspices of ESMO. *Ann Oncol* 2005;16:566-578.
10. Rossi CR, Mocellin S, Mencarelli R, Foletto M, Pilati P, Nitti D, Lise M. Gastrointestinal Stromal Tumors: from a surgical to a molecular approach. *Int. J. Cancer* 2003;107:171-176.
11. Yukihiro Kitamura. Gastrointestinal stromal tumors: past, present, and future. *J Gastroenterol* 2008; 43:499-508.
12. Sabah M, Leader M, Kay E. Gastrointestinal stromal tumours: An update. *Current Diagnostic Pathology* 2005;11:400-410.
13. Hiroshi Yano, Yutaka Kimura, Takashi Iwazawa, Hirotoshi Take-moto, Mitsunobu Imasato, Takushi Monden, and Shigeru Okamoto. Hand-assisted laparoscopic surgery for a large gastrointestinal stromal tumor of the stomach. *Gastric Cancer* 2005;8:186-192.
14. Nowain A, Bhakta H, Pais S, Kanel G, Verma S. Gastrointestinal stromal tumors: clinical profile, pathogenesis, treatment strategies and prognosis. *J Gastroenterol Hepatol* 2005;20:818-824.
15. Matthews BD, Walsh RM, Kercher KW, Sing RF, Pratt BL, Answini GA, Heniford BT. Laparoscopic vs open resection of gastric stromal tumors. *Surg Endosc* 2002;16:803-807.
16. Rosen MJ, Heniford BT. Endoluminal gastric surgery: the modern era of minimally invasive surgery. *Surg Clin North Am* 2005;85:989-1007.
17. Karakousis GC, Singer S, Zheng J, Gonen M, Coit D, DeMatteo RP, Strong VE. Laparoscopic Versus Open Gastric Resections for Primary Gastrointestinal Stromal Tumors (GISTs): A Size-Matched Comparison. *Ann Surg Oncol* 2011;18:1599-1605.
18. Ronellenfitsch U, Staiger W, Kahler G, Strobel P, Schwarzbach M, Hohenberger P. Perioperative and oncological outcome of laparoscopic resection of gastrointestinal stromal tumour (GIST) of the stomach. *Diagn Ther Endosc* 2009;2009:286138.
19. Huguet KL, Rush RM Jr, Tessier DJ, Schlinkert RT, Hinder RA, Grinberg GG, Kendrick ML, Harold KL. Laparoscopic gastric gastrointestinal stromal tumor resection: the mayo clinic experience. *Arch Surg* 2008;143:587-590.
20. Nishida T, Hirota S, Yanagisawa A, Sugino Y, Minami M, Yamamura Y, Otani Y, Shimada Y, Takahashi F, Kubota T, GIST Guideline Subcommittee: Clinical practice guidelines for gastrointestinal stromal tumor (GIST) in Japan: English version. *Int J Clin Oncol* 2008;13:416-430.
21. Kai-Hsi Hsu, Ta-Ming Yang, Yan-Shen Shan, Pin-Wen Lin. Tumor size is a major determinant of recurrence in patients with resectable gastrointestinal stromal tumor. *The American Journal of Surgery* 2007;194:148-152.
22. Everett M, Gutman H. Surgical Management of Gastrointestinal Stromal Tumors: Analysis of Outcome With Respect to Surgical Margins and Technique. *Journal of Surgical Oncology* 2008;98:588-593.
23. Junichi Nishimura, Kiyokazu Nakajima, Takeshi Omori, Tsuyoshi Takahashi, Akiko Nishitani, Toshinori Ito, Toshiro Nishida. Surgical strategy for gastric gastrointestinal stromal tumors: laparoscopic vs. open resection. *Surg Endosc* 2007;21:875-878.
24. Ki-Han Kim¹, Min-Chan Kim¹, Ghae-Joong Jung¹, Su-Jin Kim, Jin-Seok Jang and Hyuk-Chan Kwon. Long term survival results for gastric GIST: is laparoscopic surgery for large gastric GIST feasible? *World Journal of Surgical Oncology* 2012;10:230.