

Role of emergency thoracic ultrasonography in spontaneous pneumomediastinum. Two case report

A. RUSSO¹, C. DEL VECCHIO¹, A. ZAOTTINI¹, C. GIANGREGORIO²

SUMMARY: Role of emergency thoracic ultrasonography in spontaneous pneumomediastinum. Two case report.

A. RUSSO, C. DEL VECCHIO, A. ZAOTTINI, C. GIANGREGORIO

Early identification of spontaneous pneumomediastinum in an Emergency Department is possible with thoracic ultrasound. We report two cases of spontaneous pneumomediastinum, diagnosed in a 26-year old man with chronic asthma and a 19-year old athlete, and discuss the role of thoracic US alongside conventional X-ray and thoracic CT in emergency medicine. The patients were transferred to an Emergency Department, where conservative treatment produced a good outcome. The greater sensitivity and specificity of thoracic US over conventional supine X-ray in the detection of occult pneumothorax is ever more appreciated. However, training in the diagnosis of pneumomediastinum is required.

RIASSUNTO: Ruolo dell'ecografia toracica in urgenza nello pneumomediastino spontaneo. A proposito di due casi clinici.

A. RUSSO, C. DEL VECCHIO, A. ZAOTTINI, C. GIANGREGORIO

Vengono descritti due casi di pneumomediastino (pnx) spontaneo. Il primo è di un giovane di 26 anni, affetto da asma bronchiale allergica cronica, con pnx spontaneo dopo tosse persistente; a 12 ore dal rifiuto della proposta di ricovero (giustificato dalla incompleta remissione della sintomatologia dopo terapia farmacologica), il paziente ritorna con imponente enfisema cervicale, nonostante la modesta dispnea lamentata. L'altro caso di pnx spontaneo è insorto in un diciannovenne sportivo, dopo una partita di pallanuoto. La TC, a tutt'oggi ritenuta il "gold standard" per la diagnosi, conferma in entrambi il sospetto di pneumomediastino, inducendo tra l'altro ad una revisione critica degli esami strumentali precedentemente effettuati, ovvero la radiografia standard e soprattutto l'ecografia del torace, di recente applicazione presso il nostro Dipartimento di Emergenza. La terapia conservativa, non essendosi verificata alcuna emergenza ipertensiva che richiedesse drenaggio chirurgico, ha consentito il completo recupero dei pazienti, confermando la buona prognosi di questa rara complicanza.

KEY WORDS: Pneumomediastinum - Ultrasound - Emergency.
Pneumomediastino - Ecografia - Emergenza.

Introduction

Pneumomediastinum is spontaneous or traumatic. Elevated alveolar pressure causes gas to infiltrate an anatomical cavity with negative pressure. As is already well known for pneumothorax, this pressure imbalance can cause major respiratory and circulatory distress, evolving into hypertensive pneumomediastinum.

We report two cases of spontaneous pneumomedia-

stinum. The first arose in a 26-year old man with chronic asthma after a fit of persistent coughing. Having initially refused admission (suggested due to incomplete remission following pharmacological treatment) he returned to our Department 12 hours later with severe emphysema of the neck, without significant dyspnea. The second case manifested in a 19-year old athlete after a game of water polo. The diagnosis was confirmed with thoracic CT, the gold standard for the diagnosis of pneumomediastinum.

This inspired a critical reevaluation of the instrumental investigations performed in both patients, X-ray and thoracic ultrasound, the latter recently adopted in our Department. The absence of any acute hypertension requiring a drain enabled the full recovery of both patients with non-invasive treatment, confirming the good prognosis of this rare condition.

"Parodi Delfino" Hospital, ASL Roma G, Colleferrro (Rome), Italy

¹ Emergency Unit- Surgical Emergency
(Head: M. Pagliei)

² Radiological Unit
(Head: M. Federici)

© Copyright 2012, CIC Edizioni Internazionali, Roma

Case reports

Case 1

DC is a 26-year old chronic asthma patient under occasional corticosteroid treatment. He presented with persistent coughing of a few days' duration, mild dyspnea refractory to his usual treatment (betamethasone 1 mg tablets), neck pain, and elevated temperature in the afternoon. Clinical examination revealed mild dyspnea (transcutaneous oxygenation 96%), normal skin and mucosa color, strong, rhythmic heartbeat without labored breathing or dysphonia, BP 120/80, temperature 38° C, pulse 80 bpm and respiratory frequency 25/min. A chest examination revealed insufficient lung inflation with a prolonged expiratory phase and crackle on the right. Chest movement was reduced, supporting the clinical suspicion of an inflammatory complication of chronic asthma. There were no significant findings with ECG and laboratory parameters and no inflammation was evident on X-ray (Figs. 1a and b).

Despite the absence of any radiological or laboratory signs of pneumonia, the incomplete response to medical therapy indicated the need for further investigation with a thoracic US (Figs. 2a and b). This was negative for pneumothorax, as the gliding sign was preserved despite some pleural effusion (normal curtain sign). However, some enhanced B lines were revealed, suggesting "wet lung", such as in cases of vascular congestion, and there was an uncertain hyperechoic area with pleural hyperdensity around the left cardiac outline.

The patient refused hospitalization, preferring home treatment. However, a reassessment of his X-ray 12 hours later revealed a very thin layer of pneumomediastinum in the left paracardial margin, and he was therefore invited to return for further investigation. At this time his mild dyspnea was unchanged but there was strong bilateral emphysema of the neck. Thoracic CT confirmed pneumomediastinum (Figs. 3a, b and c), which had spread to the muscles and subcutaneous cervical region. Although his cardiovascular and respiratory signs were steady, the patient was transferred to an Emergency Department, where he was treated conservatively. He was discharged a week later.

Case 2

MN is a 19-year old man who presented with odynophagia and a bloated feeling in the neck after a game of water polo. There was no trauma and the patient did not report coughing or wheezing. He did not have chronic bronchitis and had not had any recent flu-like symptoms. He had not ingested any foreign bodies, or consumed any foods or medicines that may cause allergies.

Oropharyngeal and chest examination were normal. Blood pressure was in the normal range (120/80 mmHg). Body temperature and blood oxygenation in room air (99%) were both normal. However, the patient reported moderate difficulty in speaking and laryngeal discomfort, while uniform supraclavicular turgor was noted at the base of the neck, with a characteristic crackling feel (subcutaneous crepitation) highly indicative of subcutaneous emphysema.

The chest X-ray (Figs. 4a, b) did not provide any substantial diagnostic elements, merely confirming the presence of soft tissue emphysema of the neck to the right and a radiolucent line along the trachea, compatible with the thoracic ultrasound finding of pneumomediastinum (Figs. 5a, b, and c). US ruled out pneumothorax and pleural or structural lung parenchyma alterations (gliding and curtain sign preserved), while both neck nerve bundles were surrounded by multiple hyperechoic artifacts with a bullous-like appearance, suggestive of subcutaneous emphysema, which extended through the acoustic window of the jugular along the contour of the aortic arch, compatibly with pneumomediastinum.

The diagnosis was confirmed by CT (Figs. 6a and b), which revealed soft tissue emphysema of the neck bilaterally. A thin layer of subcutaneous emphysema involving the front chest wall, more pro-

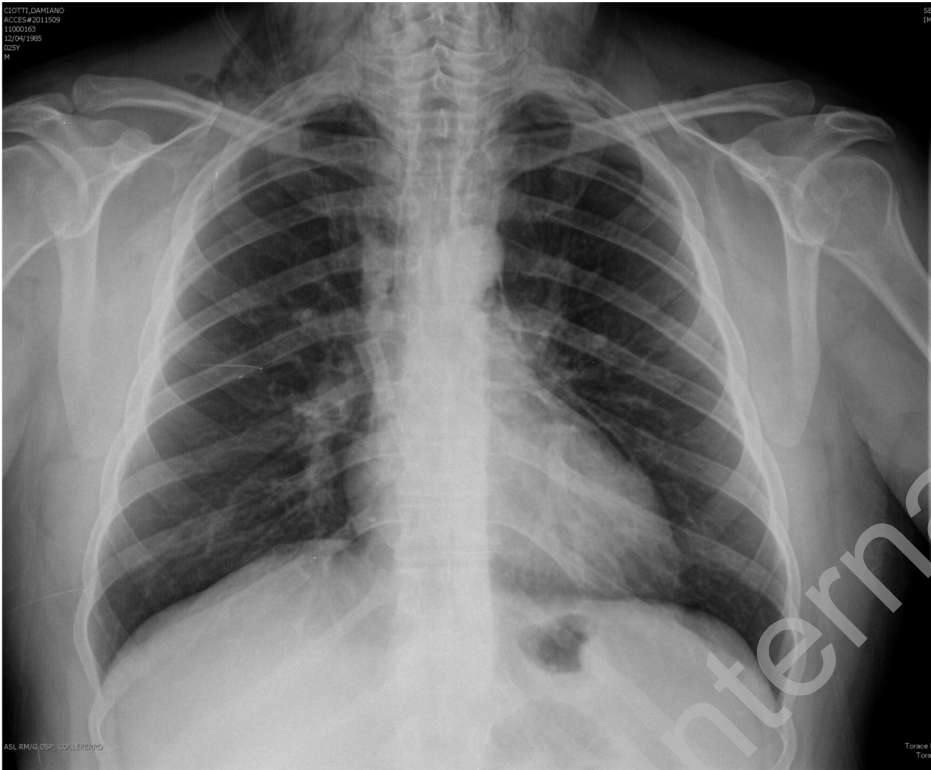
nounced on the right; marked pneumomediastinum mainly affecting the upper compartment, the trachea and its bifurcation; and minimal detachment of the parietal pleura of the lung apices, as in early pneumothorax. However, surgical evaluation in Emergency Department excluded the need for surgical drainage and the patient was discharged after 72 hours of clinical monitoring and symptomatic treatment. He made a full recovery, as confirmed by a follow-up outpatient chest X-ray after one week.

Discussion

Pneumothorax following multiple trauma was described for the first time in 1819 by the pathologist Laennec. In 1939 Hamman reported subcutaneous emphysema due to spontaneous post-partum pneumomediastinum in a living patient, later categorized as Hamman's syndrome. Only 200 cases of this syndrome have been reported in the literature (1 every 100,000 natural births), confirming both its rarity and the etiopathogenetic role played by a sudden abnormal pressure increase within the mediastinal cavity, which, like the pleural cavity, normally has negative pressure (1, 2).

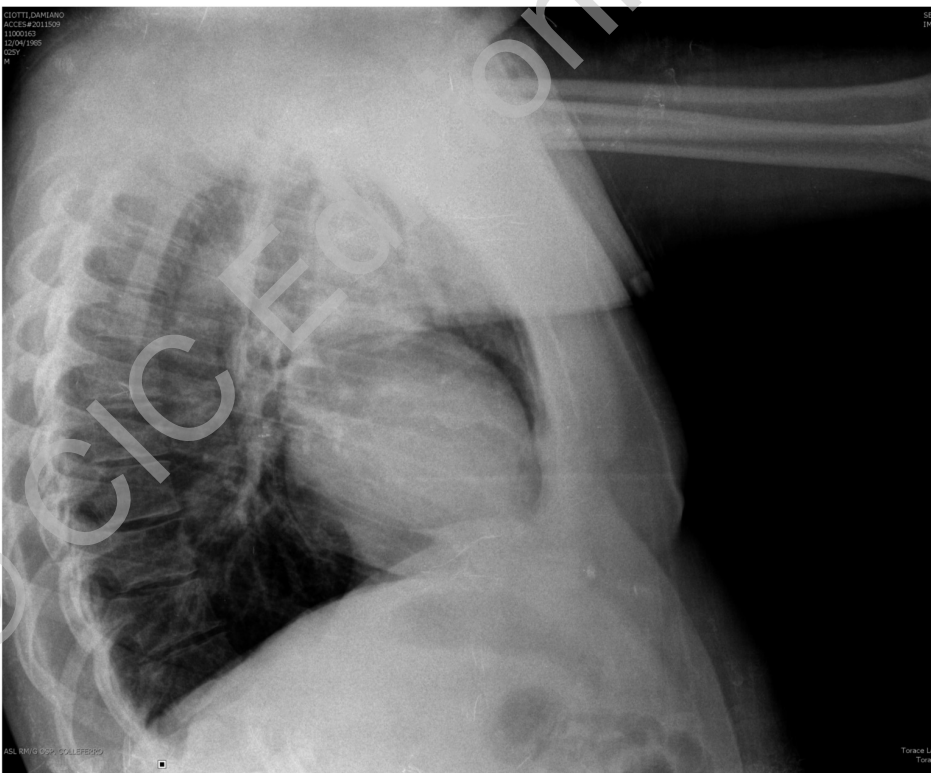
The incidence of spontaneous pneumomediastinum in adults attending emergency departments has been estimated at 1 in 44,500 patients treated, while the incidence in children is considerably higher (from 1 in 800 to 1 in 15,150). In 1979 Macklin described the sequence of events: alveolar rupture leads to air infiltration along the bronchovascular sheath with free air finally reaching the mediastinum. The most common causes of increased pressure in spontaneous pneumomediastinum include exacerbations of asthma and COPD during coughing fits, as in one of our patients; rapid ascent when scuba diving; mechanical ventilation (especially in those requiring higher maximum inspiratory pressure or positive end-expiratory pressure [PEEP]); use of drugs for inhalation; prolonged vomiting (3); and closed or penetrating trauma. Pneumomediastinum is also found in up to 10% of cases of major trauma, subsequent to traumatic injury to the tracheobronchial tree in around 25% of these. Such cases are obviously distinguished by a more acute onset, facilitating diagnosis.

It is still unknown why some patients develop the more rare complication of pneumomediastinum as opposed to pneumothorax. Fortunately, hypertension requiring emergency treatment is less frequent in the former, as the air that collects in the mediastinum spreads through the chest and drains spontaneously in the neck tissues. The difficulty of access for percutaneous drainage, which is generally subxiphoid in the fortunately rare event of pneumomediastinal hypertension (treated by thoracoscopy or thoracotomy), is thus counterbalanced by the physiological "safety valve" offered by the lax areolar tissue of the neck (Fig. 7). Due to its structural peculiarities, the mediastinum is relatively independent of the for-

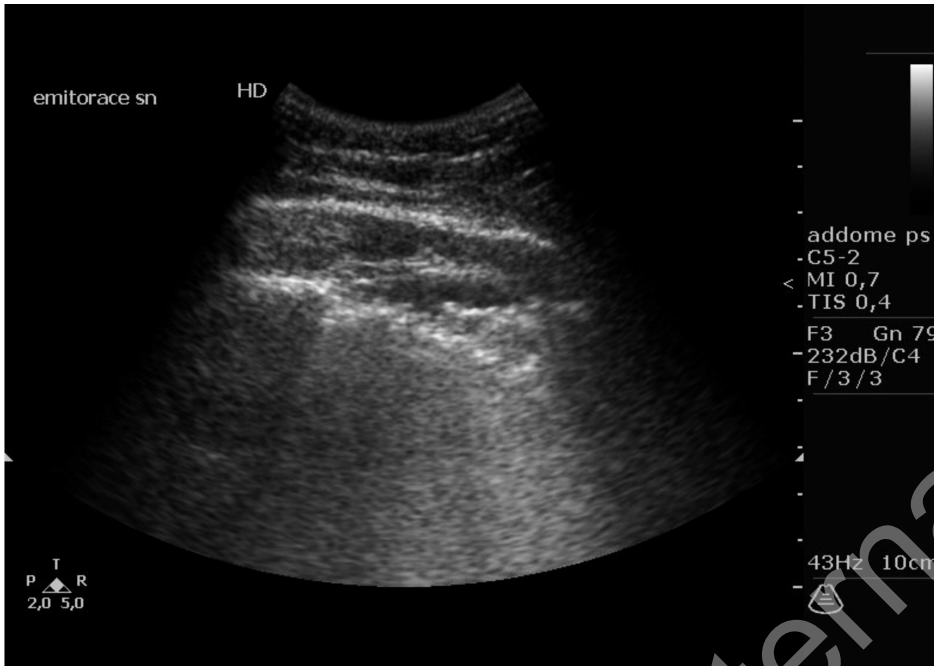

a)

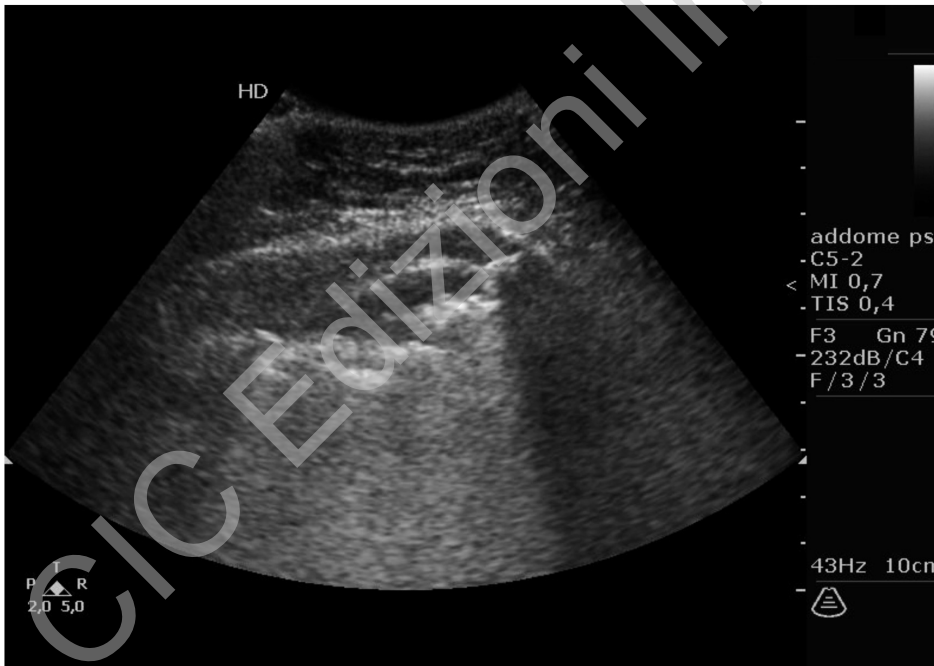Fig. 1 - Case 1 - a) Postero-anterior X-ray. Thin radiolucent line in the left paracardial margin, separating the pericardium from the mediastinal pleura. Clearly demarcated thin hyperlucent bands in the supraclavicular regions bilaterally indicative of subcutaneous emphysema. b) Lateral X-ray. Vena cava and the brachycephalic trunk, demarcated by the infiltrated air, which acts as a natural contrast agent in the most advanced phases of pneumomediastinum. The cardiac profile in the posterior compartment is in the initial stages of delineation by the air infiltration, that in severe cases can even cause flattening of the physiological convex diaphragm.



b)



a)

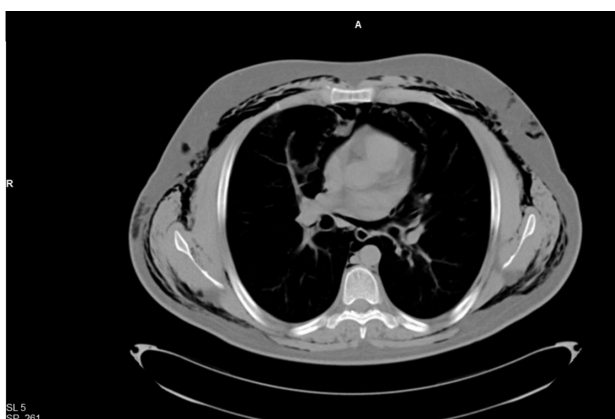


b)

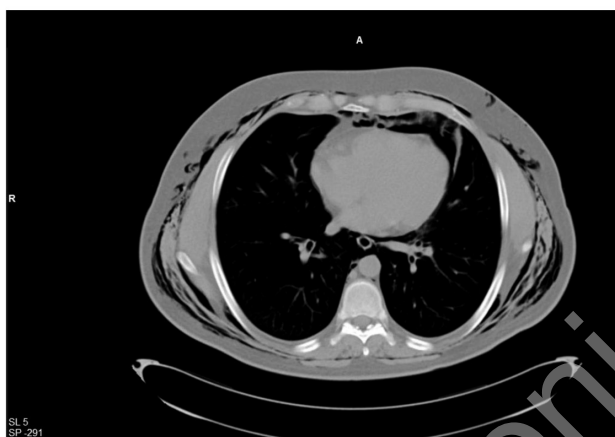Fig. 2 - Case 1 - a) Left parasternal US scan at the IV intercostal space, performed with convex probe. The acoustic artifacts (irregular whitish areas) correspond to air, and move in correspondence with the respiratory excursions: this kinetic evidence is possible only with ultrasound. b) The B lines, or vertical subpleural artifacts, fully exclude the presence of pneumothorax (which complicates 10% of cases of pneumomediastinum), as does the gliding sign of the pleura. The irregularity of the pleural profile is due to compression of the serous leaflet and the underlying pulmonary parenchyma by the air layer. The subsequent CT scan topographically confirms the location of the pneumomediastinum.

ces acting on the pleural cavity. Its elastic, spiral framework makes it both flexible and resistant to antero-posterior and longitudinal traction during respiration. The path of these elastic fibers give the mediastinum the same kinetics as a “water bubble” interposed between the two pleural cavities.

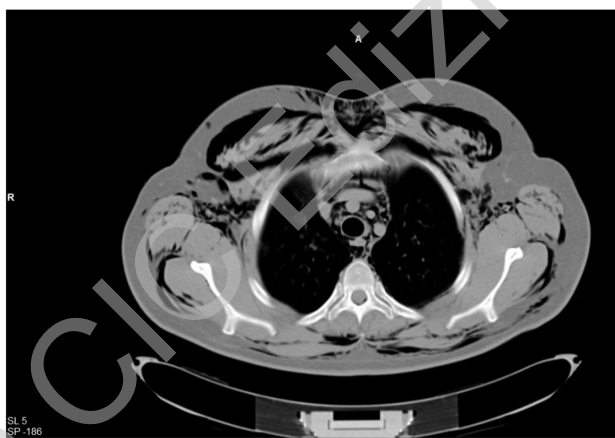
The loose cellular tissue of the mediastinum also helps cushion and protect the vital structures that it contains (heart, aortic arch and descending aorta, brachycephalic veins, azygous vein, superior vena cava, esophagus, vagus, trachea). This is demonstrated, for example, by the protection of the superior vena cava, largely con-



a)



b)



c)

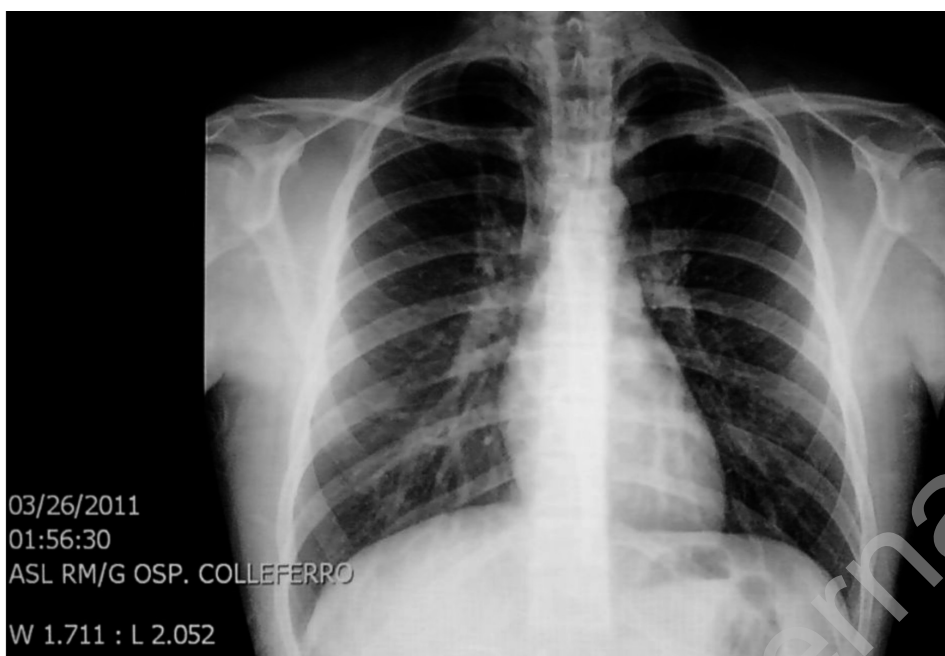Fig. 3 - Case 1 - a) Thoracic CT scan performed about 12 hours after the previous examinations. The hypodense line in the left paracardial area separating the pericardium from the pleural ipsilateral profile is now clearly visible. **b)** CT section revealing air infiltration into the pulmonary hilar structures, that appear "to float" in the gaseous environment. Indication of area of secondary pleural thickening and initial pulmonary atelectasis previously identified with US. This, alongside the medical history (dyspnea with thoracic pain and temperature rise), had led to an initial diagnosis of bronchopneumonia. **c)** 12 hours later. The upward infiltration of air into lax tissues causes significant detachment of the aponeuroses, responsible for the "gull wing" pattern of the pectoralis major and causing conspicuous subcutaneous emphysema.

tained in this compartment, from pressure imbalances between the various anatomical compartments, in comparison with the greater vulnerability of the inferior vena cava, which is more clearly affected by respiratory excursions and thoraco-abdominal pressure differences (ascites, hypovolemia from seizure, etc.). Of course, the protective role of cushioning lies in the physiological elasticity of the fibers. Ageing-related sclerosis or hyaline degeneration contributes to a loss of biomechanical compensation, explaining both the longer course of surgical drainage in the elderly and the particular elasticity and separability of the mediastinal pleura, especially in the hilar region. The latter explains the increased susceptibility of the young to gaseous infiltration after barotraumas (4). Numerous studies have in fact documented the rarity of the Macklin effect in the over sixties, in whom the increased frequency of interstitial fibrosis prevents detachment of the bronchovascular sheaths.

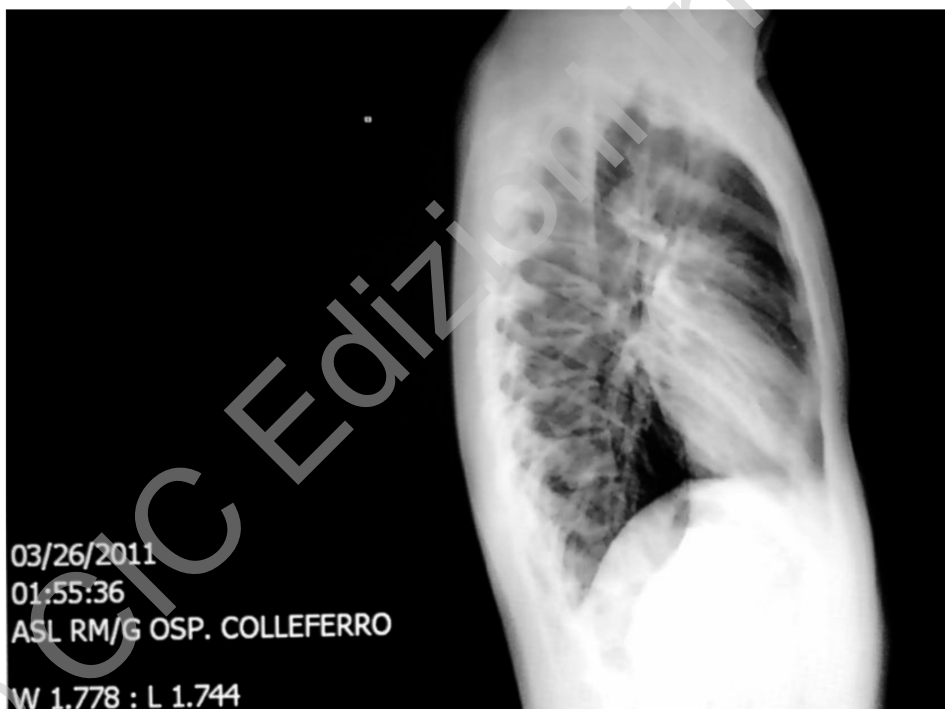Finally, we must not forget the mediastinum's role during inspiration, in particular in right atrial refilling during diastole (vacuum effect). Generally, respiratory exchange is not significantly affected by pneumomediastinum, as the laceration affects few alveoli, although bronchoscopy is necessary to rule out any tracheobronchial tree injury. Spontaneous pneumothorax may be caused by intense physical activity, bullous congenital degeneration of the lung, emphysema, asthma paroxysms, interstitial pneumonia, and anorexia (5), as well as invasive diagnostic or therapeutic techniques (6) that can both increase intrathoracic pressure and impair serous membrane resistance. However, in a considerable proportion of patients (up to 60%) the trigger is never found.

The clinical signs of spontaneous pneumomediastinum can be summarized as retrosternal pain (80%), rhinophonia and/or hoarseness (65%), dyspnea (46%), cough (26-45%), subcutaneous emphysema (32%), sore throat (18%), and neck pain (4-38%). The main causes include vomiting (36%), asthma (21%), cough (7-35%), intense physical activity (30%) or work (15%) (7), which are in turn responsible for barotrauma, or destructive lung lesions or radiotherapy regimens (the vulnerability of the serous membranes to radiation is well-known) (8). Signs and symptoms usually arise 24-48 hours before they prompt the patient to seek medical attention, due to the compensating factors found above all in young chronic bronchitis patients and the non-specific symptomatology. This is demonstrated in case 1, where the underlying chronic obstructive respiratory syndrome led to more specific symptoms but the patient deferred seeking medical help until two days after his cough had proven unresponsive to his normal asthma treatment. In contrast, in case 2 the intensity of his symptoms led the patient to come to the Emergency Department more quickly.

In the early stages, i.e. in the so-called occult form,



a)

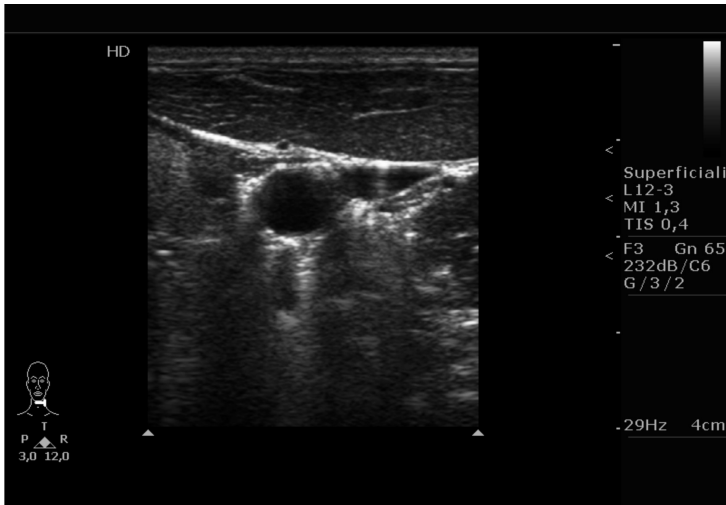

b)

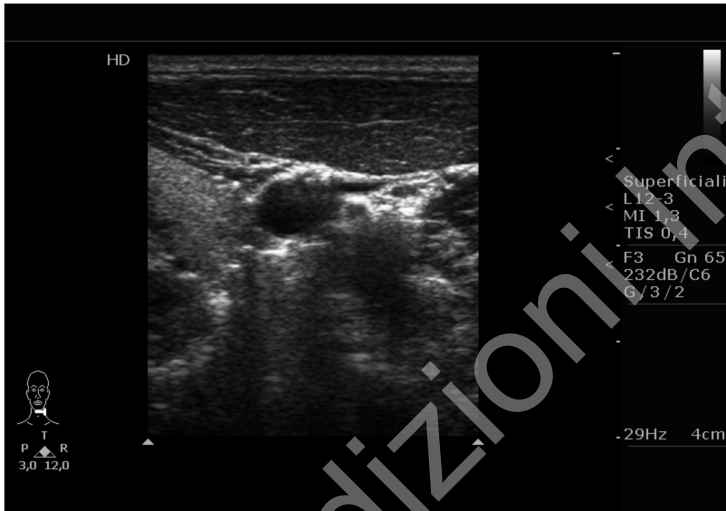Fig. 4 - Case 2 - a) Chest X-ray. No significant findings, except a thin line of hyperlucency delineating the tracheal profile to the right and emphysema of the soft neck tissues. b) At the back, enhanced contrast of the posterior mediastinum structures, that appear well delineated (as suggested by the hyperlucent area between the back of the heart and the prevertebral plane).

pneumomediastinum might not be detected with conventional radiography, as demonstrated by these cases. This is especially true where there is an underlying chronic condition such as allergic asthma, when there is no particular change to the usual symptoms, and particularly if masked by fever. Most literature reports (7-10)

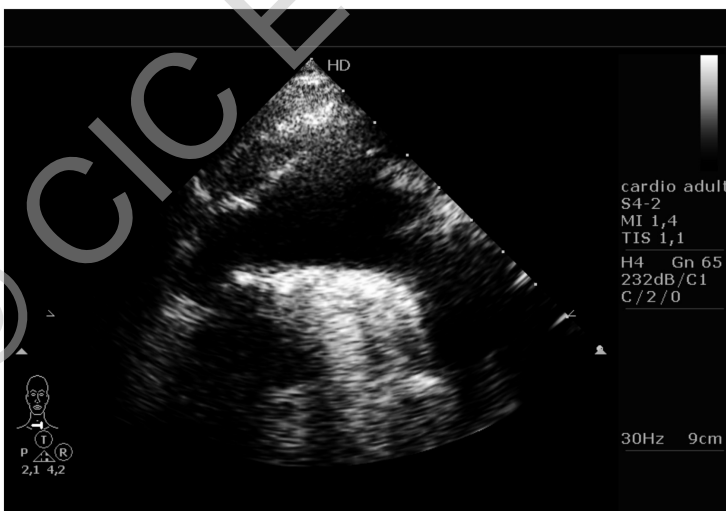concur that the risk factors are youth (14-35 years) and male gender (70%) (11-13), especially in the presence of asthma (22%). They also agree that the prognosis is good with conservative symptomatic treatment (14, 15) consisting of rest, analgesics, and clinical monitoring. Results are excellent even in the case of unfortunate com-



a)

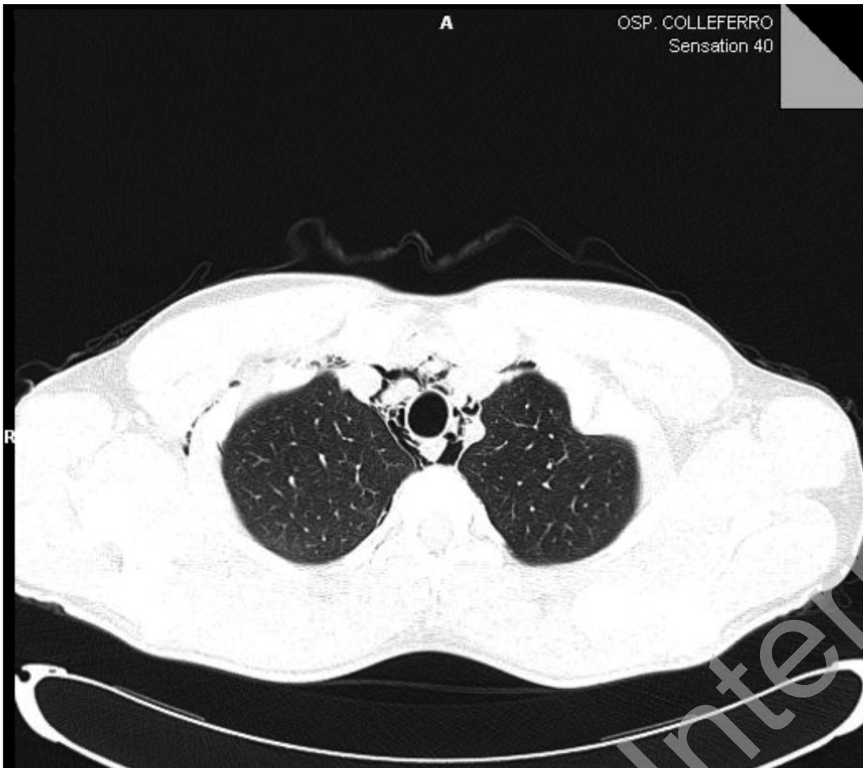


b)

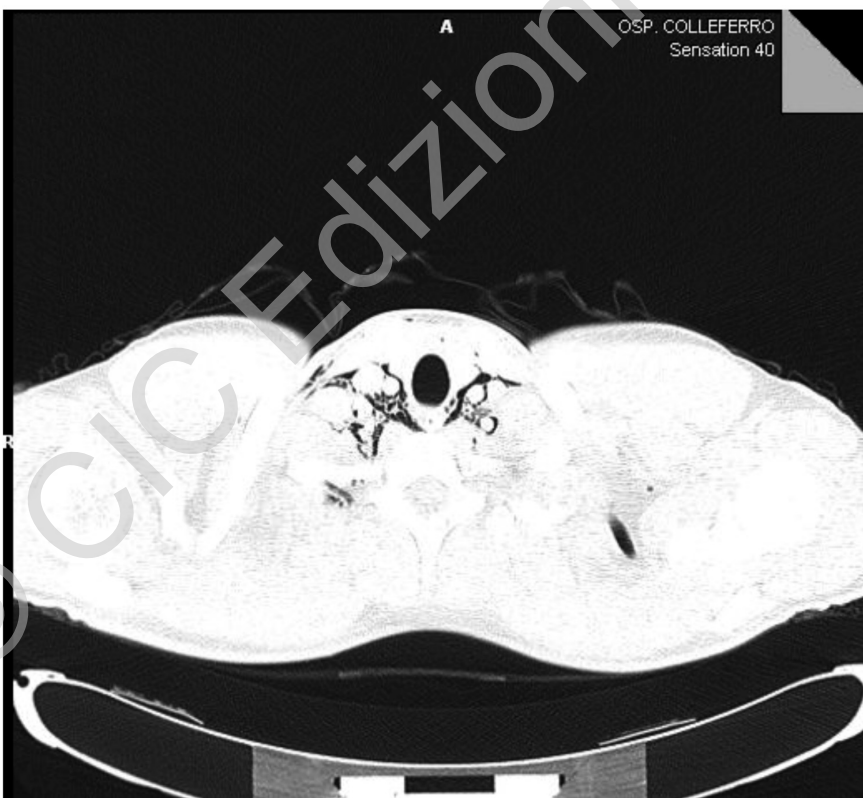

c)

Fig. 5 - Case 2 - a) Transversal US scan with linear probe. Multiple hyperechoic artifacts around the nerve bundle in the laterocervical region, suggestive of subcutaneous emphysema. However, these were not present to the extent that would have made them evident in the form of radiolucent stripes in the standard X-ray. b) Detail of the neck vessels, confirming the presence of multiple whitish miliary areas, which move with the nerve bundle and on compression by the probe, indicative of air infiltration. c) Scan of lung apex with vector array probe, conducted using the jugular as the acoustic window, that reveals a significant band of acoustic impedance (whitish area) around the aortic arch, extending downwards.



a)



b)

Fig. 6 - Case 2 - a) CT scan. Marked pneumomediastinum in mediastinal superior compartment, along the trachea and its bifurcation. b) Thin bilateral layer of subcutaneous emphysema (more evident on the right) in the anterior thoracic wall, associated with marked emphysema of the soft tissues of the neck.

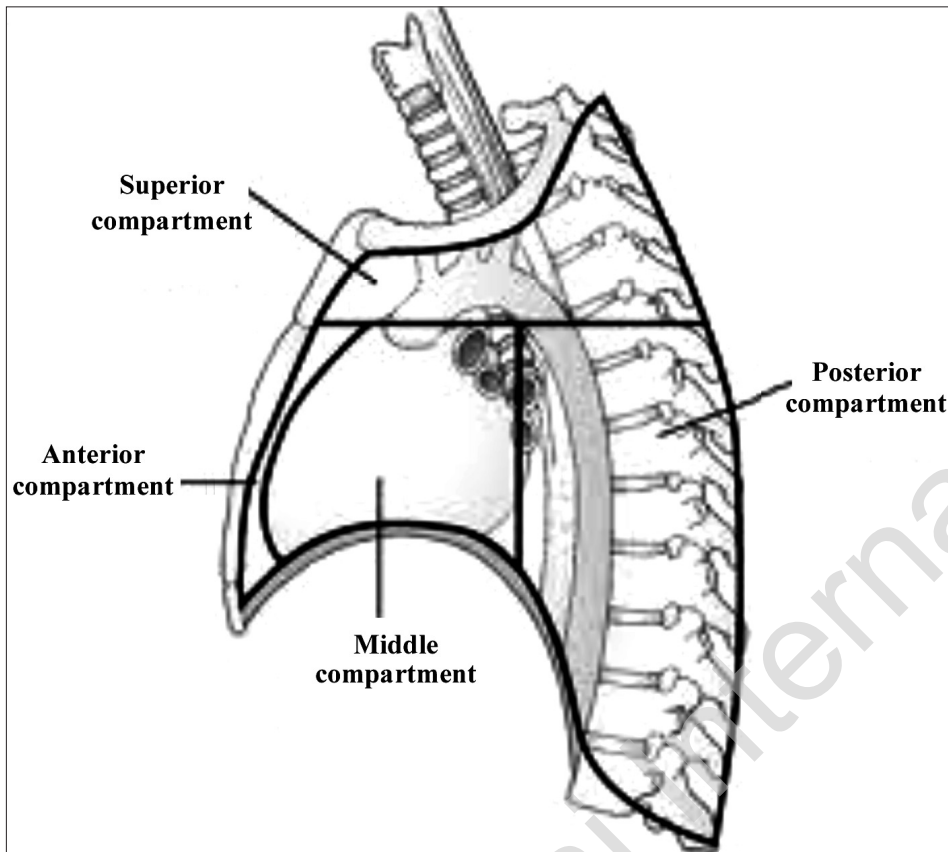


Fig. 7 - The mediastinum is divided for descriptive purposes into an upper and lower portion (superior and inferior), of which the inferior is further divided into three compartments (anterior, middle and posterior). The intercommunication of these sectors, which is independent of the physiological state, and their communication with surrounding areas (neck and subdiaphragm) explains how air and fluid (effusions from inflammatory processes) can migrate to areas far from the source (e.g. upper airway or esophageal lesions and abscesses) in pathological circumstances.

plications of mediastinitis involving ulcerations of the esophagus or trachea or the simultaneous presence of pneumorrhachia, pneumopericardium (16-18) and pneumoperitoneum, which has also been described in the literature.

The simultaneous development of pneumorrhachia, subcutaneous emphysema, pneumomediastinum, pneumopericardium and pneumoretroperitoneum was first described in 2002, in a young man undergoing proctocolectomy for ulcerative colitis (19). Since then, there have been increasingly common reports of iatrogenic lesions caused by invasive diagnostic procedures such as endoscopy and open-air or closed surgery. These usually involve more anatomical sites, and in contrast with spontaneous or traumatic events early recognition is of course facilitated by appropriate diagnostic and instrumental monitoring of the main condition.

As well as the obvious subcutaneous emphysema of the neck the main clinical sign suggesting pneumomediastinum is Hamman's sign: cardiac crackles and bubbles. These were actually heard in the first case, which was initially misinterpreted as suspected inflammation, but were in fact due to systolic pulsation of the heart when surrounded by air. The fever contributed to the initial misinterpretation of the syndrome as an inflamma-

tory process. This diagnosis was also supported by the responsiveness, albeit incomplete, to bronchodilator therapy, antibiotics and cortisone - the reason that the patient refused hospitalization.

Due to the unsatisfactory correlation of the initial exploratory chest X-ray in two projections with the patient's persistent clinical syndrome, a chest ultrasound was performed before resorting to CT. Incidentally, it should be remembered that the pathognomonic radiographic signs of pneumomediastinum include lateral detachment of the mediastinal pleura from the pericardium and large vessels. In our first patient, this was revealed in the original X-ray by a thin radiolucent line in the left paracardiac area (the only evidence of the very early stages of pneumomediastinum), which however was missed in the initial evaluation. The other signs are the presence of gas between the heart and diaphragm (continuous diaphragm sign); air dispersion in a cranial direction, seen as radiolucent streaks, which should be looked for in the supraclavicular areolar tissue; and Nacliero's V sign, i.e. the hyperlucent V-shape between the descending aorta and left hemidiaphragm, when detachment of the serous membrane becomes more conspicuous. In lateral X-ray, the infiltration of air into the tissues surrounding the right pulmonary artery is the so-called "ring sign".

As seen in the second patient, the enhanced visibility in the lateral projection of anatomical structures such as the superior and inferior cava and brachycephalic trunks (which are usually poorly defined) in addition to the esophagus is a pathognomonic sign of pneumomediastinum. When the esophagus is dilated with air, it can be used as a natural landmark for the detection of abnormal mediastinal hyperlucency, in which the aortic arch is clearly demarcated by the tracheal contrast (20). In the early stages (as in the original X-ray in our subjects), pneumomediastinum is first revealed by a thin hyperlucent line surrounding the cardiac outline in the AP view, sometimes making differential diagnosis from pneumopericardium very difficult. This line can be traced along the tracheal wall as the mediastinal pleura progressively detaches from the lung.

The differential diagnosis includes conditions that cause a widening of the upper mediastinum, such as aortic isthmus lesions (90%), at which point the vessel is anchored by the arterial ligament, or ruptures of the membranous part of the tracheal tree. In the latter case the more marked clinical signs aid interpretation.

The use of ultrasound (FAST) in blunt abdominal trauma is now part of the routine diagnostic protocol in emergency departments. Having overcome initial resistance, mainly due to difficult-to-abandon traditional practice, its use in emergency medicine for the detection of occult pneumothorax (EFAST) and other causes of acute dyspnea (bronchopneumonia, pleural effusions, etc.) is increasingly widespread. In this field, information must be gathered as quickly as possible, and the technique has proven even more diagnostically sensitive than standard radiography (sensitivity 48.8% vs. 20.9%, specificity 99.6% vs. 98.7%) (21-24).

The use of ultrasound in emergency medicine offers various advantages. First, diagnosis and treatment are carried out by the same person, who has direct access to the symptoms and medical history reported by the patient. Second, the technique is both fast and simple, with a high diagnostic and therapeutic impact. Finally, it can be focused on specific anatomical regions or organs to obtain answers to simple but crucial questions (e.g. "Are there any fluid effusions? Is there pneumothorax?"). In short, it enables the fast acquisition of the information needed to establish the therapeutic approach, thus improving the prognosis. The minimal margins of uncertainty derive from the dynamic study of the pathophysiological setting, which is directly displayed in real time (so-called "visual medicine"), rather than assumed or reconstructed through the static elements possible with other techniques.

Especially in the early stages when signs and symptoms are scarce and nonspecific, conventional X-rays in two projections may be negative in up to 30% of patients, as in our case 2. For this reason, CT can be regarded as

the gold standard for diagnosis of pneumomediastinum. In case 2, chest ultrasound revealed an initial area of atelectasis in the left lung paracardiac margin (Fig. 2a) with secondary pleural thickening (although this was initially interpreted as a possible area of thickening due to parenchymal inflammation, given the concomitant reported signs of cough and fever). It also showed hyperechoic artifacts corresponding to air bubbles. In the first patient, these were detaching the mediastinal pleura from the pericardium, and in the second were infiltrating the nerve bundle of the neck and surrounding the aortic arch (Figs. 6a, and 6b). US also confirmed the absence of pneumothorax through the physiological "gliding sign" and preservation of the B lines, whose negative predictive value for the exclusion of this additional complication is recognized as 100%.

The ultrasound findings from case 1 were later reassessed in light of the information offered by the CT scan. The previously missed thin anechoic band with clearly defined edges separating the pericardium from the pleural line was now discovered, revealing a thin layer of extrapleural air whose movements followed the respiratory excursions. At least in our experience this is a completely new sign of this rare disease.

The accessibility of the parasternal acoustic windows in the areas where the probability of locating air is highest (pneumothorax front: 84%, apex: 57%, baseline: 41%; lateral: 24%, middle 27%, back: 0%) make thoracic ultrasound a highly reliable technique for the evaluation of pneumothorax, in contrast with standard radiography performed in the supine position, which does not reveal such air (25-27). This may enable CT to be avoided, thus reducing both the biological risk (need for serial examinations) and operating costs. In major trauma it could also prevent the potential iatrogenic deterioration of unrecognized pneumothorax through ventilatory maneuvers and orotracheal intubation through the undiscovered lesion, which could cause it to become hypertensive.

Pneumomediastinum is found in about 6% of cases of moderate closed chest trauma (28), and may require surgical drainage (47%). In such cases early detection is understandably important, to prevent devastating changes in the cardiorespiratory dynamics supported by mechanical ventilation (29). It is interesting to note that while pneumothorax never evolves to pneumomediastinum (so their concomitance should prompt a search for multiple injuries), there is a 10% probability of the converse, namely the development of pneumothorax from pneumomediastinum. In this case, patients should be clinically monitored for at least 48 hours.

Secondary pneumomediastinum requires surgical repair of the post-traumatic or iatrogenic bronchial or esophageal defect causing air infiltration, and has a poor prognosis in the case of occult lesions. In contrast, spon-

taneous pneumomediastinum is treated symptomatically with oxygen, rest, analgesics, and antibiotics (for bacterial infections only) and is generally resolved very quickly (24-48 hours). The clinical course may be longer in the event of concomitant pleuroparenchymal conditions, as seen in our first patient, with obvious repercussions for recovery.

In contrast, surgical drainage is required in the event of the development of mediastinal or pericardial hypertension, the build-up of a large subcutaneous emphysema and consequent pneumothorax (4-32%) or the development of a mediastinal abscess (usually in the posterior compartment), although there is growing appreciation for the minimal invasiveness of transcervical video assisted thoracoscopic surgery. This technique offers reduced morbidity without compromising the results (30, 31).

Conclusions

The two cases described herein had various features in common: young age, male gender, initial symptoms (neck discomfort and odynophagia with development of emphysema of the soft tissues of the neck), intrinsic barotrauma (persistent cough in the first patient and Val-

salva maneuver during physical effort in the second), moderate change in the respiratory dynamics, without any significant repercussion for blood oxygenation, and excellent clinical course with a conservative approach. These elements are also in line with literature evidence to date.

The use of ultrasound for the diagnosis of pneumomediastinum in the Emergency Department was an important new development in the cases reported herein, given the condition's rarity and the general failure to use this technique to investigate chest disorders due to a lack of knowledge - even among radiologists - and availability of the technique itself. Its use in emergency departments enables physicians to harmonize and correlate the various diagnostic and therapeutic resources more rapidly than would be possible for specialists working alone.

The rarity of this complication is demonstrated by the scarcity of literature reports (32, 33). However, the integration of conventional radiography with thoracic ultrasound could reduce radiobiological risk and help contain medical costs (an unfortunately pressing need) for the diagnosis of this kind of disorder.

In any case, more experience is undoubtedly needed, although the aforementioned rarity means that such experience is difficult to come by - these are in fact the first two cases to come to our attention. Of course, this in itself is a stimulus for further research.

References

1. Revicky V, Simpson P, Fraser D. Postpartum pneumomediastinum: an uncommon cause for chest pain. *Obstetr Gynecol Int* 2010;956142; Epub 2010 dec 1.
2. Khalil H, Aubin F. Immediate postpartum pneumomediastinum. *J Obstetr Gynecol Can* 2010;32(12):1125.
3. Fiorelli A, Brongo S, D'Andrea F, Santini M. Negative-pressure pulmonary edema presented with concomitant spontaneous pneumomediastinum: Moore meets Macklin. *Interact Cardiovasc Thorac Surg* 2010;14(epub ahead of print).
4. Ameh V, Jenner R, Jilani N, Bradbury A. Spontaneous pneumopericardium, pneumomediastinum and subcutaneous emphysema; unusual complications of asthma in a 2-year-old boy. *Emerg Med* 2006; 23(6): 466-7.
5. Hochlehnert A, Lowe B, Bludau HB, Borst M, Zipfel S, Herzog W. Spontaneous pneumomediastinum in anorexia nervosa; a case report and review of the literature on pneumomediastinum and pneumothorax. *Eur Eat Disord Rev* 2010;18(2):107-115.
6. Hiremath S, Hegde HV, Swamy PR, Pai RB. Tension pneumothorax and pneumomediastinum caused by malpositioned mediastinal drain in a patient following closure of an atrial septal defect. *J Cardiothorac Vasc Anesth* 2011;11(epub ahead of print).
7. Caceres M, Ali SZ, Braud R, Weiman D, Garret EH Jr. Spontaneous pneumomediastinum: a comparative study and review of literature. *Ann Thorac Surg* 2008;86(3):962-966.
8. Barquero-Romano J, Redondo-Moralo MJ. Spontaneous pneumomediastinum and subcutaneous emphysema: an uncommon complication of lung cancer. *Arch Broncopneumol* 2009; 45(6):310-311.
9. Macia I, Moya J, Ramos R, Morera R, Escobar I, Saumench J, Perna V, Rivas F. Spontaneous pneumomediastinum; 41 cases. *Eur J Cardiothorac Surg* 2007;31(6):1110-1114.
10. Gerazounis A, Athanassiadi K, Kalantzi N, Moustardas M. Spontaneous pneumomediastinum; a rare benign entity. *J Thorac Cardiovasc Surg* 2003;126(3):774-776.
11. Campillo- Soto A, Coll-Salinas A, Soria- Aledo V, Blanco-Barrio A, Flores-Pastor B, Candel-Arenas M, Aguayo-Albasini JL. Spontaneous pneumomediastinum a descriptive study of our experience with 36 cases. *Arch Broncopneumol* 2005;41(9):528-531.
12. Cacerese M, Braud RL, Maekawa R, Weiman DS, Garrett HE Jr: Secondary pneumomediastinum: a retrospective comparative analysis. *Lung* 2009;187(5):341-346.
13. Eberle C, Junger K, Debatin KM, Wabitsch M. Spontaneously occurring pneumomediastinum related to pneumopericardium, a pneumothorax and a skin emphysema in a 12-year old boy. *Klin Pediatr* 2010;222(1):40-44.
14. Cicak B, Verona E, Mihatov-Stephanovic I, Vrsalovic R. Spontaneous pneumomediastinum in a healthy adolescent. *Acta Clin Croat* 2009;48(4):461-467.
15. Lee YJ, Jin SW, Jang SH, Lee EK, Kim YJ, Lee MY, Park JC, Rho TH, Kim JH, Hong SJ, Choi KB. A case of spontaneous pneumomediastinum and pneumopericardium in a young adult. *Korean J Intern Med* 2001;16(3):205-209.

16. Al-Mufarrej F, Gharagozloo F, Tempesta B, Margolis M. Spontaneous cervicothoracolumbar pneumorrhachis, pneumomediastinum and pneumoperitoneum. *Clin Respir J* 2009;3(4):239-243.
17. Giuliani S, Franklin A, Pierce J, Ford H, Grikscheit TC. Massive subcutaneous emphysema, pneumomediastinum and pneumopericardium in children. *J Pediatric Surg* 2010;45(3):647-649.
18. Wang H, Nugent WC. Cough-induced bilateral spontaneous pneumothorax. *Ann Thorac Surg* 2010;90(4):1363-1365.
19. Holton LH, Migaly J, Rolandelli RH. Pneumorrhachis, subcutaneous emphysema, pneumomediastinum, pneumopericardium, and pneumoretroperitoneum after proctocolectomy for ulcerative colitis: a report of a case. *Dis Colon Rectum* 2002;45(4):567-570.
20. Ota H, Fujita S, Nakamura T, Tanaka S, Tono T, Murata Y, Tanaka N, Okajima S. Pneumoretroperitoneum, pneumomediastinum, pneumopericardium and subcutaneous emphysema complicating sigmoidoscopy: report of a case. *Surg Today* 2003;33(4):305-308.
21. Kirkpatrick AW, Sirois M, Laupland KB, Liu D, Rowan K, Bakk CG, Hameed SM, Brown R, Simons R, Dulchawsky SA, Hamilton DR, Nicolau S. Hand-held thoracic sonography for detecting post-traumatic pneumothoraces; the Extended Focused Assessment with Sonography for Trauma (EFAST). *J Trauma* 2004;57(2):288-295.
22. Bialvas M, Lyon M, Duggal S. A prospective comparison of supine chest radiography and bedside ultrasound for the diagnosis of traumatic pneumothorax. *Acad Emerg Med* 2005;12(9):844-849.
23. Wilkerson RG, Stone MB. Sensitivity of bedside ultrasound and supine anteroposterior chest radiographs for the identification of pneumothorax after blunt trauma. *Acad Emerg Med* 2010;17(1):11-17.
24. Stengel D, Bauwens K, Sehoul J, Rademacher G, Mutze S, Ekkernkamp A, Porzsolt F. Emergency ultrasound-based algorithm for diagnosing blunt abdominal trauma. *Cochrane database Syst Rev* 2005;18(2):CD004446.
25. Ball CG, Kirkpatrick AW, Laupland KB, Fox DL, Litvinchuk S, Dyer DM, Anderson IB, Hameed SM, Kortbeek JB, Mulloy R. Factors related to the failure of radiographic recognition of occult pneumothoraces. *Am J Surg* 2005;189(5):541-546.
26. Ball CG, Kirkpatrick AW, Feliciano DV. The occult pneumothorax: what have we learned? *Can J Surg*; 2009;52(5):E173-17.
27. Ball CG, Dente CJ, Kirkpatrick AW, Shah AD, Rajani RR, Wyrzykowski AD, Vercruyse GA, Rozycki GS, Nicholas JM, Salomone JB, Faliciano DV. Occult pneumothoraces in patients with penetrating trauma: does mechanism matter? *Can J Surg*; 2010;53(4):251-255.
28. Rezende-Neto JB, Hofmann J, Al Mahroos M, Tien H, Hsee LC, Spencer Netto F, Speers V, Rizoli SB. Occult pneumomediastinum in blunt chest trauma; clinical significance. *Injury* 2010;41(1):40-43.
29. Ball CG, Kirk AW, Laupland KB, Fox DI, Nicolau S, Anderson IB, Hameed SM, Kortbeek JB, Mulloy RR, Litvinchuk S, Boulanger BR. Incidence, risk factors and outcomes for occult pneumothoraces in victims of major trauma. *J Trauma* 2005 Oct;59(4):917-924.
30. Testa A, Candelli M, Pignataro G, Costantini AM, Pirroni T, Silveri NG. Sonographic detection of spontaneous pneumomediastinum. *J Ultrasound Med* 2008 Oct;27(10):1507-1509.
31. Megremis S, Stefanaki S, Tsekoura T, Tsilimigaki A. Spontaneous pneumomediastinum in a child: sonographic detection in a case with minimal findings on chest radiography. *J Ultrasound Med* 2008 feb;27(2):303-306.
32. Welter S, Krbek T, Stamatis G. A new technique for complete intraluminal repair of iatrogenic posterior tracheal lacerations. *Interact Cardiovasc Thorac Surg* 2011 Jan;12(1):6-9.
33. Kozuki A, Shinozaki H, Tajima A, Kase K. Successful treatment for descending necrotizing mediastinitis with severe thoracic emphysema using video-assisted thoracoscopic surgery. *Gen Thorac Cardiovascul Surg* 2010 Nov;58(11):584-587.