

## Endoscopic treatment of difficult choledocholithiasis

B. BELVERDE, S. FRATTAROLI, A. CARBONE, G. VICECONTE

**SUMMARY:** Endoscopic treatment of difficult choledocholithiasis.

B. BELVERDE, S. FRATTAROLI, A. CARBONE, G. VICECONTE

*Common bile duct stones can be treated with normal endoscopic techniques. Where stones cannot be removed due to their size or number or due to stenosis of the common bile duct, a plastic stent can be inserted, enabling rapid drainage of bile. At the three-month check-up complete removal of the stones was found in 41 (85.4%) of the 48 patients with difficult choledocholithiasis. In the remaining 7 patients (14.6%), the stent in any case resulted in clinical improvement. A permanent stent was necessary in 4 patients, enabling safe drainage with no complications.*

*The use of endoscopy for stent placement was effective in all our cases of difficult choledocholithiasis without any complications.*

**RIASSUNTO:** Il trattamento endoscopico della calcolosi biliare "difficile".

B. BELVERDE, S. FRATTAROLI, A. CARBONE, G. VICECONTE

*La calcolosi della via biliare principale (VBP) è una patologia risolvibile con le normali tecniche endoscopiche. In caso di calcolosi difficile, oppure quando non è possibile completare l'estrazione dei calcoli per le loro dimensioni, per il loro numero o per stenosi della VBP, è possibile il posizionamento di un'endoprotesi in plastica ottenendo il drenaggio della bile in tempi veloci.*

*Nei 48 pazienti con coledocolitiasi "difficile" trattati con tecniche endoscopiche d'estrazione, si è dimostrata, già al controllo a 3 mesi, la completa toilette della VBP in 41 (85,4%) di essi.*

*Nei rimanenti 7 pazienti (14,6%) la protesizzazione della VBP ha consentito un miglioramento del quadro clinico. In 4 pazienti si è resa necessaria la protesizzazione definitiva della VBP, ottenendo un drenaggio sicuro della bile, in assenza di sintomatologia.*

*Le metodiche endoscopiche per la protesizzazione della VBP nei casi di calcolosi difficile si sono dimostrate efficaci in tutti i casi trattati con nessuna complicanza legata alla metodica stessa.*

**KEY WORDS:** Common bile duct - Stones - Stent - Endoscopy.  
Via biliare principale - Calcolosi - Stent - Endoscopia.

### Introduction

Choledocholithiasis, or common bile duct stones, is generally treated by endoscopy. In 90-95% of cases, the stones are removed by balloon catheter, Dormia basket or mechanical lithotripsy after sphincterotomy (1-3). Where complete removal is impossible, a plastic stent can be inserted to ensure drainage, avoiding impaction and possible cholangitis (4- 6). The stent thus enables a second endoscopic procedure to be scheduled, with the aim of completing removal of the stones.

In selected cases stent insertion may be the definitive treatment, whether through the patient's choice or dictated by his or her poor medical condition.

This study reports on the use of stents in a caseload of so-called difficult common bile duct stones whose complete removal was not immediately possible.

### Patients and methods

In the period 2007-2010, 1600 endoscopic retrograde cholangiopancreatographies (ERCPs) were carried out, of which 960 (60%) were for common bile duct stones. In 912 (95%) of these, complete clearance of the common bile duct was possible with endoscopic sphincterotomy using standard removal techniques (balloon catheter, Dormia basket, mechanical lithotripsy). In 48 cases (5%) complete removal was not possible. This was due to: size (>2 cm) in 20 cases (Fig. 1); number (>3) in 14 (Fig. 2); bile duct stenosis distal-

ly from the stones in 8 cases; and the patient's serious general conditions, requiring the procedure to be carried out as quickly as possible, in the remaining 6 cases. Twenty-eight of these 48 patients had jaundice.

Patients were treated with the placement of a 9-12 cm long 10-Fr plastic stent. They then underwent treatment with ursodeoxycholic acid 10 mg/kg/day, and ERCP was scheduled after 3 months.

## Results

Signs and symptoms were rapidly resolved after the first ERCP in all patients. Bilirubin values in patients with jaundice dropped quickly and without complications.

Complete removal of the stones by ERCP at the three-month check-up was possible in 41 (85.4%) of the 48 patients. This was carried out by mechanical lithotripsy in 8 cases. In 7 patients (14.6%) complete removal was not possible and the previously inserted stent was replaced to prevent obstruction by biliary sludge.

In 4 cases it was decided to leave the stent permanently due to the patient's general condition and/or choice. One patient underwent an emergency ERCP 240 days after the first stent procedure due to cholangitis caused by obstruction of the stent, which was replaced. Another patient died from unrelated causes. In one patient, complete endoscopic removal of the gallstone was possible after another three months.

## Discussion

The first choice of treatment for choledocholithiasis is undoubtedly endoscopy. Use of ERCP and endoscopic sphincterotomy enable stones to be removed from the common bile duct in around 90-95% of cases, using safe, well-established techniques. However, removal can be more difficult in the case of large stones (>2 cm), staghorn calculi or strictures of the bile duct, even with more sophisticated techniques such as mechanical, laser or extracorporeal shock wave lithotripsy (7, 8, 9).

In such cases, insertion of a stent to ensure bile drainage may be a good therapeutic choice. This procedure is risk-free with no short- or long-term complications, and enables fast resolution of the signs and symptoms of common bile duct stones. In particularly elderly patients or those whose general condition contraindicates an additional endoscopy, the definitive insertion of a stent may be useful.

All our patients benefited from the temporary or permanent insertion of the stent. Where it became dislodged, the problem was resolved by its reinsertion. The stent assures patients a good quality of life, and administration of bile acids can help reduce the volume of the stone (10, 11), although the role and usefulness of treatment with bile acids is not yet fully clear (12). In this study,

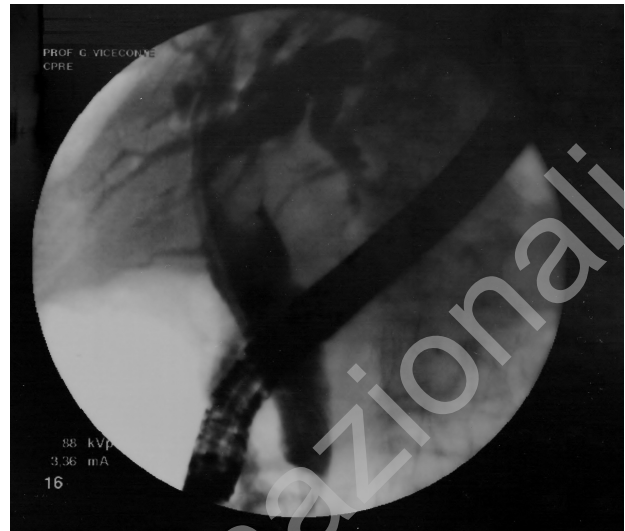


Fig. 1 - Plastic stent in patient with large gallstone (2 x 4 cm) in the common bile duct.

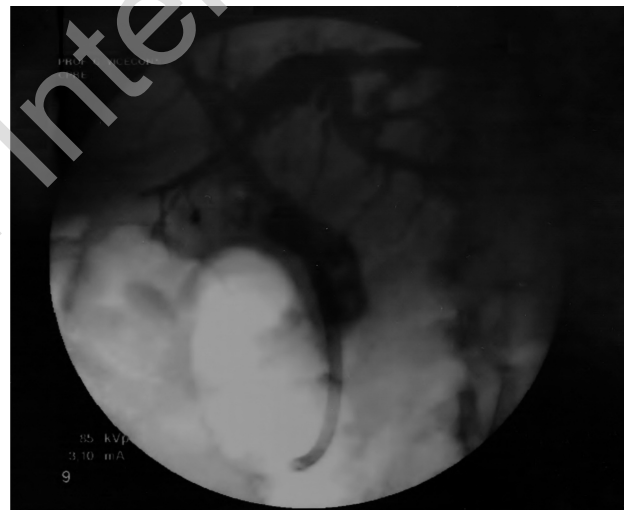


Fig. 2 - Plastic stent in patient with multiple stones in the common bile duct.

endoscopic removal of common bile duct stones was possible in 41 of 48 patients during the first procedure and in 1 patient at follow-up.

## Conclusions

Insertion of a stent for the treatment of difficult cases of choledocholithiasis is an easily performed endoscopic technique. It enables fast bile drainage in all cases and complete endoscopic removal of stones at subsequent follow-ups in most cases (13). Permanent stenting of the common bile duct is performed only in rare cases, but with satisfactory results.

## References

1. Vaira D, Ainley C, Williams S, et al. Endoscopic sphincterotomy in 1000 consecutive patients. *Lancet* 1989; 2:431-3.
2. Lambert ME, Betts CD, Hill J, et al. Endoscopic sphincterotomy: the whole truth. *Br J Surg* 1991; 78:473-6.
3. Freeman ML, Nelson DB, Sherman S, et al. Complications of endoscopic biliary sphincterotomy. *N Engl J Med* 1996; 335:909-18.
4. Chung SCS, Leung JWC, Leong HT, et al. Mechanical lithotripsy of large common bile stones using a basket. *Br J Surg* 1991; 78:1448-50.
5. Li KW, Zhang XW, Ding J, Chen T, Wang J, Shi WJ. A Prospective study of the efficacy of endoscopic biliary stenting on common bile duct stones. *JDig dis* 2009 10(4); 328-31.
6. Kim HJ, Choi HS, Park JH, et al. Factors influencing the technical difficulty of endoscopic clearance of bile duct stones. *Gastrointest Endosc* 2007; 66:1154-60.
7. Jacobs R, Maier M, Kohler B, et al. Peroral laser lithotripsy of difficult intrahepatic and extrahepatic bile duct stones: laser effectiveness using an automatic stone-tissue discrimination system. *Am J Gastroenterol* 1996; 91:468-73.
8. Binmoeller KF, Bruckner M, Thonke F, et al. Treatment of difficult bile duct stones using mechanical, electrohydraulic and extracorporeal shock wave lithotripsy. *Endoscopy* 1993; 25:201-6.
9. Arya N, Nelles SE, Haber GB, et al. Electrohydraulic lithotripsy in 111 patients: a safe and effective therapy for difficult bile duct stones. *Am J Gastroenterol* 2004; 99:2330-4.
10. Chan AC, Ng EK, Chung SC, et al. Common bile duct stones become smaller after endoscopic biliary stenting. *Endoscopy* 1998; 30:356-9.
11. Katsinelos P, Galanis I, Pilpilidis I, et al. The effect of indwelling endoprosthesis on stone size or fragmentation after long-term treatment with biliary stenting for large stones. *Surg Endosc* 2003; 17:1552-5.
12. Han J, Moon JH, Koo HC, et al. Effect of biliary stenting combined with ursodeoxycholic acid and terpene treatment on retained common bile duct stones in elderly patients: a multicenter study. *Am J Gastroenterol* 2009; 104:2418-21.
13. Horiuchi A, Nakayama Y, Kajiyama M, Kato N. Biliary stenting in the management of large or multiple common bile duct stones. *Clinical Endoscopy* 2010; 71:7.