

## Modified patch repair of femoral hernia after inguinal herniorrhaphy

H. KULACOGLU<sup>1</sup>, C. UGURLU<sup>1</sup>, I. OZYAYALI<sup>2</sup>, Z. ERGUL<sup>1</sup>, G. SEKER<sup>1</sup>

**SUMMARY:** Modified patch repair of femoral hernia after inguinal herniorrhaphy.

H. KULACOGLU, C. UGURLU, I. OZYAYALI, Z. ERGUL, G. SEKER

**Background and aim.** *It has been reported that femoral hernias are rather common after a previous repair of inguinal hernia. We herein present a modified patch repair technique for large femoral hernias that develop after a Lichtenstein operation for ipsilateral inguinal hernia.*

**Patients and methods.** *The modified technique for femoral hernia was applied to three patients who had a Lichtenstein repair for inguinal hernia. All patients were male. Hernia sac is dissected completely and sent back into to the preperitoneal space. Special attention should be given to the prevascular component of the sac. It is dissected as deep as possible into the preperitoneal space over the femoral vein. The defect is quite wide in this particular type of femoral hernia following Lichtenstein repair. A prosthetic patch that matches the defect is prepared. The medial edge of the mesh is configured to correspond to the pubic corner and lacunar ligament. The lateral margin of the patch is cut to create several petals for inverting the mesh above and medial to the femoral vein to prevent prevascular herniation. The mesh is secured to inguinal ligament, ilioinguinal tract, lacunar ligament, and Cooper ligament. Few sutures are put on the pubic corner and lacunar ligament.*

**Results.** *One patient was discharged after two hours, other two stayed overnight. Readmission because of seroma development was recorded in two cases where standard polypropylene meshes were used. No complication was observed in the other patient who received lightweight meshes. No early recurrences were recorded after 4, 9, and 30 months.*

**Conclusion.** *Femoral recurrence after previous inguinal hernia repair seems to be a specific entity. It has a prevascular component and the hernia defect can be much larger than that of a primary femoral hernia. A patch repair with infra-inguinal approach can be a valuable alternative with low complication rate.*

**RIASSUNTO:** *Plastica protesica modificata per ernia femorale post-erniorrafia inguinale.*

H. KULACOGLU, C. UGURLU, I. OZYAYALI, Z. ERGUL, G. SEKER

**Introduzione e scopo.** *È documentato che la comparsa di ernia femorale è piuttosto frequente dopo plastica per ernia inguinale.*

**Pazienti e metodi.** *Abbiamo utilizzato una tecnica modificata di plastica protesica femorale in tre pazienti, tutti di sesso maschile, già sottoposti a ernioplastica inguinale secondo Lichtenstein. Il sacco erniario è completamente disseccato e ridotto nello spazio preperitoneale, ponendo particolare attenzione alla sua componente prevascolare, in stretto rapporto con la vena femorale. Il difetto è abbastanza ampio in questo particolare tipo di ernia femorale post-plastica secondo Lichtenstein, pertanto va preparata una mesh calibrata, il cui bordo mediale va ritagliato 'a misura' in rapporto ad angolo pubico e legamento lacunare. Il bordo laterale è invece ritagliato a creare alcuni 'petali' che vanno ad avvolgere, al davanti e medialmente, la vena femorale al fine di prevenire possibili erniazioni prevascolari. La mesh è fissata al legamento inguinale, al tratto ileoinguinale, al legamento lacunare e al legamento di Cooper. Altri punti di sutura sono applicati sull'angolo pubico e sul legamento lacunare.*

**Risultati.** *Un paziente è stato dimesso dopo due ore, gli altri due la mattina del giorno dopo. Nei due casi in cui sono state utilizzate mesh tradizionali in polipropilene si è reso necessario un nuovo ricovero per comparsa di sieroma. Non si sono avute complicanze nel terzo paziente in cui era stata utilizzata una protesi lightweight. Non si sono documentate recidive a 4, 9 e 30 mesi.*

**Conclusione.** *La recidiva femorale post-ernioplastica erniaria appare una patologia specifica, con una componente prevascolare e un difetto che può essere molto più ampio di quello di un'ernia femorale primaria. La riparazione protesica con approccio sottoinguinale può essere una valida alternativa con bassa incidenza di complicanze.*

**KEY WORDS:** Femoral hernia - Mesh - Patch - Lightweight - Local anesthesia - Recurrence.  
Ernia femorale - Mesh - Patch - Lightweight - Anestesia locale - Recidiva.

## Introduction

Femoral hernia consists only 4% of all primary groin hernias (1-3). Surgeons may meet a missed femoral hernia following an inguinal hernia repair (3,4). Therefore,

<sup>1</sup> Diskapi "Yildirim Beyazit" Teaching and Research Hospital, Ankara, Turkey

<sup>2</sup> Ankara Hernia Center, Ankara, Turkey

© Copyright 2012, CIC Edizioni Internazionali, Roma

a complete exploration including femoral canal is recommended. Laparoscopic approach can be a potential solution for missed femoral hernias (5), but majority of inguinal hernias are still repaired with open anterior approach (6).

It was reported that 10% of the recurrences after Lichtenstein repair are femoral (7). Incidence of femoral hernia after inguinal herniorrhaphy is 15-fold greater compared with the spontaneous incidence (2). The pathogenesis is unclear. Professor Kehlet of Danish Hernia Data Base does not think that an inguinal hernia repair per se will provide a disposition for a femoral hernia itself; it is probably an overlooked hernia (personal communication). However, Abrahamson claimed that the upward tension on the inguinal ligament can open up the femoral canal and result in a femoral hernia (4).

McVay's suture repair for femoral hernia was widespread until 1990's, however newer techniques with prosthetic materials are more popular today. We herein present a modified patch repair technique for the repair of large femoral hernias that develops after a previous Lichtenstein operation for ipsilateral inguinal hernia.

## Patients and methods

The modified repair technique was applied to three male patients with femoral hernia following a previous Lichtenstein repair, in different centers, 1, 20, and 59 months ago.

### Novel repair technique

If preoperative evaluation of the patient by physical examination, ultrasound or computed tomography could clarify that the recurrence is not an inguinal herniation at all, an infrainguinal incision is made. If the type of recurrent hernia is still uncertain, a transverse inguinal incision parallel to skin creases should be preferred. Local anesthesia is a good option. It gives the surgeon an opportunity for asking the patient to cough for the exact location of recurrence.

When a femoral recurrence is observed after clinical exam, the aponeurosis of the external oblique muscle is not opened. Dissection is focused on the femoral canal via infra-inguinal approach (Fig. 1). Hernia sac is dissected completely and sent back into to the preperitoneal space. Special attention should be given to the prevascular component of the sac. It is dissected as deep as possible into the preperitoneal space over the femoral vein by protecting the vein (Fig. 2, A,B).

The femoral defect is quite wide in this particular type of femoral hernia and this facilitates the exposure of the structures as seen in preperitoneal approach. Inguinal ligament, ilioinguinal tract, lacunar ligament, and Cooper ligament are easily identified after the reduction of the sac.

A prosthetic patch that matches the defect is prepared. The medial edge of the mesh is configured to correspond to the pubic corner and lacunar ligament. The lateral margin of the patch is cut to create several petals for inverting the mesh above and medial to the femoral vein to prevent prevascular herniation (Fig. 3). The mesh is secured to the structures mentioned above with separate polypropylene sutures. It is crucial to put secure sutures on the Cooper ligament. Lower line sutures are started from Cooper ligament. A few sutures are put on the pubic corner and lacunar ligament (Fig. 4). An alternative lower edge suturing can also be tried: mesh is laid caudally from Cooper ligament and a 1 cm safety margin is inverted through the preperitoneal space. It may be better to leave the sutures inside. With this technique, the mesh can act more similar to a classic preperitoneal mesh. Inferior-lateral petals of the mesh are inverted on the medial border of the vein. After inverting the superior-medial petals on the prevascular herniation site, upper line sutures are started to put. It is better to leave a 1 cm inverted safety margin at

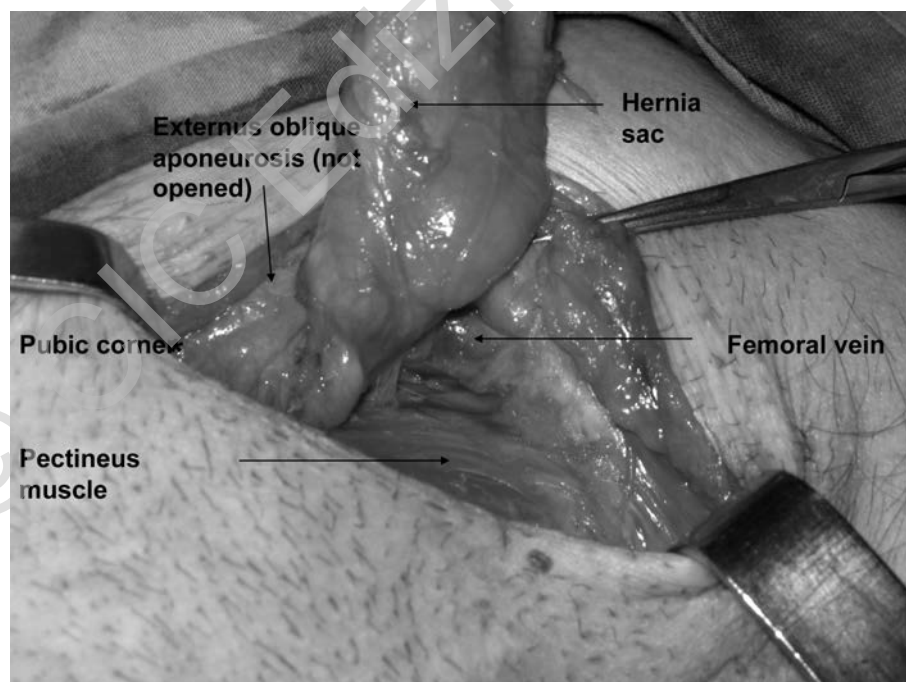


Fig. 1 - A large femoral hernia with an prevascular component was approached via an inguinal incision without opening external oblique aponeurosis. The sac extends to the pubic corner from the femoral vein.

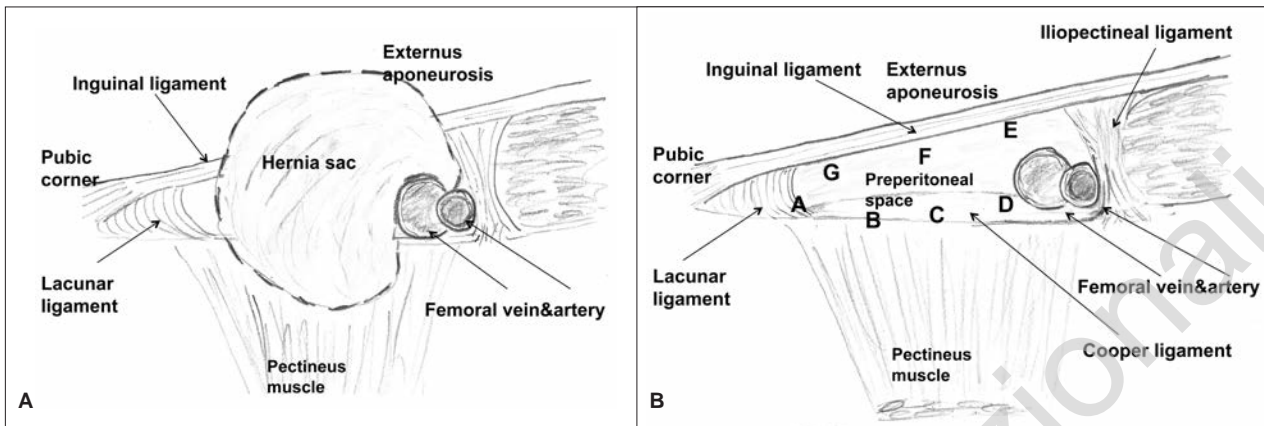


Fig. 2 - Schematic drawing of the operation field before (A) and after (B) the reduction of the hernia sac.

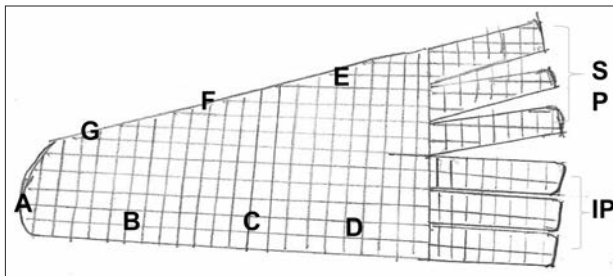


Fig. 3 - Modified patch. Medial edge is configured to correspond to the pubic corner and lacunar ligament. A to G points correspond the same points in Figure 2B for securing the mesh with interrupted sutures. Lateral margin is cut to create several petals for inverting the mesh above and medial to the femoral vein to prevent prevascular herniation. Superior petals (SP) and inferior petals (IP) are bent around the femoral vein.

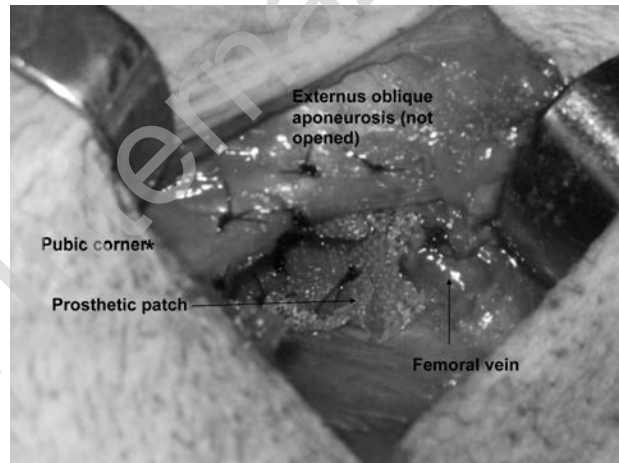


Fig. 4 - Patch has been secured with interrupted polypropylene sutures.

the upper edge of the patch as well. Several interrupted sutures are secured onto the inguinal ligament and iliopubic tract (Fig. 4).

## Results

The diameters of femoral hernia defects were 45x30, 40x25, 60x35 mm, respectively (Table 1). Two of 3 hernias had a prevascular component. Standard weight pure polypropylene material was used in one repair, whereas lightweight pure polypropylene mesh was used in one, and a composite polypropylene plus polyglactine lightweight mesh in another. A closed system suction drain was left in-situ.

Local anesthesia gave an opportunity for same day discharge in one case, other two patients stayed overnight. The drain removal time was 2 days. Two readmissions because of seroma development were recorded. Both were observed when a pure polypropylene patch was used. One seroma was resolved in 2 weeks, the other seroma was larger and aspiration was required twice. The drainage decreased to 40 ml on 10<sup>th</sup> postoperative day. Microbial cultures of the obtained fluid were negative. Seroma resolved completely within 3 weeks.

TABLE 1 - PATIENT DEMOGRAPHICS FOR NOVEL REPAIR.

Gender	Age (years)	Preoperative diagnosis	Previous repair (interval, month)	Anesthesia	Incision diameters (mm)	Defect	Mesh	Follow-up (months)
Male	31	Yes	Lichtenstein (1)	Local	Inguinal	45x30	Standard PP <sup>a</sup>	30
Male	38	Yes	Lichtenstein (20)	Local	Infra-inguinal	40x25	Composite <sup>b</sup>	9
Male	79	No	Lichtenstein (59)	Local	Inguinal	60x35	Lightweight PP <sup>a</sup>	4

<sup>a</sup> pure polypropylene; <sup>b</sup> polypropylene plus polyglactone

A complete follow-up and physical examination at the clinic was achieved for all three patients 4, 9, and 30 months. No early recurrence was recorded. None of the patients complained of chronic pain or foreign body feeling.

## Discussion

Mainly two prosthetic repairs are used for femoral hernias: patch repair with inguinal approach and plug application with infra-inguinal approach (3). One of the patch repairs is a modification of Lichtenstein prosthetic repair that was first introduced by Amid (8). Plug repair seems to be an easier alternative (9), but some major complications due to mesh migration have been reported (10,11). Also, plugs may often shrink to result in recurrence in hernias with large defects (10).

A femoral hernia after an inguinal hernia repair is a rather different entity from a primary one. If a suture repair was previously performed it might be better to open inguinal floor and employ a modified Lichtenstein repair. This will not only cure the femoral hernia but may also recognize or prevent an inguinal recurrence. If a prosthetic repair was done on the first operation and preoperative diagnosis is a femoral recurrence an infra-inguinal repair may be warranted. In our experience, femoral recurrences after inguinal hernia repairs have very large defects which occupy a wide area from the femoral vein to the pubic corner. Therefore, an ordinary plug would be inadequate to cover the defect. It seems reasonable to cover the defect with a patch. Inverting the mesh edges through the preperitoneal space can act as a classical preperitoneal mesh repair. This choice is expected to prevent the recurrence efficiently and not to cause complications reported after plug applications.

Although suture repairs have generally been accused for femoral hernia development after an inguinal hernia repair (12), Mikkelsen and colleagues stated that the

use of mesh might hypothetically cause less traction and widening of the femoral canal, but did not reduce the risk of developing a femoral hernia (2). Some other mechanisms may also contribute to this situation. According to the modern herniology principles all groin hernias arise from the three windows of the same opening: the myopectineal orifice. Femoral canal is left as the most possible way for herniation when an anterior prosthetic reinforcement has been applied to cover direct and indirect hernia sites. Mesh will sustain its own mechanical resistance on the inguinal floor, whereas other part of myopectineal orifice will weaken with time. This process can act together with anatomical distortions secondary to inguinal repair to develop a femoral hernia especially in individuals who are prone to diffuse fascial weakness.

Femoral recurrences after inguinal hernia repair frequently contain a prevascular component (12). Preformed plugs and anterior sublay meshes can be used for prevascular hernias (3,12). A recent prospective study revealed that preperitoneal patch repair is superior to infra-inguinal plug application in respect of recurrence and foreign body sensation rates (3). In that study, the maximum diameter of the hernia ring was less than 2.5 cm. Obviously, no plugs can cover larger defects such as in 3 cases we present here. The modified technique described in this paper may be a good alternative for larger hernia defects. Applying a prosthetic patch without re-opening the inguinal canal will also avoid the risk of injury to the spermatic cord.

In conclusion, femoral recurrence after previous inguinal hernia repair seems to be a specific entity. It is more common in men, frequently has a prevascular component and the hernia defect may be much larger than that of a primary femoral hernia. A patch repair with infra-inguinal approach can be a valuable alternative with low complication rate. The merit of this modified technique will be evaluated better by obtaining larger number of patients with longer follow-up periods.

## References

1. Cirignotta F, Manconi M, Mondini S, Buzzi G, Ambrosetto P. Wernicke-Korsakoff encephalopathy and polyneuropathy after gastroplasty for morbid obesity: report of a case. *Arch Neurol* 2000;57(9):1356-9.
2. Yoon CK, Chang MH, Lee DC. Wernicke-Korsakoff syndrome associated with hyperemesis gravidarum. *Korean J Ophthalmol* 2005;19(3):239-42.
3. Wilson JD. Vitamin deficiency and excess. In: Isselbacher KJ, Braunwald E, Wilson JD, eds. *Harrison's principles of internal medicine*, 13th ed. New York: McGraw-Hill, 1994; v. 1. Chap. 77.
4. Shin RK, Galetta SL, Imbesi SG. Wernicke encephalopathy. *Arch Neurol* 2000; 57(3):405.
5. Oczkowski WJ, Kertesz A. Wernicke's encephalopathy after gastroplasty for morbid obesity. *Neurology* 1985;35(1):99-101.
6. Marcus R, Coulston AM. Water soluble vitamins: the vitamin B complex and ascorbic acid. In: Hardman JG, Limbird LE, Gilman AG, editors. *Goodman and Gilman's the Pharmacological Basis of Therapeutics*. 10th ed. New York: McGraw-Hill, 2001:1753-71.
7. Haid RW, Gutmann L, Crosby TW. Wernicke-Korsakoff encephalopathy after gastric placcation. *JAMA* 1982;247(18):2566-7.
8. Feit H, Glasberg M, Ireton C, Rosenberg R, Thal E. Peripheral neuropathy and starvation after gastric partitioning for morbid obesity. *Ann Intern Med* 1982;96(4):453-5.

9. Hahn J, Berquist W, Alcorn D, Chamberlain L, Bass D. Wernicke encephalopathy and beriberi during total parenteral nutrition attributable to multivitamin infusion shortage. *Pediatrics* 1998;101(1):E10.
10. Nadel AM, Burger PC. Wernicke encephalopathy following prolonged intravenous therapy. *JAMA* 1976;235(22):2403-5.
11. Nolli M, Barbieri A, Pinna C, Pasetto A, Nicosia F. Wernicke's encephalopathy in a malnourished surgical patient: clinical features and magnetic resonance imaging. *Acta Anaesthesiol Scand* 2005;49(10):1566-70.
12. Gallone L, Galliera M. *Sindrome dell'ansa afferente*. Ed Ambrosiana, Chirurgia VII ed; 2005;1432-3.
13. Beveridge CJ, Zammit-Maempel I. Afferent loop obstruction: CT appearances of an unusual cause of acute pancreatitis. *Clin Radiol* 1999;54(3):188-9.
14. Swayne LC, Love MB. Computed tomography of chronic afferent loop obstruction: a case report and review. *Gastrointest Radiol* 1985;10(1):39-41.
15. Kuwabara Y, Nishitani H, Numaguchi Y, Kamoi I, Matsuura K, Saito S. Afferent loop syndrome. *J Comput Assist Tomogr* 1980;4(5):687-9.
16. Eboué C, Carlier-Guérin C, de La Sayette V, Grall JY, Herlicoviez M.. A rare complication of vomiting in pregnancy: Wernicke's encephalopathy. *J Gynecol Obstet Biol Reprod (Paris)* 2006;35(8 Pt 1):822-5.
17. Shimomura T, Mori E, Hirono N, Imamura T, Yamashita H. Development of Wernicke-Korsakoff syndrome after long intervals following gastrectomy. *Arch Neurol* 1998;55(9): 1242-5.
18. Okino S, Sakajiri KI, Fukushima K, Ide Y, Takamori M. A case of Wernicke-Korsakoff syndrome caused by gastrojejunostomy-specific findings of MRI and SPECT. *Rinsho Shinkeigaku* 1993;33(5):530-4.
19. Karapanayiotides T, Zaloni I, Thomaidis T. Delayed development of Wernicke encephalopathy after gastrectomy. *Arch Neurol*. 2006;63(7):1026-7.