

Pancreatic pseudocyst: case report and short literature review

E. GAGLIANO, M.A. BARBUSCIA, A. TONANTE, F. TARANTO, D. PAPARO,
E. PAPALIA, R. CASCIO, C. DAMIANO, G. STURNIOLO

SUMMARY: Pancreatic pseudocyst: case report and short literature review.

E. GAGLIANO, M.A. BARBUSCIA, A. TONANTE, F. TARANTO,
D. PAPARO, E. PAPALIA, R. CASCIO, C. DAMIANO, G. STURNIOLO

We report a case of pancreatic pseudocyst secondary to acute necrotizing pancreatitis treated with open cystogastrostomy. Following a literature review, we stress the enormous benefits offered by modern diagnostic techniques, and especially imaging techniques, for the diagnosis and monitoring of this disease. Treatment should be delayed for at least six weeks, following which the drainage by open surgery offers the best results and lowest morbidity and mortality, followed by laparoscopy and endoscopy, indicated in particular cases and in patients where open surgery is contraindicated.

RIASSUNTO: Le pseudo cisti pancreatiche: case report e revisione della letteratura.

E. GAGLIANO, M.A. BARBUSCIA, A. TONANTE, F. TARANTO,
D. PAPARO, E. PAPALIA, R. CASCIO, C. DAMIANO, G. STURNIOLO

Viene riportato un caso di pseudocisti pancreatica da pancreatite acuta necrotico-emorragica risolto dopo cisto-gastrostomia a cielo aperto. Gli Autori, dopo un esame della letteratura, sottolineano i grandi vantaggi apportati dalle moderne indagini diagnostiche nella diagnosi e nel monitoraggio di questa patologia. Tra le metodiche di trattamento consigliate, dopo un tempo di attesa di almeno sei settimane, si rileva la superiorità del drenaggio in open per risultati, morbilità e mortalità, seguito dalla laparoscopia e dall'endoscopia, che trovano tuttavia al momento precisa indicazione in casi particolari e nei pazienti ad alto rischio per la chirurgia open.

KEY WORDS: Pancreatic pseudocyst - Internal drainage - Endoscopy.
Pseudocisti pancreatica - Drenaggio interno - Endoscopia.

Introduction

Most cases of pancreatic pseudocyst are a delayed complication of acute pancreatitis. Following a recent case treated with open surgery, we decided to perform a literature review to establish the principles currently adopted for the diagnosis and treatment of this condition.

Case report

A 63-year-old woman was admitted to our department for acute necrotizing pancreatitis, associated with gallstones, brought under control with medical treatment. Diagnostic procedures revealed the subsequent formation of a large pancreatic pseudocyst, whose evolution was monitored over six weeks with ultrasound and CT

(Fig. 1). By this time the cyst appeared to have stabilized with formation of a thick fibrous wall. It was around 12 cm in size, displaced the stomach and slowed emptying. The patient complained of digestive troubles and epigastric bloating, but was not in pain and had no other related conditions.

Given the considerable size of the cyst and its compression of the stomach, it was agreed with the patient to treat it with open surgery, consisting in cholecystectomy and internal derivation of the cyst with the posterior wall of the gastric antrum (cystogastrostomy) (Fig. 2). The anastomosis was created at bottom of the stomach to facilitate drainage of the contents of the cyst into the stomach. The cystic cavity was cleaned and a nasogastric tube inserted as a precautionary measure.

Post-operative course was regular and the patient was discharged after eight days. Follow-up CT on day 30 demonstrated the almost total regression of the cyst and a complete disappearance of digestive disorders.

Discussion

Pancreatic pseudocysts are fluid collections secondary to inflammation with a fibrous wall (no epithelial lining) containing pancreatic tissue degradation products, i.e.

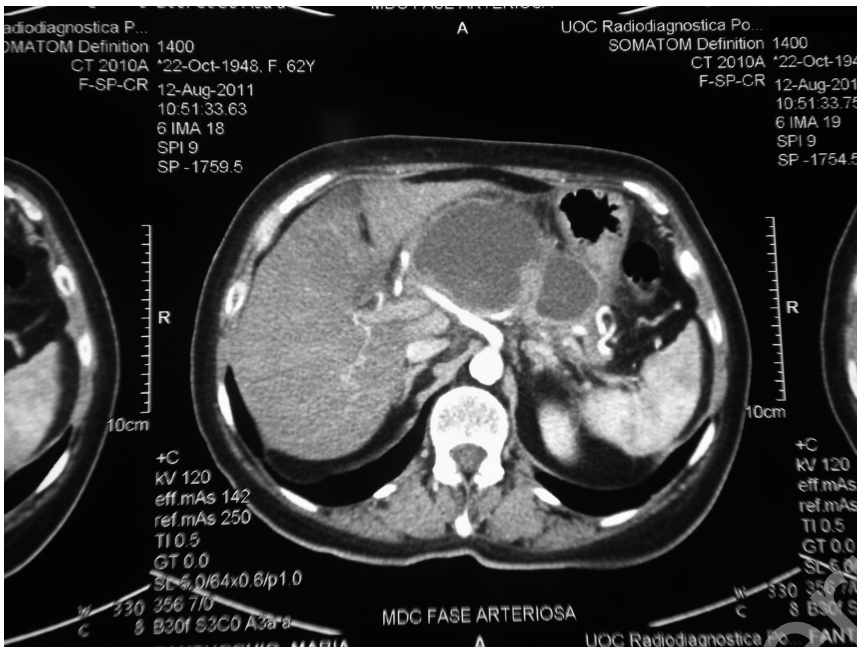


Fig. 1 - The large pancreatic pseudocyst revealed by CT.



Fig. 2 - Internal derivation of the cyst with the posterior wall of the gastric antrum (cystogastrostomy).

necrotic debris, blood degradation products and pancreatic juice. They are a delayed complication of acute or chronic pancreatitis or, rarely, pancreatic trauma.

Epidemiology

The overall incidence of pancreatic pseudocyst is low, at between 0.5 and 1 per 100,000 inhabitants. The incidence varies with the etiology, from 5 to 16% after acute pancreatitis and 20 to 40% in chronic pancreatitis (1-7). The highest incidence is seen in chronic alcoholic pancreatitis, with reported values of up to 78% of cases in areas with high levels of alcohol misuse. In cases of acute pancreatitis, pseudocysts are reported in 6-36% of cases secondary to gallstones, 3-8% of post-operative or post-traumatic cases and 6-20% of idiopathic pancreatitis and, rarely, after pancreatitis secondary to hyperlipidaemia (5,8-11).

Classification

The classification of pancreatic pseudocysts is currently based on pathogenetic criteria such as the Atlanta classification that subdivides pseudocysts into four types:

- A) Acute fluid collection, occurring early in the course of acute pancreatitis and lacking a wall of granulomatous or fibrous tissue;
- B) Acute pseudocyst, surrounded by fibrous or granulomatous tissue secondary to acute pancreatitis or trauma;
- C) Chronic pseudocyst, arising in chronic pancreatitis and without a preceding episode of acute pancreatitis;
- D) Pancreatic abscess: an intra-abdominal collection of pus in the proximity of the pancreas with little or no necrosis resulting from acute or chronic pancreatitis or trauma.

Another classification, proposed in 1991 by D'Egi-

dio and Schein, is based on the underlying condition (acute, chronic or traumatic), the anatomy of the pancreatic duct and the presence of duct-pseudocyst communication (5,12-14).

Differential diagnosis

Differential diagnosis should take into account cystic pancreatic tumor, which has a similar appearance but whose treatment obviously differs, given that it is a neoplastic disease (15-18). A cystic formation observed after acute pancreatic necrosis or during acute pancreatitis is undoubtedly a pseudocyst. When there is no previous history of pancreatic disease (19-21), a cystic tumor is very probable.

Pathology

In the early phase, pseudocysts always communicate with the pancreatic ducts, but this connection tends to disappear as the cyst "matures". Non-communication is essential if the cyst is to resolve spontaneously (22-25). In the late stage, a connection between the pancreatic duct and the cystic cavity is found in over half of cases.

Pseudocysts may be single or multiple and are found in all segments of the pancreas, but usually the head or tail. However, it is not uncommon to find them outside the pancreas, such as in the abdominal cavity or pelvis, due to intraperitoneal spread of the pancreatic juices and necrotic/hemorrhagic debris during the acute phase (26-30).

Clinical signs and complications

In most cases, pancreatic pseudocysts are non-symptomatic and are an occasional finding during follow-up monitoring of the evolution of acute pancreatitis. In around a third of cases they resolve spontaneously, as long as there is no communication with the pancreatic ducts. If they evolve and increase in size, they become symptomatic through compression of the adjacent organs (stomach, duodenum and bile duct), with the main signs being postprandial epigastric bloating, early satiety, nausea and vomiting. They may also evolve towards suppurative, rupture, fissure or deep vein thrombosis, intracystic or gastrointestinal bleeding or fistulization into the alimentary tract. If the latter takes place in the higher part (stomach, duodenum, jejunum), it is likely to resolve spontaneously. However, a fistula with the colon, due to the septic content of the latter, will lead to a superinfection of the cyst, requiring immediate surgery.

Diagnostic protocol

Diagnostic procedures should include medical history, laboratory tests, CEA testing, cytological, chemical and microbiological examination of the cyst contents and modern imaging techniques, which provide useful information on the size, location and walls of the cyst

and its contents. However, it is not uncommon for it to be impossible to establish the features distinguishing pseudocysts from cystic tumors. The most commonly used imaging procedures are transabdominal ultrasound, endoscopic ultrasound, CT, endoscopic cholangiopancreatography, and cholangio-MRI.

Treatment of pseudocysts

The first approach to treating pseudocysts is conservative, involving waiting, given that they clear up spontaneously with time in over half of cases. Traditional guidelines recommend monitoring them for at least six weeks. If the cyst tends to diminish, or at least not become larger, in this period, its evolution should be monitored over time. However, if it increases in size, its content changes and/or it becomes symptomatic, it should be treated to avoid the need for emergency abdominal surgery due to infection, suppuration, rupture, hemorrhage, etc.

Drainage - Surgeons unanimously agree on the need to treat pseudocysts larger than 6-7 cm, even if there are no complications. However, there is no unanimous agreement on how to treat them, and various methods are proposed. **Percutaneous drainage** - This is the least invasive method. However, it is associated with a high failure rate >30%, as it can lead to infection of the cyst, given that the drainage catheter has to be left in situ for long periods and does not always ensure complete emptying of the cyst (15,11,24,31-33). It is contraindicated if any communication between the pancreatic ducts and the cyst is suspected. However, it is indicated in some specific cases where surgical drainage is not practicable, such as in patients in a very poor general condition or who refuse surgery, in rapidly evolving or infected pseudocysts still without a solid wall and in pseudocysts located in unusual places. **Endoscopic drainage** - Enables the creation of a communication between the cyst and the stomach. This technique also has a high failure rate, due to recurrence, sepsis, bleeding, etc. (2,20,23,34-36). Transpapillary endoscopic drainage is particularly indicated where the pseudocyst communicates with the pancreatic duct. Following sphincterotomy, the cannula is introduced by guide wire through the pancreatic duct into the pseudocyst (37,38,40-42).

Surgical techniques

Surgical treatment of pseudocyst involves derivation or resection, depending on its location and nature (43-48). Resection depends on the location: resection of the cyst if it is outside the pancreas (pedunculated pseudocyst) and pancreatic resection in cases of caudal pseudocyst. Derivative surgery enables the creation of a permanent

passage between the cyst and the digestive tract (stomach, duodenum or jejunal loop).

The most common method, and our preferred technique, is cystogastrostomy. This involves connection of the pseudocyst to the posterior wall of the stomach by the antrum. Before beginning, it should be established that the cyst wall consists of fibrotic tissue, as this provides a good anchor for the sutures and enables a connection to be created between the wall of the pseudocyst and the posterior wall of the stomach, to ensure good drainage. Absorbable sutures are used and bleeding should be controlled. After thorough cleaning of the cyst cavity, insertion of a nasogastric tube is recommended.

Pseudocysts complicated by suppuration or rupture, especially in cases of "immature" cysts or where the wall is still thin and fragile, are more complex. In such cases, external drainage with suitable positioned large tubes is good practice. If the flow of pancreatic juices does not dry up, a fistula will develop. This may resolve sponta-

neously or require surgery in due course involving internal derivation.

Conclusions

Modern diagnostic techniques have significantly improved the diagnosis and monitoring of pancreatic pseudocysts. Open surgery is the traditional treatment, associated with a high success rate and low mortality and morbidity. Encouraging results have been reported for laparoscopy, but long-term follow-up has confirmed the superior results achieved with open surgery. Endoscopy is another valid alternative, especially in patients where open surgery is contraindicated. Transpapillary drainage is a good option in cases where the pseudocyst communicates with the pancreatic duct. However, open surgery is still considered the gold standard for the treatment of most cases of pancreatic pseudocyst.

References

1. Ammann RW, Akovbiantz A, Largiader F, Schueler G. Course and outcome of chronic pancreatitis. Longitudinal study of a mixed medical-surgical series of 245 patients. *Gastroenterology* 1984;86(5 Pt 1):820-8.
2. Barthet M, Sahel J, Bodiou-Bertei C, Bernard JP. Endoscopic transpapillary drainage of pancreatic pseudocysts. *Gastrointest Endosc* 1995;42:208-13.
3. Bradley EL, Gonzalez AC, Clements JL, Jr. Acute pancreatic pseudocysts: incidence and implications. *Ann Surg* 1976;184:734-7.
4. Gouyon B, Levy P, Rusznievski P, Zins M, Hammel P, Vilgrain V, et al. Predictive factors in the outcome of pseudocysts complicating alcoholic chronic pancreatitis. *Gut*. 1997;41:821-5.
5. Kolars JC, Allen MO, Ansel H, Silvis SE, Vennes JA. Pancreatic pseudocysts: clinical and endoscopic experience. *Am J Gastroenterol* 1989;84:259-64.
6. Monkemuller KE, Kahl S, Malfertheiner P. Endoscopic therapy of chronic pancreatitis. *Dig Dis* 2004;22:280-91.
7. Sica GT, Braver J, Cooney MJ, Miller FH, Chai JL, Adams DF. Comparison of endoscopic retrograde cholangiopancreatography with MR cholangiopancreatography in patients with pancreatitis. *Radiology* 1999;210:605-10.
8. Laxson LC, Fromkes JJ, Cooperman M. Endoscopic retrograde cholangiopancreatography in the management of pancreatic pseudocysts. *Am J Surg* 1985;150:683-6.
9. Lehman GA. Pseudocysts. *Gastrointest Endosc* 1999;49(3 Pt 2):S81-S84.
10. Sankaran S, Walt SJ. The natural and unnatural history of pancreatic pseudocysts. *Br J Surg* 1975;62:37-44.
11. Warshaw AL, Rattner DW. Timing of surgical drainage for pancreatic pseudocyst. Clinical and chemical criteria. *Ann Surg* 1985;202:720-4.
12. Brandwein SL, Farrell JJ, Centeno BA, Brugge WR. Detection and tumor staging of malignancy in cystic, intraductal, and solid tumors of the pancreas by EUS. *Gastrointest Endosc* 2001;53:722-7.
13. Elliott DW. Pancreatic pseudocysts. *Surg Clin North Am* 1975;55:339-62.
14. Polakow J, Ladny JR, Serwatka W, Walecki J, Puchalski Z, Czech B. Percutaneous fine-needle pancreatic pseudocyst puncture guided by three-dimensional sonography. *Hepatogastroenterology* 2001;48:1308-11.
15. Adams D, Anderson MC. Percutaneous catheter drainage compared with internal drainage in the management of pancreatic pseudocyst. *Ann. Surg* 1992;215:571-6; discussion 576-8.
16. Andrén-Sandberg A, Maleckas A. Pancreatic pseudocysts. Diagnosis, treatment and results in the 2003s. A literature study aiming at evidence based surgery. BIM Publishing 2003.
17. Balthazar EJ, Freeny PC, vanSonnenberg E. Imaging and intervention in acute pancreatitis. *Radiology* 1994;193:297-306.
18. Barthet M, Bugallo M, Moreira LS, Bastid C, Sastre B, Sahel J. Management of cysts and pseudocysts complicating chronic pancreatitis. A retrospective study of 143 patients. *Gastroenterol Clin Biol* 1993;17:270-6.
19. Bhattacharya D, Ammori BJ. Minimally invasive approaches to the management of pancreatic pseudocysts: review of the literature. *Surg Laparosc Endosc Percutan Tech* 2003;13:141-8.
20. Binmoeller KE, Seifert H, Walter A, Soehendra N. Transpapillary and transmural drainage of pancreatic pseudocysts. *Gastrointest Endosc* 1995;42:219-24.
21. Brugge WR, Lewandrowski K, Lee-Lewandrowski E, Centeno BA, Szydlo T, Regan S, et al. Diagnosis of pancreatic cystic neoplasms: a report of the cooperative pancreatic cyst study. *Gastroenterology* 2004;126:1330-6.
22. Brugge WR. Approaches to the drainage of pancreatic pseudocysts. *Curr Opin Gastroenterol* 2004;20:488-92.
23. Cantasdemir M, Kara B, Kantarci F, Mihmanli I, Numan F, Er-

- guney S. Percutaneous drainage for treatment of infected pancreatic pseudocysts. *South Med J* 2003;96:136-40.
24. Catalano MF, Geenan JE, Schmalz MJ, Johnson GK, Dean RS, Hogan WJ. Treatment of pancreatic pseudocysts with ductal communication by transpapillary pancreatic duct endoprosthesis. *Gastrointest Endosc* 1995;42:214-18.
 25. Chak A. Endosonographic-guided therapy of pancreatic pseudocysts. *Gastrointest Endosc* 2000;52(6 Suppl):S23-S27.
 26. Crass RA, Way LW. Acute and chronic pancreatic pseudocysts are different. *Am J Surg* 1981;142:660-3.
 27. D'Egidio A, Schein M. Pancreatic pseudocysts: a proposed classification and its management implications. *Br J Surg* 1991;78:981-4.
 28. Grace PA, Williamson RC. Modern management of pancreatic pseudocysts. *Br J Surg* 1993;80:573-81.
 29. Gress F, Gottlieb K, Cummings O, Sherman S, Lehman G. Endoscopic ultrasound characteristics of mucinous cystic neoplasms of the pancreas. *Am J Gastroenterol* 2000;95:961-5.
 30. Heider R, Meyer AA, Galanko Ja, Behrns KE. Percutaneous drainage of pancreatic pseudocysts is associated with a higher failure rate than surgical treatment in unselected patients. *Ann Surg* 1999;229:781-7; discussion 787-9.
 31. Jensen AR, Matzen P, Malchow-Moller A, Christofferson I. Pattern of pain, duct morphology, and pancreatic function in chronic pancreatitis. A comparative study. *Scand J Gastroenterol* 1984;19:334-8.
 32. Rohrmann CA, Silvis SE, Vennes JA. Evaluation of the endoscopic pancreatogram. *Radiology* 1974;113:297-304.
 33. Varghese JC, Masterson A, Lee MJ. Value of MR pancreatography in the evaluation of patients with chronic pancreatitis. *Clin Radiol* 2002;57:393-401.
 34. Nealon WH, Townsend CM, Jr, Thompson JC. Preoperative endoscopic retrograde cholangiopancreatography (ERCP) in patients with pancreatic pseudocyst associated with resolving acute and chronic pancreatitis. *Ann Surg* 1989;209:532-8; discussion 538-40.
 35. Newell KA, Liu T, Aranha GV, Prinz RA. Are cystgastrostomy and cystjejunostomy equivalent operations for pancreatic pseudocysts? *Surgery* 1990;108:635-9; discussion 639-40.
 36. Rosso E, Alexakis N, Ghaneh P, Lombard M, Smart HL, Evans J, et al. Pancreatic pseudocyst in chronic pancreatitis: endoscopic and surgical treatment. *Dig Surg* 2003;20:397-406.
 37. Cooperman AM. Surgical treatment of pancreatic pseudocysts. *Surg Clin North Am* 2001;81:411-19, xii.
 38. Sanfey H, Aguilar M, Jones RS. Pseudocysts of the pancreas, a review of 97 cases. *Am Surg* 1994;60:661-8.
 39. Nealon WH, Walser E. Main pancreatic ductal anatomy can direct choice of modality for treating pancreatic pseudocysts (surgery versus percutaneous drainage) *Ann Surg* 2002;235:751-8.
 40. Sugawa C, Walt AJ. Endoscopic retrograde pancreatography in the surgery of pancreatic pseudocysts. *Surgery* 1979;86:639-47.
 41. Usatoff V, Brancatisano R, Williamson RC. Operative treatment of pseudocysts in patients with chronic pancreatitis. *Br J Surg* 2000;87:1494-9.
 42. Walt AJ, Bouwman DL, Weaver DW, Sachs RJ. The impact of technology on the management of pancreatic pseudocyst. Fifth Annual Samuel Jason Mixter Lecture. *Arch Surg* 1990;125:759-63.
 43. Kloppel G. Pseudocysts and other non-neoplastic cysts of the pancreas. *Semin Diagn Pathol* 2000;17:7-15.
 44. London NJ, Neoptolemos JP, Lavelle J, Bailey I, James D. Serial computed tomography scanning in acute pancreatitis: a prospective study. *Gut* 1989;30:397-403.
 45. Maringhini A, Uomo G, Patti R, Rabitti P, Termini A, Cavallera A, et al. Pseudocysts in acute nonalcoholic pancreatitis: incidence and natural history. *Dig Dis Sci* 1999;44:1669-73.
 46. Nealon WH, Townsend CM, Jr, Thompson JC. Preoperative endoscopic retrograde cholangiopancreatography (ERCP) in patients with pancreatic pseudocyst associated with resolving acute and chronic pancreatitis. *Ann Surg* 1989;209:532-8; discussion 538-40.
 47. Pitchumoni CS, Agarwal N. Pancreatic pseudocysts. When and how should drainage be performed? *Gastroenterol Clin North Am* 1999;28(3):615-39.
 48. VanSonnenberg E, Wittich GR, Casola G, Brannigan TC, Karnel F, Stabile BE, et al. Percutaneous drainage of infected and noninfected pancreatic pseudocysts: experience in 101 cases. *Radiology* 1989;170(3 Pt 1):757-61.