

Simultaneous volvulus of the transverse and sigmoid colon. Case report

G. LIANOS, E. IGNATIADOU, E. LIANOU, Z. ANASTASIADI, M. FATOUROS

SUMMARY: Simultaneous volvulus of the transverse and sigmoid colon. Case report.

G. LIANOS, E. IGNATIADOU, E. LIANOU, Z. ANASTASIADI, M. FATOUROS

Introduction. Volvulus of transverse colon is rare when compared to cecal and sigmoid volvulus. Cases involving simultaneous volvulus of the transverse colon and another colonic segment are extremely rare.

Case report. We report a rare case of simultaneous sigmoid and transverse colon volvulus in a 82-year-old Caucasian female

Conclusion. Volvulus is a well recognized cause of large bowel obstruction. The development of transverse and sigmoid volvulus in the same patient is extremely rare. Though rare this possibility must always be considered in the differential diagnosis, when dealing with recurrent intermittent abdominal pain or acute intestinal obstruction.

RIASSUNTO: Concomitante volvolo del colon trasverso e del sigma. Caso clinico.

G. LIANOS, E. IGNATIADOU, E. LIANOU, Z. ANASTASIADI, M. FATOUROS

Introduzione. Il volvolo del colon trasverso è una condizione clinica rara se viene comparata con il volvolo del cieco e del sigma. Casi clinici con concomitante volvolo del colon trasverso e di altro segmento del colon sono molto rari.

Caso clinico. Riportiamo il raro caso di concomitante volvolo del sigma e del colon trasverso in una anziana di 82 anni.

Conclusione. Come è noto, il volvolo può causare ostruzione del grosso intestino. Il concomitante volvolo del colon trasverso e del sigma è una situazione clinica molto rara. Anche se rara, questa possibilità deve essere sempre considerata nella diagnosi differenziale, quando si deve valutare il dolore addominale intermittente o l'ostruzione acuta intestinale.

**KEY WORDS: Volvulus - Transverse colon - Obstruction.
Volvolo - Colon trasverso - Ostruzione.**

Introduction

Colonic volvulus is the axial twisting of the colon on its vascular pedicle. The most common site is the sigmoid colon (75%) followed by the cecum (22%). Rare sites of colonic volvulus include the transverse colon (about 2%) and the splenic flexure (1-2%) (1-3). A double transverse and sigmoid colon volvulus is an extremely rare situation (4-6). To our knowledge, few reports on simultaneous sigmoid and transverse colon have been pu-

blished to date. We share our experience in successfully treatment of such a unique case.

Case report

A 82-year-old Caucasian woman was admitted to the emergency department of the University Hospital of Ioannina due to abdominal pain, absolute constipation and abdominal distention of 8 days duration.

Clinical examination revealed no pyrexia, heart rate at 80 per minute and normal blood pressure. Upon physical examination, a grossly distended abdomen with no rebound was revealed. On auscultation abdominal sounds were absent. Rectal examination showed an empty rectum. The emergent laboratory tests revealed as follow: WBC: 6910/mm³, hemoglobin at 13,5 g/dl, c-reactive protein was at 1 mg/l, creatinine, electrolytes and liver function test results were normal. The abdominal plan X-ray showed massively dilated loops of large bowel (Fig. 1). The admission chest radiography showed elevation of both hemidiaphragms (Fig. 2). The urgent CT showed massively dilated large bowel (Fig. 3).

Laparotomy was performed in general anesthesia on the day of

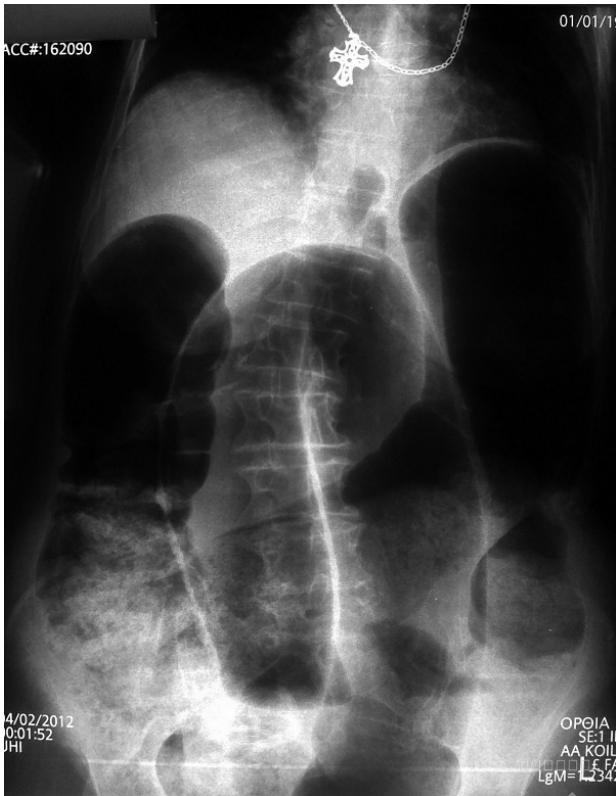


Fig. 1 - Abdominal radiography with massively dilated loops of large bowel.

the admission. Intraoperative findings revealed transverse colon volvulus and sigmoid volvulus associated with megacolon. The volvulus were untwisted. The entire colon appeared massively dilated and total colectomy was performed (Fig. 4). The resection with one time anastomosis revealed hazardous and terminal ileostomy was preferred. The postoperative period was uneventful and the patient was discharged 8 days later.

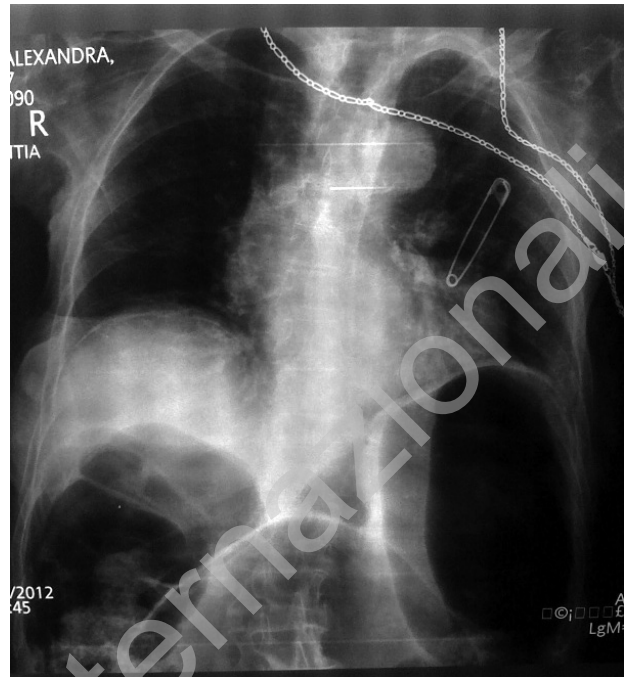

Fig. 2 - Chest radiography showed elevation of both hemidiaphragms.

Discussion

It is reported that approximately 3%-5% of all cases of intestinal obstruction are caused by colonic volvulus (7). It seems that, of all tracts of colon, only 2% of volvulus involve the transverse colon. The anatomy of the transverse colon prohibits volvulus in this area. In other words, the volvulus of the transverse colon is rare because the transverse mesocolon is short and the colo-

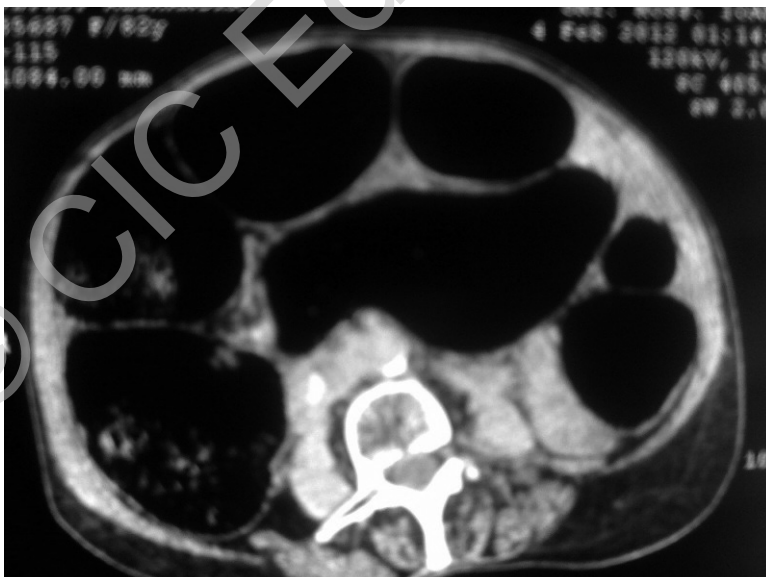


Fig. 3 - CT showed massively dilated large bowel.

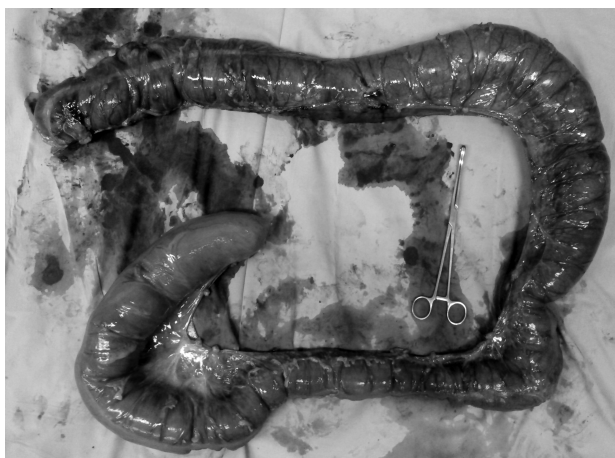

Fig. 4 - Total colectomy specimen (length: 230 cm; max diameter: 13 cm).

nic flexures act to fix the transverse colon in position. The chronic constipation is a common condition which predisposes to volvulus because of the elongation and the redundancy of the colon. This situation permits volvulus even in the presence of a normal mesentery (8). The presence of simultaneous volvulus in the transverse colon and in another colonic area is an extremely rare situation. It seems that dolichocolon is a clinical condition involving elongation and dilatation of the colon, most commonly seen in elderly patients, as in our case (9). Re-

section with or without primary anastomosis is the treatment of choice for these cases in order to prevent recurrence (10).

Conclusion

In conclusion, the diagnosis of single tract colonic volvulus or in association with another colonic segment can be difficult and requires a high suspicion on the part of the surgeon. These conditions must be considered in the differential diagnosis when dealing with recurrent intermittent abdominal pain or acute intestinal obstruction because any misinterpretation may result in unfavorable outcomes.

Competing interests

The authors declare that they have no competing interests.

Author's contributions

LG and IE performed the surgery researched sources for the reference and drafted the manuscript. LE and AZ took the photographs and draft the manuscript. FM helped draft the final version of the manuscript. All authors were actively involved in the preoperative and postoperative care of the patient, read and approved also the final manuscript form.

References

1. Ballantyne GH, Brandner MD, Beart Jr RW, et al. Volvulus of the colon: incidence and mortality. *Ann Surg* 1985;202:83-92.
2. Spiegel A, Chugh T, Lebovics E. A Review of Colonic Volvulus. A case report. *Practical Gastroenterology*, Sept 2009;42-46.
3. Udezue NO. Sigmoid Volvulus in Kaduna, Nigeria. *Dis Colon Rectum* 1990;33:647-9.
4. Faranisi CT. Volvulus of transverse colon (occurring after sigmoid volvulus). *Cent Afr J Med* 1984;30(2):272-3.
5. Jones IT, Fazio VW. Colonic Volvulus: etiology and management. *Dig* 1989;7(4):203-209.
6. Wisler JR, Stawicki SPA. Interesting Clinical Image: Colonic "double twist". *OPUS 12 Scientist* 2009; 58-59 Vol 3, No 3.
7. Gumbs MA, Koshan F, Shumofsky E, et al. Volvulus of the transverse colon. Report of cases and review of the literature. *Dis Colon Rectum* 1983;26:825-828.
8. Anderson JR, Lee P, Taylor TV, et al. Volvulus of the transverse colon. *Br J Surg* 1981;68:179-181.
9. Houshian S, Sorensen S, Jensen KEJ. Volvulus of the transverse colon in children. *J Pediatr Surg* 1998;33:1399-1401.
10. Santoshkumar ND, Audumber NM, Akshay PD et al. Transverse Colon Volvulus with Chilaiditis Syndrome. Case report. *Indian J Surg* (July-August 2010) 72(4):347-349.