

A wrong diagnosis of recurrent perineal hernia

M. CARICATO, F. AUSANIA, R. COPPOLA

SUMMARY: A wrong diagnosis of recurrent perineal hernia.

M. CARICATO, F. AUSANIA, R. COPPOLA

We describe a case of a patient who had several operations for recurrent perineal hernia. She eventually had an abdominal surgical debulking for aggressive angiomyxoma.

RIASSUNTO: Ernia perineale recidiva: una diagnosi errata.

M. CARICATO, F. AUSANIA, R. COPPOLA

Descriviamo il caso clinico di una paziente che si è presentata alla nostra attenzione dopo essere stata sottoposta a diversi interventi di ernioplastica perineale. La diagnosi finale è stata di angiomioma aggressivo, trattato con successo mediante debulking chirurgico.

KEY WORDS: Aggressive angiomyxoma - Perineal hernia - Pelvic tumor.
Angiomixoma aggressivo - Ernia perineale - Tumore pelvico.

Introduction

A 38-year-old woman was admitted to our hospital due to recurrent perineal swelling of the left labium (Fig. 1). This symptom had occurred several times for the last ten years and, during her previous admissions, she was diagnosed as having recurrent perineal hernia all the time and therefore she underwent seven perineal hernia repairs.

Case report

During the admission at our Unit, the patient underwent a pelvic MRI that showed the presence of a large pelvic tumour, compressing and displacing rectum, sigmoid colon, uterus, bladder and ureters, and invading labia and inguinal regions (Fig. 2). A percutaneous biopsy of the perineal tissue was performed, and the histology was consistent with the diagnosis of aggressive angiomyxoma (AAM).

She underwent a surgical debulking via an abdomino-perineal

approach. Total hysterectomy and inguinal canal exploration were also performed (Fig. 3). Histology confirmed the diagnosis of AAM but surgical margins were microscopically positive.

The postoperative course was complicated by left ureteral leak-

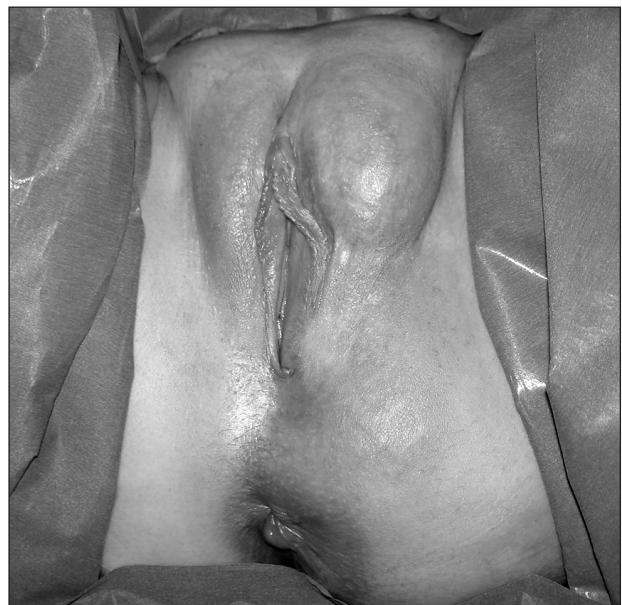

Fig. 1 - Clinical presentation at admission. Perineal swelling of the labium.

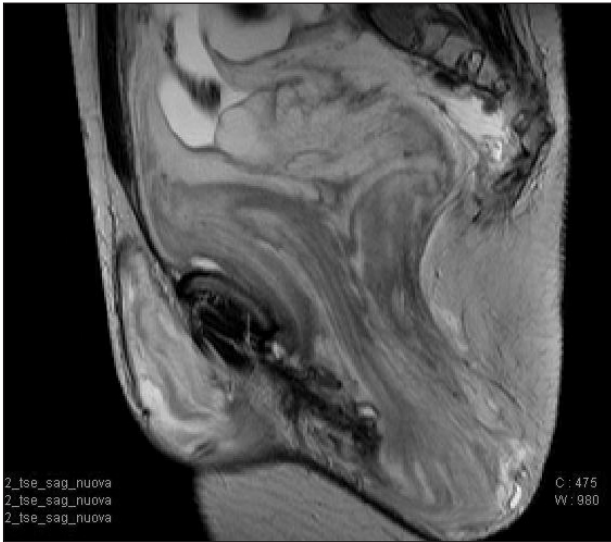


Fig. 2 - Pelvic tumor hyperintense in T2-weighted images with a swirled internal structure and presenting non-homogeneous enhancement.

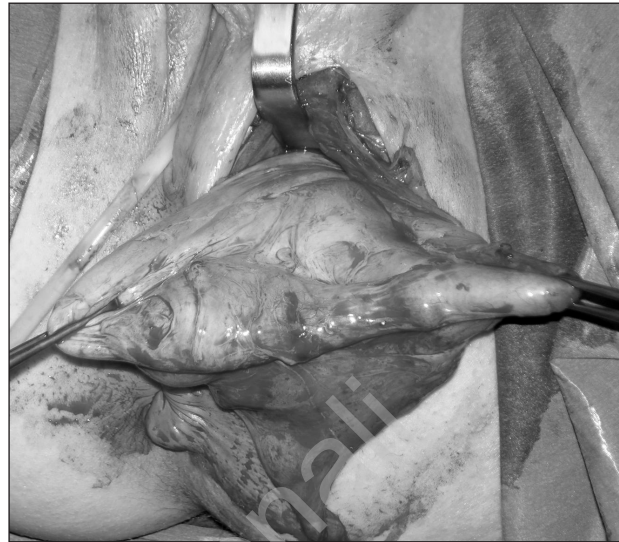


Fig. 3 - Perineal approach.

age requiring ureteral stent, and neurologic bladder treated with rehabilitation.

Discussion

Aggressive angiomyxoma is a rare soft-tissue neoplasm that predominantly occurs in premenopausal women, often reaching huge sizes. Presentation as inguinal or pelvic floor hernia has been reported, and failure to make a correct preoperative diagnosis is common (1).

At MRI, AAM shows high signal intensity on T2-

weighted images with swirled internal structure. Local relapse is frequent (33-83%) and two cases of distant metastasis have been reported (2).

Histology demonstrates immunohistochemical positivity for desmin, vimentin, SMA, estrogen and progesterone receptors.

Therapy is based on surgical resection, and the role of complementary treatment is not well defined. Furthermore, as radical excision does not significantly reduce the risk of local relapse, many authors suggest non-mutilating surgery to reduce postoperative complications (3).

References

1. Amezcua CA, Begley SJ, Mata N, Felix JC, Ballard CA. Aggressive angiomyxoma of the female genital tract: a clinicopathologic and immunohistochemical study of 12 cases. *Int J Gynecol Cancer* 2005, 15, 140-145.
2. Outwarter EK, Marchetto BE, Wagner BJ, Siegelman ES. Aggressive angiomyxoma: findings on CT and MR imaging. *AJR Am J Roentgenol* 1999; 172(2):435-8.
3. Han-Geurts IJ, van Geel AN, van Doorn L, M den Bakker, Eggermont AM, Verhoef C. Aggressive angiomyxoma: multimodality treatments can avoid mutilating surgery. *Eur J Surg Oncol*. 2006 Dec;32(10):1217-21.