

Surgical treatment of anaplastic thyroid carcinoma. Our experience

N. PALESTINI, E. BRIGNARDELLO¹, M. FREDDI, A. PIOVESAN¹,
N.S. PIPITONE FEDERICO, G. SISTO, A. ROBECCHI

SUMMARY: Surgical treatment of anaplastic thyroid carcinoma. Our experience.

N. PALESTINI, E. BRIGNARDELLO, M. FREDDI, A. PIOVESAN,
N.S. PIPITONE FEDERICO, G. SISTO, A. ROBECCHI

Background. In anaplastic thyroid carcinoma (ATC) surgical resection associated to radiotherapy and chemotherapy can ameliorate local disease control with occasional long-term survivals.

Patients and methods. Resection of the tumor was accomplished in 20 ATC patients, with no macroscopic (13 cases) or minimal residual neck disease infiltrating vital structures (7 cases). Ten of these patients (50%) had distant metastases. Sixteen cases were also treated with radiotherapy and chemotherapy, while in one patient only chemotherapy was possible; 2 patients refused further therapy; the last one is starting adjuvant treatment. Morbidity and survival were analysed, and compared with other 15 ATCs submitted to partial tumor debulking or not operated at all (control group).

Results. Function of at least one laryngeal recurrent nerve was preserved in all 20 patients; none experienced permanent hypoparathyroidism. At last follow-up examination 17 patients had died and 3 were alive 1, 6 and 80 months after the operation, the latter being free of disease. Survival of dead patients ranged from 3 to 28 months (mean: 8 months). In the control group all patients died, survival ranging from 1 to 13 months (mean: 4 months). Actuarial analysis of survival showed a significant difference between the two groups ($p = 0.0112$); multivariate analysis of several prognostic factors confirmed that complete or near complete tumour resection was the most relevant.

Conclusions. Surgical resection is an important component of the multimodal treatment of ATC and should be attempted whenever possible.

RIASSUNTO: Nostra esperienza nel trattamento chirurgico del carcinoma anaplastico della tiroide.

N. PALESTINI, E. BRIGNARDELLO, M. FREDDI, A. PIOVESAN,
N.S. PIPITONE FEDERICO, G. SISTO, A. ROBECCHI

Introduzione. Nel carcinoma anaplastico della tiroide (ATC) l'exeresi chirurgica associata a chemio- e radioterapia può migliorare il controllo locale della malattia con occasionali lunghe sopravvivenze.

Pazienti e metodi. In 20 pazienti con ATC è stato possibile effettuare la resezione del tumore, senza residui macroscopici (13 casi) o con minimi residui su strutture vitali infiltrate (7 casi); 10 di questi pazienti (50%) avevano già metastasi a distanza. Sedici casi sono stati trattati anche con chemio- e radioterapia; in uno è stata possibile solo la chemioterapia; 2 pazienti hanno rifiutato ulteriori terapie; uno sta per iniziare la terapia adiuvante. Sono state analizzate morbilità e sopravvivenza, anche confrontando questi casi con altri 15 ATC sottoposti a exeresi incompleta del tumore cervicale o non operati affatto (gruppo di controllo).

Risultati. La funzione di almeno un nervo laringeo ricorrente è stata salvaguardata in tutti i casi, e nessuno ha avuto un ipoparatiroidismo permanente. Al termine dello studio 17 pazienti erano morti e 3 erano vivi a 1, 6 e 80 mesi dall'intervento; quest'ultimo caso è libero da malattia. La sopravvivenza dei pazienti deceduti varia fra 3 e 28 mesi (media: 8 mesi). Nel gruppo di controllo tutti i pazienti erano deceduti, con sopravvivenze comprese fra 1 e 13 mesi (media: 4 mesi). L'analisi attuariale della sopravvivenza ha dimostrato una significativa differenza fra i due gruppi ($p = 0.0112$); un'analisi multifattoriale di diversi fattori prognostici ha confermato che il più rilevante era l'exeresi completa o quasi completa del tumore.

Conclusioni. La resezione chirurgica è una componente importante del trattamento multimodale dell'ATC e dovrebbe essere tentata ogniqualvolta possibile.

KEY WORDS: Anaplastic thyroid carcinoma - Total thyroidectomy - Prognosis.
Tiroide - Carcinoma anaplastico - Tiroidectomia totale - Prognosi.

Background

Anaplastic thyroid carcinoma (ATC) is a rare, highly aggressive malignancy with poor prognosis. The role of surgery remains controversial. Nevertheless there is evidence that a multimodality approach including surgical resection, radiation, and chemotherapy can ameliorate

A.O.U. San Giovanni Battista della Città di Torino, Italy
Services of General Surgery I and
¹ Endocrinological Oncology

Relazione presentata in occasione del "XXIX Congresso Nazionale della Società Italiana di Endocrinochirurgia"
Palermo, 24-26 giugno 2010

© Copyright 2010, CIC Edizioni Internazionali, Roma

local disease control with occasional long-term survivals (1-4).

Here, we retrospectively report the results of complete or near complete surgical resection in a series of ATC patients treated in a single center of Northern Italy.

Patients and methods

Between 01/01/2003 and 03/31/2010 complete resection of the tumour was attempted in 22 ATC patients. The study is focused on 20 patients in which the operation was accomplished with no macroscopic, or minimal residual neck disease infiltrating vital structures. Ten of these patients had distant metastases (TMN stage IV C: 50%). This was not considered a contraindication, because primary aim was local disease control. Demographic and clinical data are set in Table 1.

TABLE 1 - DEMOGRAPHIC AND CLINICAL DATA.

Sex	F = 13 (65%) M = 7
Age	57-88 (mean: 74)
TNM Stage	IV A/B = 10 (50%) IV C = 10
LRN paralysis	7 (35%)
History of multinodular goiter	14 (70%)
- With hyperthyroidism	- 4 (20%)
- Submitted to partial resection	- 1 (5%)
- Submitted to external beam radiotherapy	- 1 (5%)
Locoregional recurrence of anaplastic cancer	1 (5%)*

* Thyroidectomy for multinodular goiter 3 months before with unexpected finding of anaplastic cancer

Sixteen patients received radiation therapy (36-40 Gy) combined with chemotherapy (doxorubicin 20 mg/m² + cis-platinum 20 mg/m², administered weekly up to a maximum doxorubicin dose of 550 mg). One patient not suitable for radiotherapy after surgery was treated by chemotherapy alone (paclitaxel 100 mg/m² weekly, for 6 consecutive weeks out of 8 weeks). Two patients refused further therapies. One patient has just been operated and is starting adjuvant treatment.

Operative details and morbidity were analysed. Furthermore, survival of the 19 patients with a sufficient follow-up was compared with 15 ATCs referred to our Institutions in the same period, and submitted to partial tumour debulking or not operated at all (control group). The follow-up was updated as of February 28, 2010. Crude Kaplan-Meier survival probabilities were estimated, both overall and stratified by several variables (age at diagnosis, tumour size, TNM stage, chemotherapy, radiotherapy). Differences between curves were tested using the two-tailed log-rank test. Multivariate hazard ratios (HR) and corresponding 95% confidence intervals (95% CI) were estimated via the Cox proportional hazard model. SAS System v. 8.0 was used.

Results

Operative details

Relevant operative data are summarized in Table 2. Two cases required a partial sternotomy for tumour mobilisation and vascular control in the upper mediastinum. The tumour mass was excised with surrounding infiltrated tissues and metastatic lymph nodes (Fig. 1). In 4 cases an internal jugular vein was resected and one patient also required resection of the vagus nerve, but in most cases the elements of the vascular bundle were dissected from the tumour and preserved (Fig. 2). Minimal macroscopic

TABLE 2 - OPERATIVE DETAILS.

Access, pts	
- Cervicotomy	- 18 (90%)
- Cervicotomy plus partial sternotomy	- 2
Tumour maximum diameter (cm)	2,5-12,0 (mean: 6,5)
Lymph node metastases	12 (60%)
Deliberate resection of nervous/vascular structures, pts	6 (30%)
- RLN	- 3 (15%)
- Vagus nerve	- 1 (5%)
- Internal jugular vein	- 4 (20%)
Macroscopic residual disease (R2 resections), pts	7 (35%)
- Infiltrating trachea	- 5 (25%)
- Infiltrating pharynx and/or oesophagus	- 2 (10%)
- Infiltrating subclavian vein	- 1 (5%)
Tracheostomy, pts	1 (5%)
Exeresis of an incidentally discovered parathyroid adenoma, pts	1 (5%)

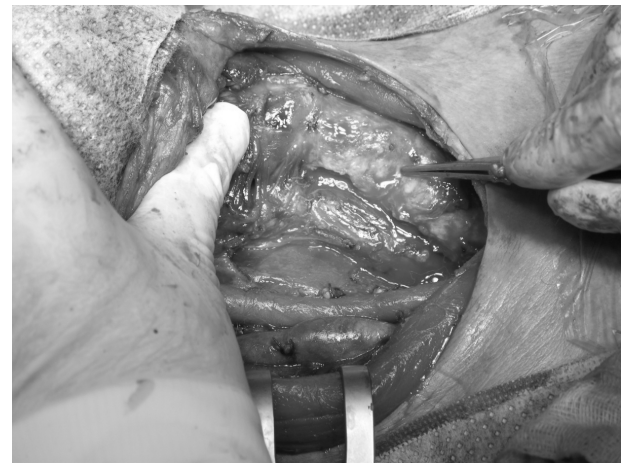

Fig. 1 - Operative field after complete exeresis: the tumour was "shaved off" from the trachea and removed with an oval of oesophageal wall; right LRN had already been paralyzed and was resected.

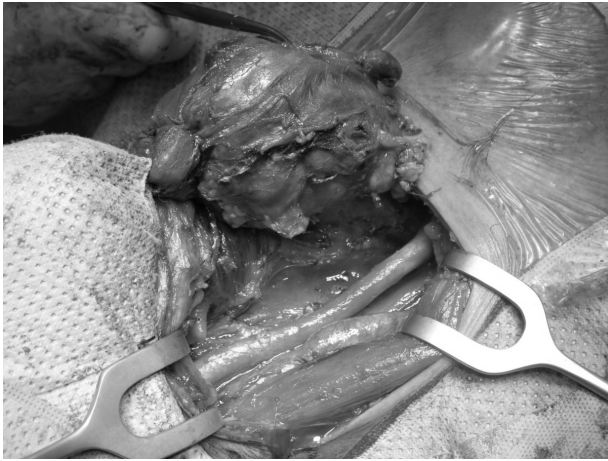

Fig. 2 - The elements of right vascular bundle have been dissected from the tumour.

pic residual disease was left behind in 7 cases (R2 resections: 35%) because an aggressive resection of infiltrated vital structures was not considered reasonable (5). The operation ended with a tracheostomy in one case.

Morbidity

Five (25%) monolateral paralyses of the recurrent laryngeal nerve (RLN) resulted from the deliberate *en bloc* resection of one RLN (3 cases) or vagus nerve (one case), or from the dissection of a RLN encased by the tumour (one case). One patient experienced some respiratory distress due to laryngeal edema and bilateral vocal folds hypomobility, that completely recovered after two-days ob-

TABLE 3 - KAPLAN-MEIER SURVIVAL ESTIMATES AND COX MODEL.

Variables	% 6 months survival (SE)	HR (95% CI)
Surgical exeresis		
- Complete / near complete	68.4 (0.11)	0.35 (0.13-0.91)
- Partial / not done	20.0 (0.10)	1
Age at diagnosis		
- ≤ 70	46.2 (0.14)	1
- > 70	47.6 (0.11)	1.24 (0.53-2.90)
Tumour diameter (cm)		
- ≤ 6.5	47.1 (0.12)	1
- > 6.5	47.1 (0.12)	0.98 (0.38-2.52)
TNM stage		
- IV A/B	66.7 (0.12)	1
- IV C	31.6 (0.11)	1.56 (0.64-3.78)
Chemotherapy		
- Yes	48.1 (0.10)	0.71 (0.16-3.14)
- Not	42.9 (0.19)	1
Radiotherapy		
- Yes	52.4 (0.11)	1.37 (0.33-5.73)
- Not	38.5 (0.13)	1

SE: standard error; HR: hazard ratios; CI: confidence intervals.

servation in Intensive Care Unit. No cases of permanent hypoparathyroidism, or intra-/postoperative haemorrhage occurred. One patient developed a seroma that resolved after percutaneous aspiration.

Survival

At last follow-up examination 17 patients had died, and 3 were alive 1, 6 and 80 months after the operation, the latter being free of disease. Survival of dead patients ranged from 3 to 28 months (mean: 8 months); two patients lived >1 yr and one lived >2 yrs. In the control group all the patients had died, survival ranging from 1 to 13 months (mean: 4 months).

Crude survival was better in our series than in the control group (p = 0.0112) and was significantly affected by any of the other variables. Cox model confirmed that complete or near complete resection of the tumour was the most relevant prognostic factor (HR = 0.35; 95% CI: 0.13-0.91) (Fig. 3 and Table 3).

Conclusions

Despite the overall grim outcome of ATC, these results justify an attempt at complete or near complete resection, followed by adjuvant chemoradiotherapy, possible in all ATC patients.

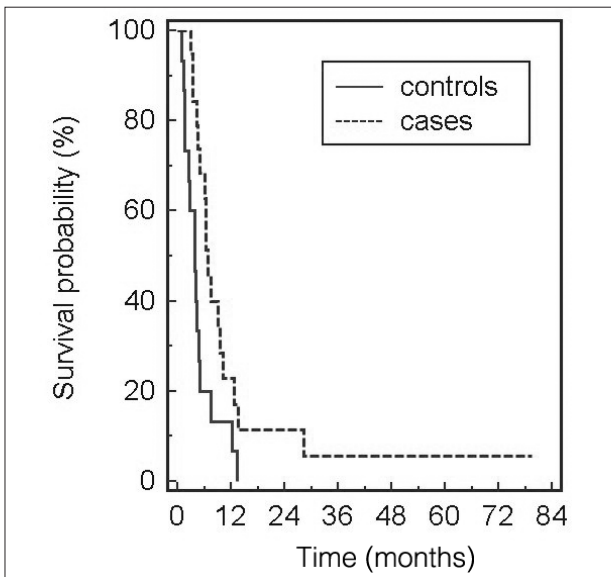


Fig. 3 - Survival in our series and in the control group according to crude Kaplan-Meier estimates.

References

1. Are C, Shaha AR. Anaplastic thyroid carcinoma: biology, pathogenesis, prognostic factors, and treatment approaches. *Ann Surg Oncol* 2006; 13:453-64.
 2. Brignardello E, Gallo M, Baldi I, Palestini N, Piovesan A, Grossi E, Ciccone G, Bocuzzi G. Anaplastic thyroid carcinoma: clinical outcome of 30 consecutive patients referred to a single institution in the past 5 years. *Eur J Endocrinol* 2007; 156:425-30.
 3. Miccoli P, Materazzi G, Antonelli A, Panicucci E, Frustaci G, Berti P. New trends in the treatment of undifferentiated carcinomas of the thyroid. *Langenbecks Arch Surg* 2007; 392:397-404.
 4. Neff RL, Farrar WB, Kloos RT. Anaplastic thyroid cancer. *Endocrinol Metab Clin N Am* 2008; 37:525-38.
 5. Lang BH-H, Lo C-Y. Surgical options in Undifferentiated thyroid carcinoma. *World J Surg* 2007; 31:969-77.
-