

## Endoscopic sphincterotomy of the major duodenal papilla in acute relapsing pancreatitis associated with pancreas divisum: a case report

E. SPAZIANI, P. TRENTINO<sup>3</sup>, M. PICCHIO<sup>2</sup>, A. DI FILIPPO, M. BRIGANTI<sup>1</sup>,  
G. PIETRICOLA<sup>4</sup>, W. ELISEI<sup>2</sup>, F. CECI, S. CODA<sup>3</sup>, G. PATTARO, F. PARISELLA<sup>4</sup>,  
F. DE ANGELIS, M. PECCHIA, F. STAGNITTI

**SUMMARY:** Endoscopic sphincterotomy of the major duodenal papilla in acute relapsing pancreatitis associated with pancreas divisum: a case report.

E. SPAZIANI, P. TRENTINO, M. PICCHIO, A. DI FILIPPO, M. BRIGANTI, G. PIETRICOLA, W. ELISEI, F. CECI, S. CODA, G. PATTARO, F. PARISELLA, F. DE ANGELIS, M. PECCHIA, F. STAGNITTI

*We report a case of acute relapsing pancreatitis associated with pancreas divisum, who underwent major papilla sphincterotomy after failed minor papilla cannulation. Long-term results were satisfactory. The possible explanations of the efficacy of major papilla endoscopic resection in this particular case are discussed.*

**RIASSUNTO:** Sfinterotomia endoscopica della papilla duodenale maggiore in pancreatite acuta ricorrente associata a pancreas divisum. Caso clinico.

E. SPAZIANI, P. TRENTINO, M. PICCHIO, A. DI FILIPPO, M. BRIGANTI, G. PIETRICOLA, W. ELISEI, F. CECI, S. CODA, G. PATTARO, F. PARISELLA, F. DE ANGELIS, M. PECCHIA, F. STAGNITTI

*Gli Autori riportano un caso di pancreatite acuta ricorrente associata a pancreas divisum. La paziente è stata sottoposta a sfinterotomia endoscopica della papilla duodenale maggiore, dopo fallimento dell'incannulazione della papilla minore. La paziente è asintomatica ai controlli clinici e di laboratorio a lungo termine. Vengono discussi i possibili meccanismi alla base del successo terapeutico.*

**KEY WORDS:** Endoscopic sphincterotomy - Pancreas divisum - Acute relapsing pancreatitis. Sfinterotomia endoscopica - Pancreas divisum - Pancreatite acuta ricorrente.

### Introduction

Pancreas divisum (PD) is the most frequent congenital anomaly of the pancreas with a 5-10% prevalence in autopsy studies (1, 2). It is characterized by separate drainage into the duodenum of the dorsal and ventral parts of the gland, owing to the failure of normal fusion between the dorsal and ventral ducts during the seventh week of gestation. The duct of Santorini is the

main duct, while the duct of Wirsung drains only the pancreatic head. In subjects with PD the dorsal pancreatic duct drains most of the pancreas through the minor duodenal papilla. As the minor duodenal papilla is substantially smaller than the major duodenal papilla, a larger volume of secretions could place a significant load on the minor duodenal papilla (3).

Considerable controversy exists regarding the correlation between this malformation and pancreatitis, as most cases with complete PD are asymptomatic. However, it has been suggested that, in some cases, complete PD may cause acute pancreatitis, chronic pancreatitis, or pancreatic-type pain, due to the presence of relative obstruction to the drainage of pancreatic juices at the minor duodenal papilla (3, 4).

In patients with pancreatitis and PD, endoscopic therapy was proposed with the aim to enlarge the minor sphincter. This technique can improve pain score in approximately 75% of patients with acute relapsing pancreatitis (ARP) (5). However, cannulation of the minor papilla is difficult and fails in about 10-20% of cases (3).

<sup>1</sup> "Sapienza" Università di Roma, Ospedale "A. Fiorini" Terracina, AUSL Latina, UOC Chirurgia Universitaria Polo Pontino (Direttore: Prof. F. Stagnitti)

<sup>2</sup> Ospedale "S. Giovanni di Dio" Fondi, AUSL Latina, UOC Radiologia (Direttore: Dott. E. Monti)

<sup>3</sup> Ospedale "P. Colombo" Velletri, AUSL RMH, UOC Chirurgia Generale (Direttore: Dott. G. Marino)

<sup>4</sup> "Sapienza" Università di Roma, Azienda "Policlinico Umberto I", Roma UOS Diagnostica e Terapia Parachirurgica Vie Biliari e Apparato Digerente

<sup>5</sup> Ospedale "A. Fiorini" Terracina, AUSL Latina, UOC Radiologia (Direttore: Dott. E. Monti)

Moreover, complications are not trivial and occur in up to 50% of patients (5).

We present a patient with ARP and PD, who underwent major papilla sphincterotomy after failed minor papilla cannulation with satisfactory long-term results.

## Case report

A 71-year-old female, with no history of alcohol use, was admitted in our Department after 3 days of epigastric pain irresponsive to therapy with FANS. Previous history showed three hospital admissions with acute pancreatitis in the last 2 years. Since 2 years the patient was given a low-fat diet and pancreatic enzyme supplements.

At physical examination the patient was in good general conditions with a moderate epigastric tenderness. The white cell count was 11,300/mm<sup>3</sup>, serum amylase 304 U/L (normal value 28-100 U/L), lipase 894 U/L (normal values 13-60 U/L), total bilirubin 1.7 mg/dL (normal values 0-1 mg/dL), direct bilirubin 1.0 mg/dL (normal values < 0.25 mg/dL), AST 544 U/L (normal values < 35 U/L) ALT 224 U/L (normal values < 55 U/L), GGT 210 U/L (normal values 5-36 U/L). The patient underwent both abdominal ultrasound and CT, showing an edematous pancreas. The patient improved with conservative therapy.

Owing to the history of relapsing acute pancreatitis, the patient was submitted to magnetic resonance cholangiopancreatography (MRCP), that showed the presence of an accessory pancreatic duct directly extended into the main pancreatic duct and crossing the common bile duct (Fig. 1). The diagnosis of PD was established. The patient underwent ERCP, performed by an experienced endoscopist. The attempt to cannulate the minor papilla with a tapered cannula and a guidewire failed. The cannulation of the major papilla was successful, showing a short Wirsung duct without other morphologic abnormalities and normal choledocus (Fig. 2). Major papilotomy was performed. The recovery was uneventful.

At 3 year follow-up the patient showed neither further episode of abdominal pain for symptomatology of acute pancreatitis.

## Discussion

PD was originally defined as a very rare congenital anomaly in which the parenchyma of the ventral and dorsal pancreas is separated as a double pancreas. At present PD describes the presence of two ductal systems and also includes incomplete PD, in which a communication between the ventral and dorsal pancreatic duct exists as a small-caliber channel, with predominantly drainage through the minor duodenal papilla (3).

In our case PD was associated with primitive ARP. The increased incidence of this congenital anomaly in patients with unexplained acute pancreatitis and without response to endoscopic or surgical therapy supports the theory that PD should be considered an etiologic factor (5). In patients with ARP, MRCP is important to identify anatomical abnormalities such as pancreas divisum, choledochocoele, anomalous pancreatobiliary junction, or annular pancreas (6). One impor-

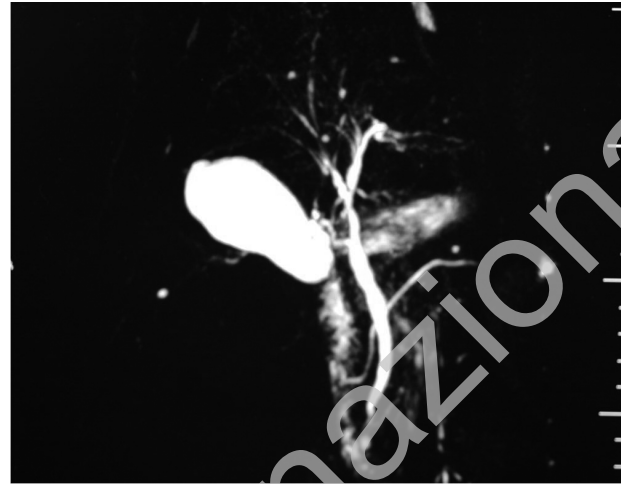


Fig. 1 - MRCP coronal T2 SE SPIR. The duct of Santorini is the main duct, while the duct of Wirsung drains only the pancreatic head.

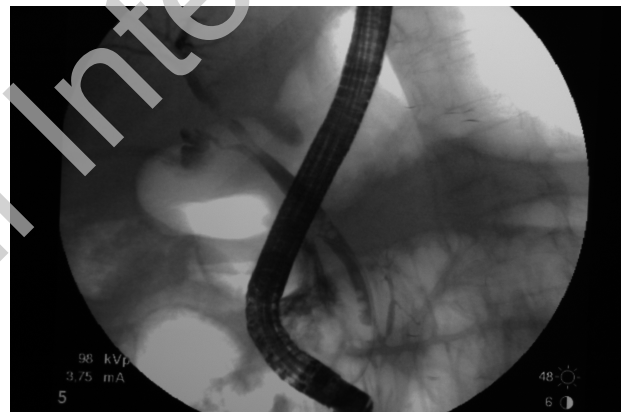


Fig. 2 - Cannulation of major papilla shows a normal biliary tree as well as the cephalic pancreatic duct.

tant limitation of MRCP is that it overestimates the presence of PD, as it cannot completely exclude a connection between dorsal and ventral ductal system (incomplete PD), due to limited spatial resolution (7).

Endoscopic interventions via the minor papilla are well-established standard procedures in patients with pancreas divisum. The minor papilla orifice may be opened endoscopically by dilation, stenting, or sphincterotomy. In a recent large series of patients with symptomatic PD, minor papilla cannulation was technically successful in 86% of subjects; mild-to-moderate complications occurred in 12% of cases and 76% of patients with ARP took advantage from the procedure (8).

We reported a unique case of ARP associated with PD successfully treated with major papilla sphincterotomy, after minor duodenal papilla cannulation failure. A possible explanation may be that our patient actually represents a case of incomplete PD with a tiny

communication between the ventral and dorsal pancreatic duct undetectable with MRCP and ERCP. In normal pancreas a patent Santorini duct was documented with dye-injection through the major papilla in 43% of cases (9).

The results of a recent study showed that the main pancreatic duct can be adequately decompressed through the minor papilla, with relief of symptoms in patients with a normal arrangement of the accessory and main pancreatic ducts (10). In our case main pancreatic duct sphincterotomy may have been effective through the reverse mechanism. Another possible explanation is that

endoscopic therapy of the major sphincter in patients with PD may be effective because pancreatitis often resides in both the parenchyma drained by the ventral and dorsal pancreatic duct (11). Biliary sludge, undetectable by common diagnostic work-up, may represent another etiology factor in determining ARP (12).

In conclusion, our case report claims for the endoscopic therapy of the main pancreatic duct in patients with ARP and PD when minor papilla cannulation fails. Further studies are required to assess its efficacy alone or in combination with minor papilla endoscopic therapy.

## References

1. Stimec B, Bulajic M, Korneti V, Milosavljevic T, Krstic R, Ugljesic M. Ductal morphometry of ventral pancreas in pancreas divisum. Comparison between clinical and anatomical results. *Ital J Gastroenterol* 1996;28:76-80.
2. MacCarthy RL, Stephens DH, Brown AL, Carlson HC. Retrograde pancreatography in autopsy specimens. *Am J Roentgenol Rad Nucl Med* 1975;123:359-66.
3. Kamisawa T. Clinical significance of the minor duodenal papilla and accessory pancreatic duct. *J Gastroenterol* 2004;39:605-15.
4. Lehman GA, Sherman S, Nisi R, Hawes RH. Pancreas divisum: results of minor papilla sphincterotomy. *Gastrointest Endosc* 1993;39:1-8.
5. Fogel LE, Toth TG, Lehman GA, DiMagno MJ, Di Magno EP. Does endoscopic therapy favorably affect the outcome of patients who have recurrent acute pancreatitis and pancreas divisum? *Pancreas* 2007;34:21-45.
6. Levy MJ, Geenen JE. Idiopathic acute recurrent pancreatitis. *Am J Gastroenterol* 2001;96:2540-55.
7. Ito K, Koike S, Matsunaga N. MR imaging of pancreatic disease. *Eur J Radiol* 2001;38:78-93.
8. Chacko LN, Chen YK, Shah RJ. Clinical outcomes and non-endoscopic interventions after minor papilla endotherapy in patients with symptomatic pancreas divisum. *Gastrointest Endosc* 2008;68:667-73.
9. Kamisawa T, Yoshiike M, Egawa N, Nakajima H. Patency of the accessory pancreatic duct evaluated by dye-injection endoscopic retrograde pancreatography: method and clinical implication. *Dig Endosc* 2004;16:272-6.
10. Song MH, Kim MH, Lee SK, Lee SS, Han J, Seo DW, Min YI, Lee DK. Endoscopic minor papilla interventions in patients without pancreas divisum. *Gastrointest Endosc* 2004;59:901-5.
11. Kamisawa T, Horiguchi S, Hayashi Y, et al. Discrepancy between pancreatographic and histopathological findings in the ventral pancreas of pancreas divisum. *JOP* 2004;5:480-3.
12. Levy MJ, Geenen JE. Idiopathic acute recurrent pancreatitis. *Am J Gastroenterol* 2001; 96:2540-55.