

## True mediastinal ectopic goitre. Case report

M. DENTE, V. VITALE, A. SCARINCI, M. CAVALLINI

SUMMARY: True mediastinal ectopic goitre. Case report.

M. DENTE, V. VITALE, A. SCARINCI, M. CAVALLINI

*Heterotopic thyroid tissue is described to usually lie at the tongue base, while the 10% at the hyoid bone. We report a case of incidental diagnosis of a true mediastinal goitre with preoperative chest X-ray in a 35-year old woman with a multinodular cervical goitre.*

RIASSUNTO: Vero gozzo mediastinico: caso clinico.

M. DENTE, V. VITALE, A. SCARINCI, M. CAVALLINI

*La presenza di tessuto tiroideo eterotopico viene di solito descritta alla base della lingua e nel 10% dei casi nell'osso ioide. Riportiamo un caso di diagnosi accidentale di vero gozzo mediastinico evidenziato come "massa" dalla radiografia preoperatoria del torace in una donna di 35 anni con gozzo cervicale multinodulare.*

KEY WORDS: Ectopic thyroid - Incidental diagnosis - Sternotomy.  
Tiroide ectopica - Diagnosi accidentale - Sternotomia.

### Introduction

Heterotopic thyroid tissue is described to usually lie at the tongue base, while the 10% at the hyoid bone (1). Different localization are also described in cervical regions and in relation with larynx, trachea, oesophagus, mediastinum, diaphragm and the heart.

We report a case of asymptomatic true mediastinal ectopic goitre in a patient with multinodular cervical goitre and previous excision of thyroid nodule.

### Case report

A 35-year-old woman is admitted in our department for an asymptomatic multinodular goiter. She underwent thyroid nodule excision four years ago. Hematologic and thyroid function tests were normal. During the preoperative evaluation a chest X-ray showed a shadow in anterior mediastinum on the right (Fig. 1). A chest CT-scan disclosed a non homogeneous 84x51 mm oval mass lying on the ascending aorta (Fig. 2).

Due to the unknown nature of the mediastinal mass, we deci-

ded to refer our patient to the Thoracic Surgery Unit. At sternotomy there was no continuity between the thyroid gland and the mediastinal vascularized from the branches of anonymous artery and thoracic vessels. The mass was excised.

### Results

The definitive histology revealed an ectopic goiter without findings of malignancy. The postoperative course was uneventful and the patient was discharged on postoperative day 5<sup>th</sup>.

Thirteen months later, the patient was readmitted to our unit to perform the total thyroidectomy for multinodular goiter.

### Discussion and conclusion

According to the criteria of ectopic thyroid tissue, the true intrathoracic goiter is a rare condition. Indeed this definition is often used for both cervical goiter developed into mediastinum and for thyroid tissue not linked to the thyroid. The first condition, known as secondary intrathoracic goiter, is the result of progressive downgrowing of a cervical goiter in to the chest behind the sternum (1-3). On the other hand the so-called primary intrathoracic goiter represents the true ectopic thyroid

"Sapienza" University of Rome, Italy  
II School of Medicine  
"St. Andrea" Hospital  
Department of General Surgery

© Copyright 2009, CIC Edizioni Internazionali, Roma

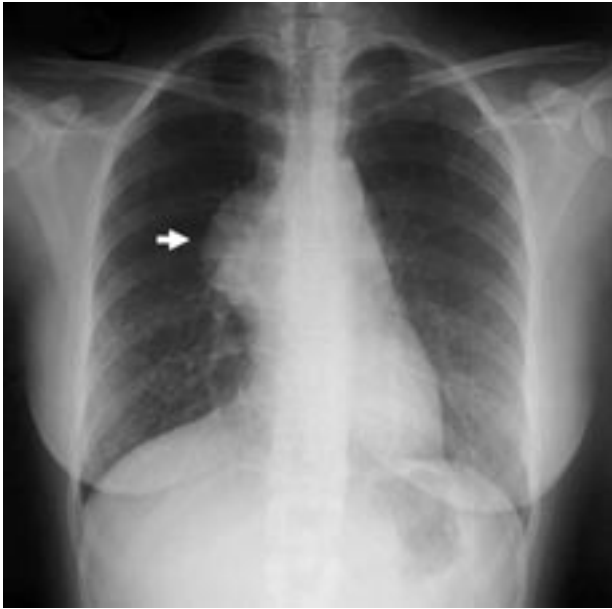


Fig. 1 - Chest X-ray showing a large mediastinal mass.

tissue in the chest as in our case; it differs from the secondary goiter because of the absence of connection with thyroid and for the blood supply from mediastinal vessels (3). Few patients are symptomatic showing cough, wheezing, dyspnea, hemoptysis, recurrent pneumonia, dysphagia, chest pain or superior vena cava syndrome due to the growing of mediastinal mass (1, 3). But most of the cases are asymptomatic (4). Thus the diagnosis is usually incidental, as in our case, during preoperative exams, i.e. chest X-ray, disclosing a tracheal displacement, or compression, calcifications and soft tissue mass.

## References

1. Fish J, Moore RM. Ectopic thyroid tissue and ectopic thyroid carcinoma: a review of the literature and report of a case. *Ann Surg* 1963;157:212–21.
2. Radkowski D, Arnold J, Healy GB, McGill T, Treves ST, Paltiel H et al. Thyroglossal duct remnants. *Arch Otolaryngol Head Neck Surg* 1991;117:1378–81.
3. Shields TW. Thyroid. In: Pearson FG, Deslauriers J, Ginsberg RJ, eds.; *Thoracic Surgery*. New York: Churchill Livingstone 1995; pp 1454–64.
4. Specker R, Curti G, Muller W, Stulz P. Intrathoracic goiter — a rare mediastinal tumor. *Swiss Surg* 2001;7(3):134–8.
5. Buckley JA, Stark P. Intrathoracic mediastinal thyroid goiter: imaging manifestations. *AJR Am J Roentgenol* 1999;173:471–5.
6. Mack E. Management of patients with substernal goiters. *Surg*

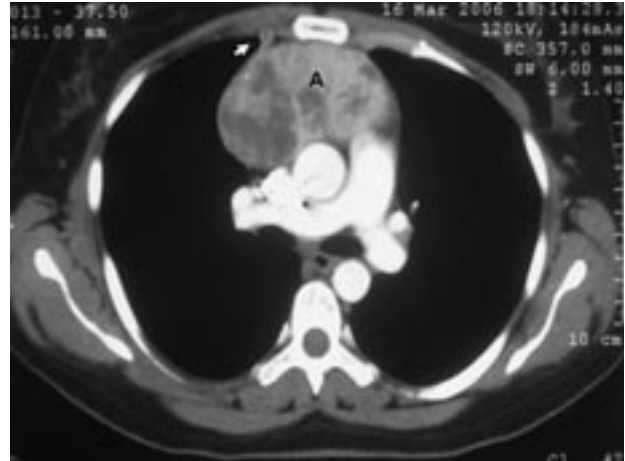


Fig. 2 - Chest CT scan showing a non homogeneous oval mass (A) in the anterior mediastinum and blood supply from thoracic vessels (arrow).

Further diagnostic tools are needed for the management plane. The scintigraphy can be useful for the differential diagnosis of thymoma and teratoma, but it is not ever diagnostic since the absence of uptake of the  $I^{131}$  by the mediastinal thyroid tissue (5, 6). Thus, according with the indications to surgical excision for almost all mediastinal masses, a chest CT-scan is required to show the connection with major thoracic vessels and other mediastinal organs (6-9). The resection is advocated like to solve compressive symptoms, and to rule out the diagnosis of malignancy (9, 10).

Although the thoracoscopic excision has been described, the surgical approach is usually a thoracotomy or sternotomy with a mortality rate ranging from 0 to 2% (9-11).

7. Neef H. The role of surgery in diagnosis and treatment of mediastinal malignancies. *Lung* 1990;168 Suppl:1153–61.
8. Van Schil P, Vanmaele R, Ehlinger P, Schoofs E, Goovaerts G. Primary intrathoracic goitre. *Acta Chir Belg* 1989; 89:206–8.
9. Nettekville JL, Coleman SC, Smith JC, Smith MM, Day TA, Burkey BB. Management of substernal goiter. *Laryngoscope* 1998;108(11 Pt 1):1611–17.
10. Houck WV, Kaplan AJ, Reed CE, Cole DJ. Intrathoracic aberrant thyroid: identification critical for appropriate operative approach. *Am Surg* 1998;64:360–62.
11. Grondin SC, Buenaventura P, Luketich JD. Thoracoscopic resection of an ectopic intrathoracic goiter. *Ann Thorac Surg* 2001;71:1697–8.