

Perforation of Meckel's diverticulum by a chicken bone mimicking acute appendicitis. Case report

A.L. CAMPOS CANELAS¹, A.N. ABUD NETO¹, A.L. SANTOS RODRIGUES¹,
L. CROCIATI MEGUINS², D. FELGUEIRAS ROLO², M. FERREIRA LOBATO³

SUMMARY: Perforation of meckel's diverticulum by a chicken bone mimicking acute appendicitis. Case report.

A.L. CAMPOS CANELAS, A.N. ABUD NETO, A.L. SANTOS RODRIGUES,
L. CROCIATI MEGUINS, D. FELGUEIRAS ROLO, M. FERREIRA LOBATO

Meckel's diverticulum (MD) is a congenital disorder that results from an incomplete obliteration of the vitelline duct. MD may give rise to bleeding, intestinal obstruction and inflammation; however its perforation by a foreign body is an extremely rare life-threatening complication.

We report on a 52 years-old Brazilian Amazon man presenting symptoms and signs of acute abdomen with an initial suspicion of acute appendicitis. However, the right diagnosis was made only during exploratory laparotomy when the appendix was found to be normal, whereas MD was found to be inflamed and perforated by a chicken bone. The patient was treated successfully with resection of a segment of the ileum, including the perforated diverticulum, and had an uncomplicated postoperative course.

RIASSUNTO: Perforazione del diverticolo di Meckel causata da un osso di pollo simulante un'appendicite acuta. Descrizione di un caso.

A.L. CAMPOS CANELAS, A.N. ABUD NETO, A.L. SANTOS RODRIGUES,
L. CROCIATI MEGUINS, D. FELGUEIRAS ROLO, M. FERREIRA LOBATO

Il diverticolo di Meckel (DM) è una anomalia congenita dovuta a una chiusura incompleta del dotto vitellino. Il DM può manifestarsi con emorragia, ostruzione intestinale e infiammazione; la sua perforazione da osso di pollo è una complicazione molto rara che pone a rischio la vita.

Descriviamo qui il caso di un paziente di sesso maschile (52 anni d'età), di origine amazzonica, il quale ha manifestato sintomi e segni di addome acuto con sospetto iniziale di appendicite acuta. Tuttavia, la diagnosi corretta è stata posta solo durante l'atto operatorio, quando l'appendice ciecale è apparsa normale mentre si è constatato che il DM era infiammato e perforato da un osso di gallina. Il paziente è stato curato con la rimozione del segmento ileale, con il DM perforato, con un'evoluzione post-operatoria regolare.

KEY WORDS: Meckel's diverticulum - Chicken bone - Surgery.
Diverticolo di Meckel - Osso di pollo - Chirurgia.

Introduction

Meckel's diverticulum (MD) is the most common congenital anomaly of the gastrointestinal tract and corresponds to a remnant of the vitelline or omphalomesenteric duct (1-3). It normally lies within 30 cm from the ileocecal valve and is found in 1-2% of the population, however only 16% of all MD are symptomatic and bleeding and obstruction are the most common clinical presentation in adults and children, respectively (4,

5). Foreign body perforation of MD caused by chicken bone is an extremely rare event, with only three cases reported in the literature (6-8).

The aim of this report is to describe the case of a Brazilian Amazon man who was thought to have acute appendicitis pre-operatively; however at operation a MD perforated by a chicken bone was found.

Case report

A 52-years-old Brazilian Amazon man was admitted presenting a seven days history of constant abdominal pain localized on the right iliac fossa (RIF). The patient referred also intermittent fever, nausea, vomits and absence of passage of stool and gas. His past medical history was unremarkable, but one week before the beginning of symptoms the patient referred having eaten a small chicken bone. On physical examination, he was apyrexia. He was tender on his RIF with signs of guarding. There was rebound tenderness, ab-

¹ Hospital de Pronto Socorro Municipal Dr. Humberto Maradei Pereira Belém, Pará, Brazil

² Health Science Institute. Faculty of Medicine. Federal University of Pará Belém, Pará, Brazil

³ Health and Biological Science Center. School of Medicine. State University of Pará. Belém, Pará, Brazil

© Copyright 2009, CIC Edizioni Internazionali, Roma

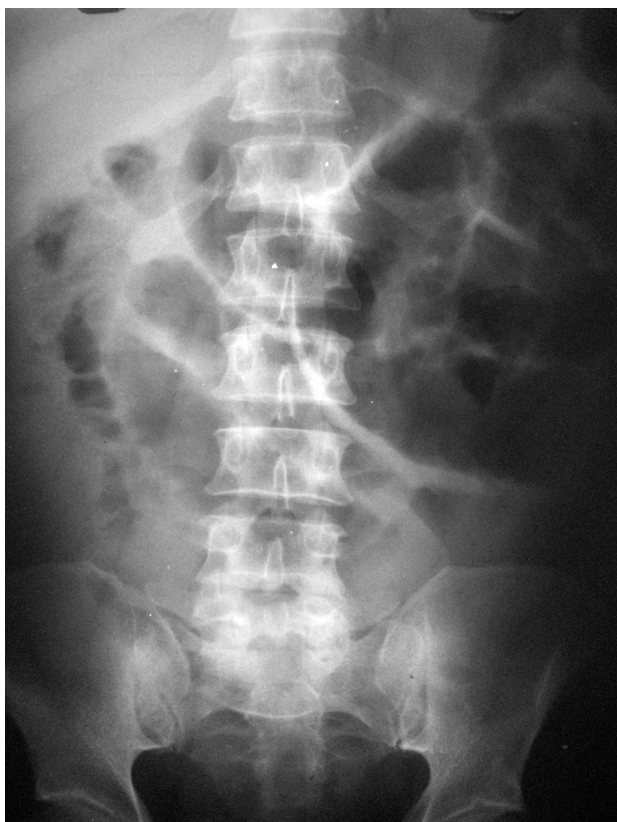


Fig. 1 - Abdominal radiography.

dominal dilation and a palpable mass at the right lower abdominal quadrant. Laboratorial blood tests were normal. Abdominal radiography showed important intestinal dilation (Fig. 1). As no other structural abnormality was identified, a provisional clinical diagnosis of acute appendicitis was made and the abdominal painful syndrome was attributed to it. Based on this diagnosis, the patient underwent an exploratory laparotomy.

At operation, through a median incision, a small amount of free fluid and a right iliac fossa mass were revealed. The appendix was normal as was the terminal ileum. However, there was a diverticulum projecting from the anti-mesenteric ileal board 25 cm from the ileocecal valve, perforated by a chicken bone, where adhesions of the omentum were identified. As some lesions of the ileum close to the inflammatory mass were created during the isolation of the MD from the adhesions, a 10 cm enterectomy, including the perforated MD (Fig. 2), and an end-to-end enteroenteral anastomosis 15 cm from the ileocecal valve were performed. The patient had an uneventful recovery and was discharged home on the sixth post-operative day. Histopathology revealed a MD with evidence of acute inflammatory process, vascular congestion and perforation. The gastric mucosa was not present within the diverticulum.

Discussion

Meckel's diverticulum (MD) is the most common congenital abnormality of the small intestine and corresponds to a remnant of the vitelline duct which nor-

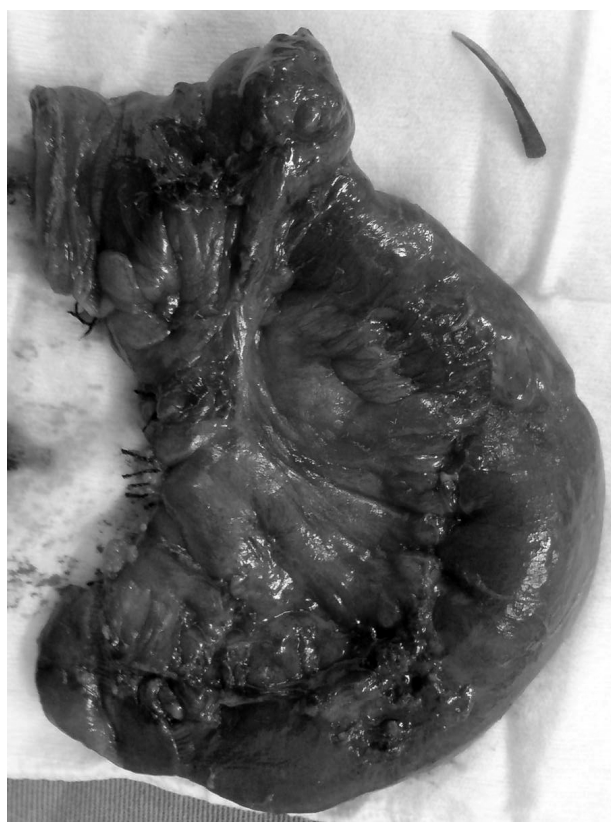

Fig. 2 - Gross specimen.

mally disappears at the end of the seventh week of gestation (6, 9). Wilhelm Fabricius Hildanus, a German surgeon, first described the diverticulum in 1598 (1, 4,5). However, Johann Friedrich Meckel, a German comparative anatomist, in a cadaver's study of 22 children was the first to publish a detailed description of the diverticulum's anatomy and embryology (1, 4-6).

The incidence in the general population is estimated to range between 0.3-3%, but only 16% of all MD are symptomatic (5,6). MD may give rise to bleeding, intestinal obstruction and inflammation, intussusception and neoplasms (5,9); however its perforation by a foreign body is an extremely rare life-threatening complication. According to Roessel (1962) (11), fish bone and wood splinter are the most common types of foreign bodies responsible of MD's perforation. Perforation of MD by a chicken bone is an extremely rare and dramatic event with only three cases reported in the literature (6-8).

In the majority of perforations, history of an ingested foreign body was lacking and operation usually was done on the basis of a surgical acute abdomen. Acute appendicitis is by far the most common preoperative diagnosis in patients without history of ingested foreign body (11). However, although there are no specific phy-

sical symptoms or signs that can differentiate between perforation of MD and acute appendicitis, diagnostic laparoscopy in acute abdominal pain may be an useful tool in the diagnosis and management foreign body perforation of MD (12). In our case, an initial suspicion of acute appendicitis was made, but we only confirmed the diagnosis during exploratory laparotomy when the appendix was found to be normal, whereas the MD was found to be inflamed and perforated by a

chicken bone. After surgery, our patient confirmed unintentional swallowing of a chicken bone two days before the beginning of symptoms.

In conclusion, this case reinforces that perforation of MD by a chicken bone is a rare complication and an uncommon cause of acute abdomen in adults. A segmental resection of the ileum, including the perforated MD, may be a good surgical approach when the diverticulum is involved by many adhesions.

References

1. John J, Pal K, Singh VP. Perforated Meckel's diverticulum causing giant pseudocyst and secondary appendicitis. *Indian Pediatr.* 2006;43:988-90.
2. Markogiannakis H, Theodorou D, Toutouzas KG, Drimousis P, Panoussopoulos SG, Katsaragakis S. Persistent omphalomesenteric duct causing small bowel obstruction in an adult. *World J Gastroenterol.* 2007;13:2258-60.
3. Rangarajan M, Palanivelu C, Senthilkumar R, Madankumar MV. Laparoscopic surgery for perforation of Meckel's diverticulum. *Singapore Med J.* 2007;:102-5.
4. Dumper J, Mackenzie S, Mitchell P, Sutherland F, Quan ML, Mew D. Complications of Meckel's diverticula in adults. *Can J Surg.* 2006;49(5):353-7.
5. Park JJ, Wolff BG, Tollefson MK, Walsh EE, Larson DR. Meckel diverticulum: the Mayo Clinic experience with 1476 patients (1950-2002). *Ann Surg.* 2005;241:529-33.
6. Yagci G, Cetiner S, Tufan T. Perforation of Meckel's diverticulum by a chicken bone, a rare complication: report of a case. *Surg Today.* 2004;34:606-8.
7. Borovoi SV. Perforation of Meckel's diverticulum by a chicken bone. (Russian) *Klin Khir.* 1990;(2):58 (Abstract).
8. Koussidis A, Dounavis A. Acute appendicitis as a diagnostic error. Perforation of Meckel's diverticulum by a chicken bone. (German) *Zentralbl Chir.* 1983;108:1525-6 (Abstract).
9. Karadeniz Cakmak G, Emre AU, Tascilar O, Bektaş S, Uçan BH, Irkorucu O, Karakaya K, et al. Lipoma within inverted Meckel's diverticulum as a cause of recurrent partial intestinal obstruction and hemorrhage: a case report and review of literature. *World J Gastroenterol.* 2007;13:1141-3.
10. Roessel CW. Perforation of Meckel's diverticulum by foreign body: case report and review of the literature. *Ann Surg.* 1962;156:972-5.
11. Wong JH, Suhaili DN, Kok KY. Fish bone perforation of Meckel's diverticulum: a rare event? *Asian J Surg.* 2005; 28:295-6.