

Endovascular repair in atypical traumatic rupture of thoracic aorta

F. BENEDETTO, M. LA SPADA, F. STILO, G. DE CARIDI, A. COTRONEO, G. PASSARI, F. SPINELLI

SUMMARY: Endovascular repair in atypical traumatic rupture of thoracic aorta.

F. BENEDETTO, M. LA SPADA, F. STILO, G. DE CARIDI, A. COTRONEO, G. PASSARI, F. SPINELLI

Introduction. The traumatic rupture of thoracic aorta is a surgical emergency with high risk of morbidity and mortality.

Case report. We describe the case of an atypical rupture of retrocardiac thoracic aorta with dissection of brachiocephalic trunk and spleen trauma occurred after a road accident. TC scan and perioperative angiography showed an atypical rupture of thoracic aorta.

Conclusion. A combined treatment, endovascular for retrocardiac thoracic aorta and surgical for brachiocephalic artery, has been useful to diminish the hemodynamic and organ ischemic problems associated with open surgery.

RIASSUNTO: Riparazione endovascolare di rottura traumatica atipica dell'aorta toracica.

F. BENEDETTO, M. LA SPADA, F. STILO, G. DE CARIDI, A. COTRONEO, G. PASSARI, F. SPINELLI

Introduzione. La rottura traumatica dell'aorta toracica rappresenta un'emergenza chirurgica con un alto rischio di morbilità e mortalità.

Caso clinico. Si riporta il caso di una rottura atipica dell'aorta toracica, in sede retrocardiaca, con associata dissezione del tronco brachio-cefalico e rottura della milza, verificatesi in seguito ad un incidente stradale. L'esame angio-TC e l'angiografia preoperatoria hanno dimostrato la rottura dell'aorta toracica.

Conclusioni. Il trattamento combinato, endovascolare per l'aorta toracica retrocardiaca e chirurgico per il tronco brachio-cefalico, ha ridotto i rischi emodinamici e d'ischemia d'organo.

KEY WORDS: Thoracic aorta - Atypical rupture - Endovascular repair.
Aorta toracica - Rottura atipica - Riparazione endovascolare.

Introduction

The traumatic rupture of thoracic aorta is the most frequent cause of aortic emergency. The rupture is usually located in the isthmic aorta. Open surgery is associated with high mortality (1). The endovascular treatment of the thoracic aortic diseases offers a realistic alternative to open surgery and demonstrates a lower perioperative morbidity and mortality if compared to conventional technique (2).

We report the case of a patient with atypical rupture of thoracic aorta and dissection of brachiocephalic trunk associated with splenic rupture.

We decided a combined treatment, endovascular for retrocardiac thoracic aorta and open for brachiocephalic trunk, in order to diminish the hemodynamic, metabolic and organ ischemic complications (medullar ischaemia specially) associated with open surgery (3).

Case report

We describe the case of a 19 years old man who, after a road accident, was taken at Emergency Department for thoracic and abdominal pain with normal hemodynamic and neurological state.

The X-ray of chest demonstrated mediastinic widening and CT scan of chest and abdomen showed a dissection of brachiocephalic trunk and rupture of retrocardiac aorta with mediastinic hematoma and splenic bruises (Fig. 1).

After CT scan the patient presented a severe hypotension and bradycardia associated with lypothimia; electrocardiogram showed ST-segment elevations through leads V1-V3 revealing a severe myocardial ischaemia. Haemoglobin was 5.8 mg/dl.

"G. Martino" University Hospital, Messina, Italy
Unit of Vascular Surgery

© Copyright 2008, CIC Edizioni Internazionali, Roma

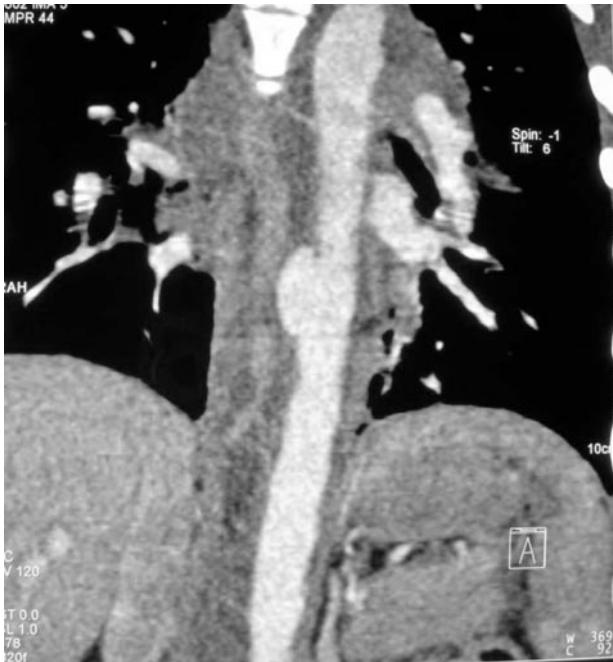

Fig. 1 - CT scan: rupture of retrocardiac thoracic aorta.

We took urgently the patient to operatory room. We performed a catheterization of right femoral artery and left brachial artery. The arteriography confirmed a retrocardiac rupture of thoracic aorta and a little ostial dissection of brachiocephalic trunk. We positioned Cook Zenith device (24-24 mm of diameter and 10 mm of length) in the side of rupture by surgical access of left femoral artery. The postprocedure angiography showed a perfect repair of thoracic aorta (Fig. 2).

The postprocedure abdominal echography showed an hypoechogenic perisplenic area revealing a splenic rupture, so we had to perform a xifo-umbilical laparotomy and a splenectomy. In the postoperative period, haemoglobin and hemodynamic conditions were stabilized but color-Doppler of supraortic trunks showed an extension of the dissection on the brachiocephalic trunk without neurological deficit. Then we performed a sternotomy and a prosthesis by pass between aorta and brachiocephalic trunk with termino-lateral anastomosis on the descending aorta and termino-terminal on the brachiocephalic trunk with ligation of distal stump. There weren't any neurological and cardiologic complications.

After two years, the CT follow-up demonstrated the absence of endoleak and the patency of bypass.

Discussion

The traumatic rupture of thoracic aorta is characterized by an high mortality. In literature the risk of spontaneous rupture is 8.8% in the first 30 hours and

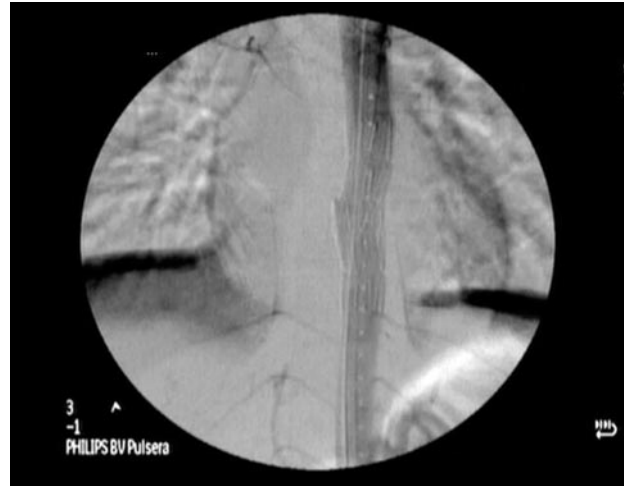


Fig. 2 - Postprocedure angiography: repair of thoracic aorta.

72% in the first week in patients hemodynamically stable at admission in Emergency Department (4). The isthmic aorta is more interested in the traumatic rupture. The ruptures are generally subadventitial, circumferential or partial (in an case in the concavity of isthmic aorta) (5, 6).

The aortic lesion of our patient is particular because it is a retrocardiac rupture, interposed between the diaphragmatic pillars, and for the unusual pathophysiologic mechanism. In fact, literature doesn't report traumatic lesions in the retrocardiac aorta where there is a protective action of diaphragmatic muscles and a higher resistance of the surrounding structures. The pathophysiologic mechanism could be explicated by a sudden deceleration generating a velocity gradient in descending aorta. This condition occurred in systole and the radial force of contusion slid the heart injuring the aortic wall.

The X-ray chest performed in emergency showed indirect signs of aortic rupture and CT scan provided us useful informations. Aortography is an invasive examination but also the gold standard in the traumatic lesions of thoracic aorta and it was conclusive for our diagnosis and the choice of endoprosthesis.

We preferred the hybrid treatment because of the high mortality and morbidity of totally open treatment. In fact, the endovascular repair of the atypical aortic rupture allowed us to avoid the substitution of thoracic aorta (and, consequently, the possible risk of a medullary ischaemia) and to perform the aorto-brachiocephalic bypass.

References

1. Bell RE, Taylor PR, Aukett M, Sabharwal T, Reidy JF. Results of urgent and emergency thoracic procedures treated by endoluminal repair. *Eur J Vasc Endovasc Surg.* 2003;25 (6):527-31.
 2. Fattori R, Nienaber CA, Rousseau H, et al. Results of endovascular repair of the thoracic aorta with the Talent Thoracic stent graft: the Talent Thoracic Retrospective Registry. *J Thorac Cardiovascul Surg* 2006;132(2):332-339.
 3. Svensson LG, Crawford ES, Hess KR, Coselli JS, Safi HJ. Experience with 1509 patients undergoing thoracoabdominal aortic operations. *J Vasc Surg* 1993;17:357-68.
 4. Fabian TC, Croce MA, et al. Prospective Study of blunt Aortic injury: multicenter trial of the American Association for the Surgery of trauma. *J Trauma* 1997;42:347-383.
 5. Schmidt CA, Wood MN, Razzouk AJ, et al. Primary repair of traumatic aortic rupture: a preferred approach. *J Trauma* 1992;32:588-592.
 6. Turney SZ, Rodriguez A. Injuries to the great thoracic vessels. In: Turney SZ, Rodriguez A, Cowley RA, Eds. *Management of cardiothoracic trauma.* Baltimore: Williams end Wilkins, 1990:229-260.
-