

## Isolated giant mesenteric fibromatosis (intra-abdominal desmoid tumors). Case report

K. SPIRIDAKIS, G. PANAGIOTAKIS, M. GRIGORAKI, I. KOKKINOS, T. PAPADAKIS,  
T. KOKKINAKIS, S. KANDYLAKIS

**SUMMARY:** Isolated giant mesenteric fibromatosis (intra-abdominal desmoid tumors). Case report.

K. SPIRIDAKIS, G. PANAGIOTAKIS, M. GRIGORAKI, I. KOKKINOS,  
T. PAPADAKIS, T. KOKKINAKIS, S. KANDYLAKIS

*A rare case of isolated giant mesenteric fibromatosis is presented. The tumor originated from the fibrous mesenteric tissue. The patient underwent laparotomy because of abdominal discomfort and subocclusive symptoms due to the giant mass. Differential diagnosis of mesenteric masses is discussed and the Authors also review the literature concerning this rare disease.*

**RIASSUNTO:** Fibromatosi mesenterica gigante (tumore e desmoide intra-addominale). Case report.

K. SPIRIDAKIS, G. PANAGIOTAKIS, M. GRIGORAKI, I. KOKKINOS,  
T. PAPADAKIS, T. KOKKINAKIS, S. KANDYLAKIS

*La fibromatosi mesenterica o tumore desmoide è una rara neoplasia. Presentiamo un caso di fibromatosi mesenterica gigante. Per l'occlusione intestinale che la massa aveva provocato, il paziente è stato sottoposto ad intervento chirurgico con asportazione dell'intero tumore e parte dell'intestino tenue (20 cm). Gli Autori, dopo una revisione della letteratura su questo argomento, discutono la diagnosi differenziale con altri tumori intra-addominali e le strategie terapeutiche.*

**KEY WORDS:** Mesenteric fibromatosis - Desmoid tumors - Surgery.  
Fibromatosi mesenterica - Tumori desmoidi - Chirurgia.

### Introduction

Mesenteric fibromatosis is a group of disorders characterized by fibroblastic proliferation, without evidence of inflammation or neoplasia (1). They may assume diffuse, multifocal or localized nodular forms (2, 3). The localized nodular form has been called "desmoid tumor". Desmoid tumours (fibromatosis) are quite rare, occurring in an estimated 3,7 new cases per million/years (2).

Mesenteric fibromatosis is a "desmoid tumor" of the mesentery and constitutes a benign intra-abdominal lesion (4, 5), characterized by proliferation of fibrous tissue with biological behavior intermediate between benign fibrous lesions and fibrosarcomas.

Although rare, the primary desmoid tumor (fibromatosis) can develop in any age but is more common

in persons aged 10-40 years (3). The lesion's etiology remains unclear (4).

We present a rare case of a giant mesenteric tumor not associated with Gardner's syndrome or previous abdominal surgery or familial polyposis of the colon. We also review the literature concerning this extremely rare disease.

### Case report

A 43 years old Caucasian male was admitted to our Surgical Department because of abdominal discomfort and subocclusive symptoms. The physical examination revealed an abnormal abdominal mass (Fig. 1), well circumscribed.

The ultrasound examination diagnosed a well marginated mass all over the abdomen. The CT scan confirms a well circumscribed mass occupying all the abdomen with dislocation of the intrabdominal organs (Figs. 2, 3 and 4). The colonoscopy was negative.

The patient underwent laparotomy, via an abdominal incision extending down to the pubic symphysis with lateral spread, during which an extremely large mesenteric mass, encompassing the most of the vascular supply of the small bowel, was found, adherent to the ileus for about 20 cm. The mass was completely excised. Macroscopic examination of the specimen showed a 35x23x29 cm capsulated, well circumscribed mass (Figs. 5 and 6).

Iraklion Crete, Greece  
General Hospital Venizeleion  
Department of Surgery  
(Chief: Dott. S. Kandilakis)

© Copyright 2008, CIC Edizioni Internazionali, Roma

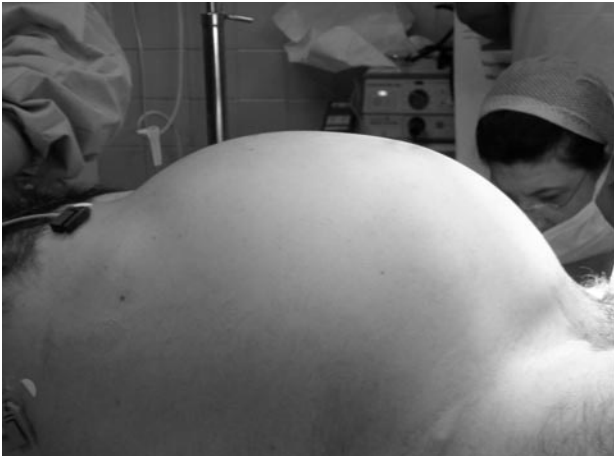


Fig. 1 - Abnormal abdominal mass.

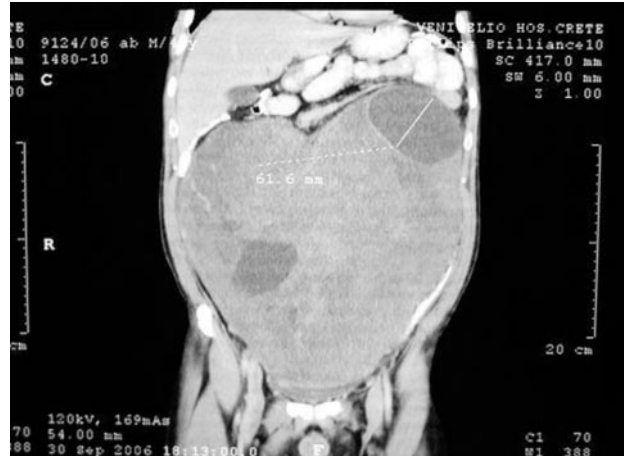

Fig. 4 - CT scan.

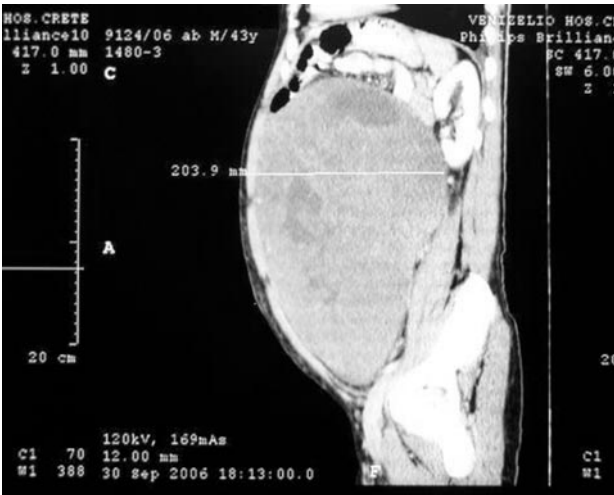

Fig. 2 - CT scan. Well circumscribed mass occupying all the abdomen with dislocation of the intra-abdominal organs.

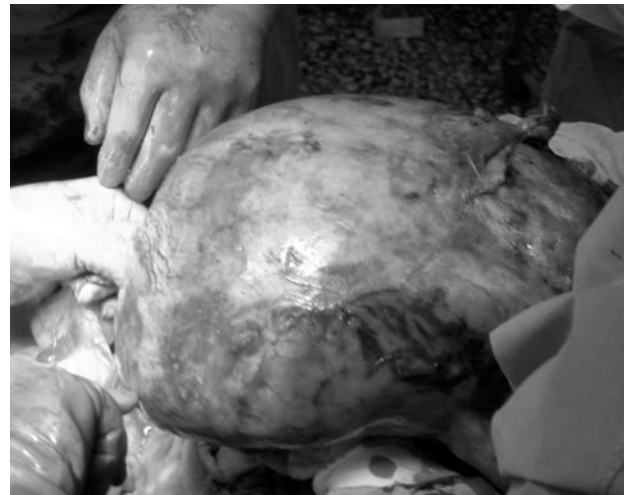

Fig. 5 - Excision of the desmoid tumor.

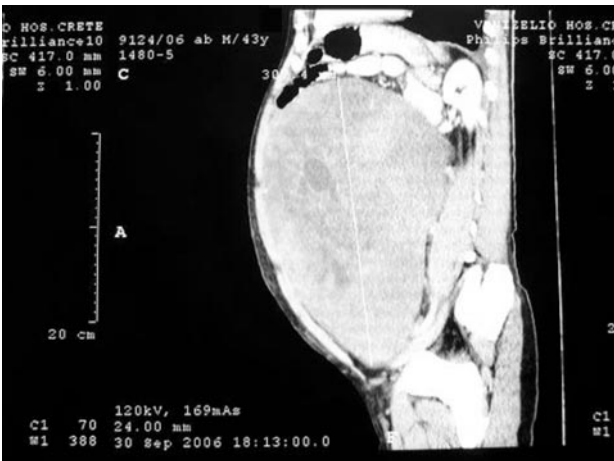

Fig. 3 - CT scan.

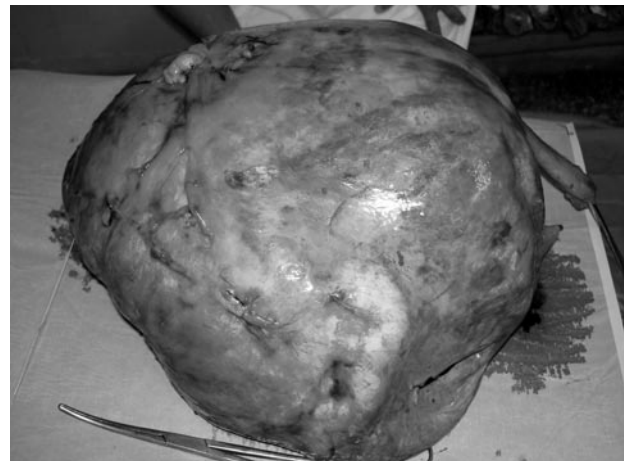


Fig. 6 - Specimen of the giant mesenteric tumor (intra-abdominal desmoid tumor).

The postoperative course was regular. On the 5<sup>th</sup> day oral nutrition was started and on the 8<sup>th</sup> day the patient was discharged.

The histological examination of the specimen demonstrated the mesenteric fibromatosis (desmoid tumor) without mitosis and with c-Kit, CD34, CD94, S100 negativity.

## **Discussion and conclusions**

Abdominal desmoid tumors arise from the fibrous mesenteric tissue (6). The term “desmoid” created by Muller in 1838, is derived from the greek word “desmos” which means tendon-like (9, 18).

The primary intra-abdominal fibromatosis of the mesenterium is a rare variant of benign stromal neoplasm of the fibroblast-myofibroblast. It may be secondary to trauma or may be associated with familial polyposis of the colon or Gardner’s syndrome (7, 8). Desmoids are rare lesions with an estimated incidence of 3,7 new cases/million population/year. They may occur in the abdominal wall, the mesenterium or the retroperitoneum (6, 10-12).

Demographically, the desmoid tumors may occur in all age groups but they are most common in the third and fourth decades of life (13). Females are more affected than males. However, in one of the largest study in the literature, with 130 cases, 55% of the cases occurred in men (13, 14).

They are locally aggressive tumors, with the possibility of invasion of the contiguous structures. Metastases however are not seen and these tumors are classified as benign tumors and histologically they are also benign fibrous neoplasms.

Mesenteric fibromatosis (desmoid tumors) vary in size from a few centimeters to tumors compassing the entire abdomen (15). These tumors have not been extensively reported in the literature. There is a small number of patients studied. Most mesenteric (desmoids) fibromatosis arise usually in the mesentery of the small bowel. Patients with Gardner’s syndrome are at higher risk than the others, as with patients after abdominal surgery, trauma or therapy with estrogens and those with familial polyposis of the colon (16).

Patients with mesenteric fibromatosis most frequently present with painless enlarging masses. Symptoms can be caused by compression of the adjacent structures and their vascular supply. The radiologic appearance may mimic other intraperitoneal tumors like lymphoma or carcinoma.

Mesenteric desmoid tumors appear as well demarcated solid masses containing occasionally dense internal echoes simulating mesenteric adenopathy, previously described as the “sandwich sign” (17).

The treatment is still controversial. Radical surgical excision is the treatment of choice, although local recurrence rate is as high as 50% as has been reported. The excision should be completed with a safe margin of 1cm. Most reports indicated that the local recurrence rate is higher with positive margins. The recommendation is to obtain negative margins if possible, but not at risk of the neurovascular structures.

Although the treatment is controversial, many Authors believe that the optional treatment has not yet been found. Post surgical recurrence rates as high as 77-85% favour the indication to non surgical therapy, such as steroidal anti-inflammatory drugs and antiestrogens. They support that the surgical treatment is reserved for the patients with bowel or urinary obstruction or intractable pain.

The imaging studies, like CT scan, US and MR, are used for the diagnosis and follow-up of the desmoid tumors. They can determine the extent of the tumor and its relationship to the nearby structures. CT scan is the most useful in confirming the mesenteric location of the mass and its homogeneous pattern. On CT scan, they appear as masses with soft tissue density, causing compression or dislocation of the adjacent structures (3).

The postoperative treatment includes radiotherapy, that may be used as treatment of recurrences, and estrogens and prostaglandins. The cancer markers CA. 19-9, CA. 125, AFP, and CEA can be not modified. The differential diagnosis of solid masses can include metastatic carcinoma, lymphoma intestinal carcinoid and mesenchymal tumors.

Metastatic carcinomas are usually multiple and uncommonly reach the size of mesenteric fibromatosis, without evidence of hemorrhage or necrosis. Gastrointestinal lymphoma may also be recognized by the presence of additional adenopathy in the mesenterium or the presence of splenomegaly. Mesenchymal tumors tend to have internal hemorrhage and necrosis before reaching the large size of mesenteric fibromatosis.

Although the differential diagnosis of mesenteric (desmoid) tumor or a recurrent tumor is very difficult, an important role has the histological examination of the surgical specimen to clear the diagnosis.

## References

1. Forte DM, Brant EB. Spontaneous Isolated Mesenteric fibromatosis. Report of a case. *Dis Col & Rect.* 1988;31(4):315-317.
2. Antony T. Desmoid tumors. *J Am Coll Surg* 1996;182:369-377.
3. Faria CS, Revathy BI, Ellis L, Whitman JG. Desmoid tumor of the small bowel and the mesentery. *AJR* 2004;183.
4. Colombo P, Rahal D, Grizzi F, Quaglinolo V, Roncalli M. Localized intraabdominal fibromatosis of the small bowel mimicking a gastrointestinal stromal tumor: a case report. *World J Gastroenterol* 2005;11(33):5226-5228.
5. Enzinger FM, Weiss SW. *Soft tissue tumors.* St. Louis Mosby 1983:45-70.
6. Bruke AP, Leslie H, Sobin LH, Shekitka KM. Mesenteric Fibromatosis. *Arch Pathol Lab Med* 1990;114:832-835.
7. Gold RS, Mucha SJ. Unique case of mesenteric fibromatosis in multiple polyposis. *Am J Surg* 1975; 130:366-369.
8. Corno F, Pera A, Toppino M, et al. La fibromatosi mesenterica nella syndrome di Gardner. *Minerva Chir* 1990;45(12): 895-898.
9. Schwartz RA. Desmoid tumor. *e-Medicine* 2006, p 1-7.
10. Sharihan H, Abes M, Yildiz K, et al. Mesenteric fibromatosis. Case report. *Eur J Pediatr Surg* 1998;8:107-110.
11. Jones IT, Fazio VW, Wenkley TL. Desmoid tumors in familial polyposis coli. *Ann Surg* 1985;204:94-97.
12. Einstein DM, Tagliabue JR, Desai RK. Abdominal desmoids: CT findings in 25 patients. *AJR* 1991;157:275-279.
13. Bruke AP, Sobin LH, Shekitka KM, Federspiel BH, Helwig EB. Intra-abdominal fibromatosis: a pathologic analysis of 130 tumors with comparison of clinical subgroups. *Am J Surg Pathol* 1990;14:335-341.
14. Baron RL, Joseph KT. Mesenteric Desmoid Tumors (sonographic and computed-tomographic appearance). *Radiology* 1981;140:777-779.
15. Pearman RO, Mayo CW. Desmoid tumors: a clinical and pathologic study. *Ann Surg* 1942;115:114-125.
16. Mueller PR, Ferruci JT Jr, Harbin WP, et al. Appearance of lymphomatous involvement of the mesentery by ultrasonography and body computed tomography. The "sandwich sign". *Radiology* 1960;134:467-473.
17. Seel DJ, Booher RJ, Joel R. Fibrous tumors of musculoaponeurotic origin. *Surgery* 1964;56:497-504.
18. Casillas J, Jais JG, Greve LJ, Iparraguirre CM, Morillo G. Imaging of intra- and extra-abdominal desmoid tumors. *Radio Grafics* 1991;11:959-968.