

Unusual acute onset of pedunculated extragastric leiomyosarcoma. Case report

G. GERACI, F. PISELLO, C. SCIUMÈ, F. LI VOLSI, L. PLATIA, T. FACELLA, G. MODICA

SUMMARY: Unusual acute onset of pedunculated extragastric leiomyosarcoma. Case report.

G. GERACI, F. PISELLO, C. SCIUMÈ, F. LI VOLSI, L. PLATIA, T. FACELLA, G. MODICA

Introduction: a case report of 25 yrs-old man with pedunculated exogastric leiomyosarcoma (with acute onset) surgically treated is presented.

Case report: the patient was operated after clinical, instrumental and blood sample tests. We performed a 5 cm wedge resection of the stomach in continuity with the omentum. Careful inspection revealed neither adenopathy nor metastases.

Results: actual complete remission of pathology. Negative 1 year follow up by endoscopy and CT.

Discussion: information on gastric leiomyosarcoma (LM), such as prognostic factors, patterns of disease recurrence, and optimal methods of treatment, are derived from limited clinical experience. Although about 25% of the gastric mesenchymal tumors present an exogastric growth, pedunculated exogastric leiomyosarcomas are extremely rare. Lymphatic spread of gastric LM is uncommon, therefore a formal lymph node dissection is not standard surgical management. At present, there is no evidence of intraperitoneal seeding from exogastric leiomyosarcomas. Consequently, a local resection with an adequate margin is sufficient when no invasion to the adjacent structures is observed. Neither the addition of lymphadenectomy nor the wider tumor-free margins of a radical gastrectomy seemed superior to the more conservative local excision.

Conclusions: further studies are called for to elucidate if exogastric tumours lead to peritoneal seeding and, thereby, affect tumour survival.

RIASSUNTO: Un caso di leiomiosarcoma extragastrico peduncolato ad esordio clinico acuto.

G. GERACI, F. PISELLO, C. SCIUMÈ, F. LI VOLSI, L. PLATIA, T. FACELLA, G. MODICA

Introduzione: presentiamo il caso di un soggetto giovane sottoposto ad intervento chirurgico per un leiomiosarcoma extragastrico peduncolato che si era presentato con una sintomatologia acuta.

Caso clinico: dopo valutazione clinica, strumentale e sieroematologica, il paziente veniva sottoposto ad intervento chirurgico di resezione di un lembo gastrico cuneiforme in blocco con l'omento. Non erano presenti linfadenopatie né metastasi.

Risultati: completa remissione della patologia con follow up endoscopico e radiologico entrambi negativi per recidiva.

Discussione: le informazioni sul leiomiosarcoma gastrico per quanto riguarda i fattori prognostici, i pattern di presentazione e di recidiva e il miglior metodo di trattamento derivano da una limitata esperienza riportata in letteratura. Benché quasi il 25% dei tumori mesenchimali gastrici abbia crescita esofitica, è estremamente raro il debutto clinico acuto di un leiomiosarcoma peduncolato extragastrico. Poiché la sua diffusione linfatica non è comune, non c'è indicazione in letteratura ad eseguire una linfadenectomia come per il carcinoma gastrico, né i dati attuali indicano evidenza di insemenza in intraperitoneale. Sulla base di questi dati, la resezione locale con adeguato margine e senza linfadenectomia sembra costituire il "gold standard" quando la neoplasia appare localizzata.

Conclusioni: ulteriori studi sono necessari per stabilire se i tumori stromali a crescita esogastrica possono causare insemenza in intraperitoneale che influenza negativamente la prognosi.

KEY WORDS: Leiomyosarcoma - Exogastric growth - Local surgical resection.
Leiomiosarcoma - Crescita esogastrica - Resezione locale cuneiforme.

Introduction

Gastric malignant tumours of smooth muscle (commonly known as leiomyosarcomas and leiomyoblastomas) comprise 0.1% to 3.0% of all malignant neoplasms of the stomach (1, 2).

Although about 10% to 20% of gastric leiomyosarcomas (LM) predominantly show an exogastric

Università degli Studi di Palermo
Azienda Ospedaliero Universitaria Policlinico "Paolo Giaccone"
Dipartimento di Chirurgia Generale, d'Urgenza e dei Trapianti d'Organo
Unità Operativa di Chirurgia Generale ad Indirizzo Toracico
(Direttore: Prof. G. Modica)

© Copyright 2007, CIC Edizioni Internazionali, Roma

growth, pedunculated ones (with narrow attachment to the muscularis propria) are extremely rare.

A case report of pedunculated exogastric LM is described.

Case report

A 25-year-old caucasian man was referred to our University hospital on July 2005: 2 days before the admission, he went to an emergency area for an acute and severe upper abdominal pain, radiating to dorsal region, followed by profuse sweating, and a lipotimic episode, without any other abdominal symptom (neither vomiting nor delay in gastric emptying or signs of constipation).

At the admission, the clinical examination was negative.

A computed tomography (CT) scan of the abdomen demonstrated, in the omental sac, the presence of a large median abdominal mass (18x8x12 cm), strictly adherent to the gastric angulus and posterior wall of the antrum, descending below the stomach

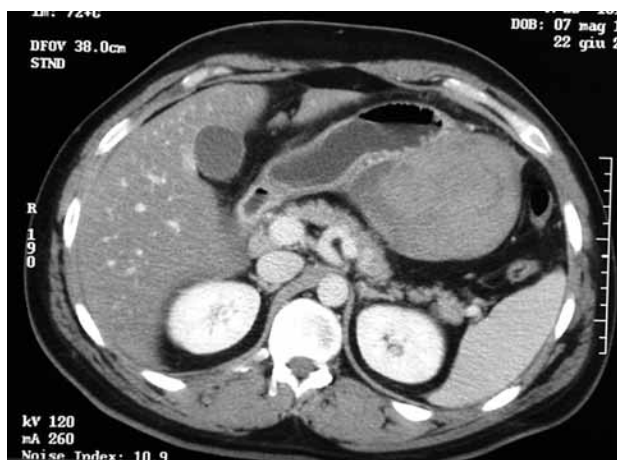

Fig. 1 - CT: a large median abdominal mass (18x8x12 cm) is present in omental sac strictly adherent to the gastric angulus and posterior wall of the antrum, descending below the stomach between pancreas and transverse colon.

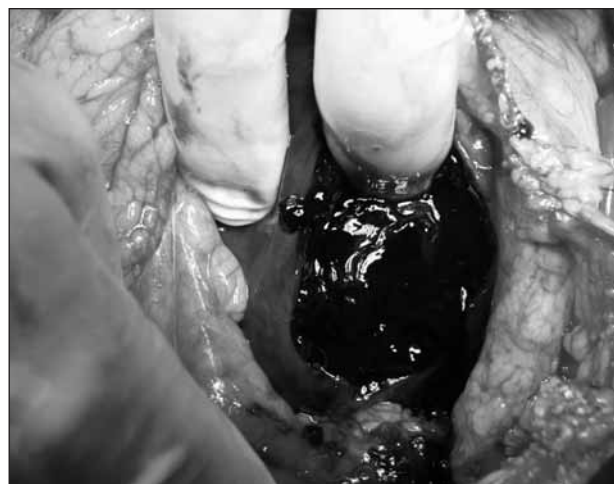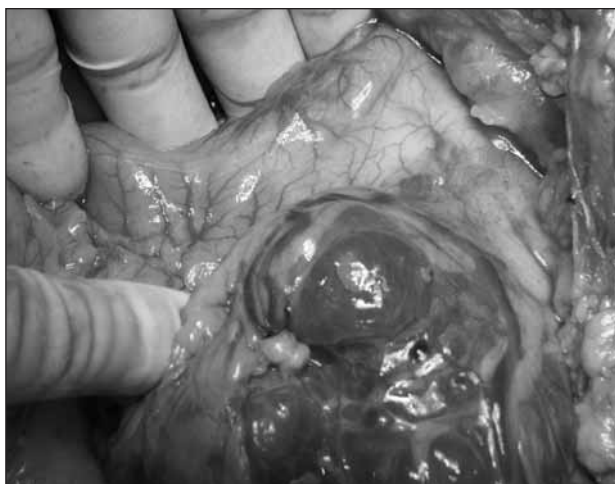between pancreas and transverse colon (Fig. 1). The density value of the mass were 50-70 HU for the left lateral and cervical part, 10-40 HU for the median one. The hypothesis of a haematic collection, containing clots partially organized and areas of recent bleeding, was likely suspected: hence the suspect of aneurism of an artery originating from the celiac axis organized in the omental sac. After haemodynamic stabilization, a selective arteriography of celiac axis and superior mesenteric artery was done: nevertheless no haematic spreading was visualized. Excluded the primitive vascular nature of the mass, it was considered a tumoral lump with internal acute haemorrhagic event. The admission laboratory findings were within the reference ranges. Gastric endoscopy didn't reveal any direct and indirect sign of compression.

With a diagnosis of intra-abdominal mass, the patient underwent laparotomy. Neither ascites nor active bleeding were observed. The tumor was located beneath the greater omentum, surrounded by the stomach superiorly, by the spleen laterally, by the mesocolon inferiorly and by the pancreas posteriorly. The tumor was a large, irregular and pedunculated solid mass arising from the greater curvature of the stomach near the antrum. It extended into the gastrocolic omentum and displaced the pancreas and transverse colon inferiorly, with an adjacent voluminous capsulated haematoma. Multiple dilated vessels were seen on its surface. Necrotic and hemorrhagic lesions were found in the wall of the tumour. The haematoma was removed (Figs. 2).

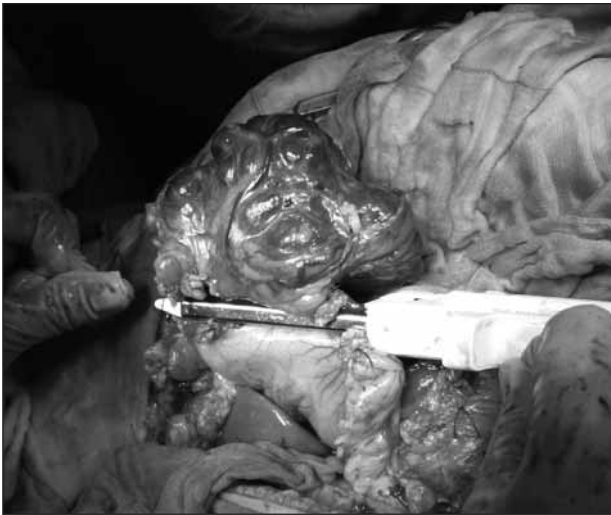
At the frozen section five suspected nodes were found free of neoplastic spreading, so the decision for a local stapler resection was based on the presumption that the tumor did not spread to adjacent tissues or nodes. Adhesions of the tumor to the parietal peritoneum were dissected and it was removed in continuity with the omentum ("en bloc") and a 5 cm wedge of the stomach resected by linear stapler (GIA 75, Ethicon Endosurgery®) (Figs. 3). Frozen section was negative for tumor. A careful inspection revealed neither adenopathies nor metastases.

The post-operative course was regular, without any complication and the patient was discharged in the VIII post-operative day.

Grossly, the tumor appeared to be a large, encapsulated, moderately firm, somewhat fluctuant mass, measuring 18x7x12 cm. It arose from the muscular wall of the stomach, predominantly bulging over the serosal surface. On a cut section, the tumour was in part pale, tan-white and "fishfleshy" with small areas of cystic degeneration and haemorrhage (25% of the volume) and in part with a soft consistence and pinky colour. Microscopically, the tumor showed morphological and immunological pattern of the



Figs. 2 - Intraoperative findings of exploration: the neoplasm.



Figs. 3 - Resection and specimen.

white-cells (epithelioid) leiomyosarcoma, CMA++, SMA++, DES+/-, S100-, CD117-, composed of polygonal cells with either eosinophilic or clear cytoplasm. Moderate cellular and nuclear pleomorphism, and mitoses were observed (> 5 x 10 HPF). The tumor was attached to the muscular layer of the gastric wall sparing the mucosal and submucosal layer. Spindle cells were microscopically confirmed to arise from the muscularis propria of the stomach. Many areas of cystic degeneration and haemorrhage were found (Fig. 4). The tumor appeared to have been completely resected (R0 resection) with no evidence of tumor spreading to the adjacent structures (hyperplasia of peritoneal mesothelial cells) or metastases into the 12 examined lymph nodes (chronic reactive aspecific flogosis).

The patient refused the antitlastic chemotherapy proposed by oncologists.

At one year follow-up as outpatient, we re-evaluated the patient for exclusion of metastases with ecosonography (negative) and CT (negative).

At present the patient is in good conditions with no clinical or radiological signs of relapse.

Discussion

Gastric LM is rare: it is placed within the submucosa and the muscularis propria. Bigger tumors extend into the gastric lumen or are exogastric; some of these have a dumb-bell shape, with a bulbous submucosal component, a constricted area in the muscularis propria, and a second bulbous component in the subserosa (3). Rarely, tumors are predominantly extramural with very narrow attachments to the outer layer of the muscularis propria such as in our case.

Although several studies investigated the clinicopathological features of mesenchymal tumors (leiomyomas, leiomyoblastomas, and LM) of the stomach, surprisingly few documented the frequency of pedunculated exogastric growth (2).

Clinically, gastrointestinal bleeding is found in

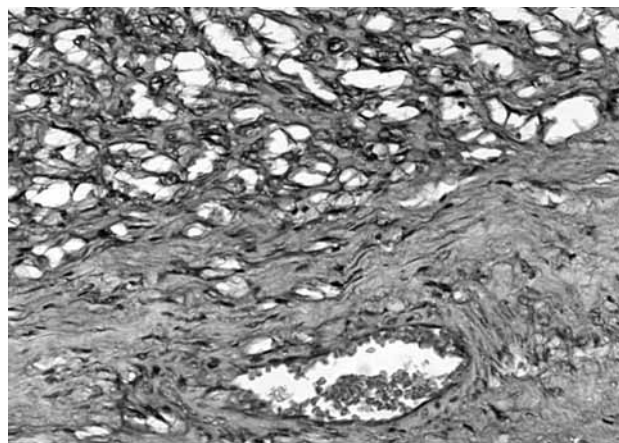


Fig. 4 - Histological features.

26% and pain/dyspepsia in 14%. Some patients (less than 10%) have a palpable mass or perforation, and obstruction is found only in 3% of patients (4).

In predominantly exogastric tumors, such as the case here described, either barium contrast or endoscopy may not be useful for diagnosis, but ultrasonography (US), selective angiography and CT are can detect them as tumors. In our case CT demonstrated the image of an intra-abdominal tumor, but it was impossible to determine the nature of the mass.

In our opinion, in the patients with exogastric tumour growth (CT-visualized), endoscopic ultrasonography (EUS) is not useful for diagnosis and therapeutic strategy and EUS-guided fine needle biopsy is contraindicated.

There has been much debate in the literature about the morphologic features separating GIST (Gastro-Intestinal Stromal Tumors) from other mesenchymal tu-

TABLE 1 - IMMUNOCHEMISTRY IN GISTS AND OTHER MESENCHYMAL GASTRO-INTESTINAL TUMORS (modified from ref. 12).

	c-Kit (CD117)	CD34	SMA	Desmin	S-100
GIST	pos	pos (60-70%)	pos (30-40%)	neg (rare pos)	neg (5% pos)
Epithelioid GIST	pos	pos	neg	neg	neg
Smooth muscle tumor	neg	pos (10-15%)	pos	pos	neg
Schwannoma	neg	pos	neg	neg	pos

mors (5); unfortunately, we still have little knowledge of the malignant potential of all mesenchymal tumors, which present a difficult management problem.

LM exhibit positive staining for SMA (smooth muscle actin), and are negative for CD117 antigen (c-Kit) and CD34, more commonly expressed in GISTs, that are defined as cellular spindle cell, epithelioid or occasionally pleomorphic mesenchymal tumors of the GI tract that express c-Kit protein (6, 12).

The GISTs definition shown in the Table 1 excludes gastro-intestinal true smooth muscle tumors, such as esophageal leiomyomas, small colorectal leiomyomas of the muscularis mucosae, and rare gastro-intestinal true LM, each of which have distinctive clinicopathologic features.

Although LM are almost invariably c-Kit-negative, some tumors other than GISTs (such as typical LM) may contain isolated c-Kit-positive cells. Considering that GISTs are typically diffuse c-Kit-positive, the sporadic c-Kit-positive cells in other tumors make very difficult the differential diagnosis (7). In fact, c-Kit-positive tumors are, on principle, GISTs, including most of tumors classified as leiomyoblastoma, epithelioid leiomyoma or LM before the introduction of new immunohistochemistry-based classification.

It is generally accepted that the treatment of choi-

ce in non-metastatic LM is surgery. The tumor can invade the adjacent structures directly; it generally doesn't spread to the regional lymph nodes. Therefore, radical surgery, as usually performed in carcinoma of the stomach, is not indicated unless metastases are detected. The pathological features resection with an adequate margin is sufficient, without systematic nodes dissection (3, 8-10). Radiotherapy and chemotherapy give little benefit. Therefore, recurrences should be treated with surgery.

The prognosis in these tumors depends on the histopathological grade, tumor size, and evidence of metastasis (4). No other parameter, including invasion, necrosis, cellularity, cytologic atypia, or mitotic rate has such a strong correlation with survival rate. The 5-year survival for patients with low-grade tumours is more than 90% versus less than 50% for high-grade tumours (9,11).

On the basis of rare nodal spread, laparoscopic wedge resection of the stomach can be considered a first-line treatment for gastric non-complicated LM.

Unfortunately, there is no data on the prognosis of patients with predominantly esogastric LM. Further studies are required to make clear whether exogastric tumours lead to peritoneal seeding and, thereby, affect tumour survival.

References

1. Sasako M, Kinoshita T, Maruyama K, Okabayashi K, Itabashi M, Hirota T. Surgical treatment for gastric leiomyosarcoma: clinicopathological study of 51 resected cases. *Jpn J Gastroenterol Surg* 1989;22:2212-2216.
2. Shimoji H, Iyazato H, Nakachi A, Shiraishi M, Muto Y, Toda T. Pedunculated exogastric leiomyosarcoma: case report and brief literature review. *Clinical Imaging* 1999;23:94-98.
3. Ng EH, Pollock RE, Munsell MF, Atkinson EN, Romsdahl MM. Prognostic factors influencing survival in gastrointestinal leiomyosarcomas. Implications for surgical management and staging. *Ann Surg* 1992;215:68-77.
4. Dougherty MJ, Compton C, Talbert M, Wood WC. Sarcomas of the gastrointestinal tract. Separation into favorable and unfavourable prognostic groups by mitotic count. *Ann Surg* 1991;214:569-574.
5. Lewin KJ, Appleman HD. Tumours of the Esophagus and Stomach. Atlas of Tumour Pathology, Third series, Fascicle 18. Washington, DC: Armed Forces Institute of Pathology 1996:405-439.
6. Fletcher CD, Berman JJ, Corless C, Gorstein F, Lasota J, Longley BJ. Diagnosis of gastrointestinal stromal tumors: a consensus approach. *Hum Pathol* 2002;33:459-465.
7. Miettinen M, Majidi M, Lasota J. Pathology and diagnostic criteria of gastrointestinal stromal tumors (GISTs): a review. *Europ J Cancer* 2002;38(Suppl. 5):S39-S51.
8. Koga H, Ochiai A, Nakanishi Y, Sasako M, Mizuno S, Ki-

Unusual acute onset of pedunculated extragastric leiomyosarcoma. Case report

- noshita T. Reevaluation of prognostic factors in gastric leiomyosarcoma. *Am J Gastroenterol* 1995;90:1307-1312.
9. Carson W, Karakousis C, Douglass H, Rao U, Palmer ML. Results of aggressive treatment of gastric sarcoma. *Ann Surg Oncol* 1994;1:244-251.
 10. Katai H, Sasako M, Sano T, Maruyama K. Surgical treatment of gastric leiomyosarcoma. *Ann Chir Gynaecol* 1998;87(4):293-296.
 11. Farrugia G, Kim CH, Grant CS, Zinsmeister AR. Leiomyosarcoma of the stomach: determinants of long-term survival. *Mayo Clin Proc* 1992;67:533-536.
 12. Fletcher CDM. The evolving classification of the soft tissue tumours: an update based on the new WHO classification. *Histopathology* 2006;48:3-12.
-