

The misdiagnosis of ruptured abdominal aortic aneurysm: an ancient problem always present. Report of an atypical case

L.F. CIARDO, F. AGRESTA, N. BEDIN

SUMMARY: The misdiagnosis of ruptured abdominal aortic aneurysm: an ancient problem always present. Report of an atypical case.

L.F. CIARDO, F. AGRESTA, N. BEDIN

The rupture of an abdominal aortic aneurysm is one of the most dramatic event in the daily clinical practice. It is often easily suspected when the classical signs of hemorrhagic shock are associated with an anterior (mesogastric) abdominal pain and an expanding mass, especially in the non-obese patients. Sometimes many of these signs can lack and, as a consequence, the diagnosis might be very difficult. This may cause a fatal delay for the patients.

We describe a singular case in which the rupture of an abdominal aortic aneurysm was simulating an acute cholecystitis: the presented symptoms, together with a negative personal medical history, were so atypical that even four experienced practitioners misdiagnosed the vascular lesion and the diagnosis was possible only at autopsy.

RIASSUNTO: L'errore diagnostico nell'aneurisma dell'aorta addominale in rottura: un vecchio ma sempre attuale problema. Su di un caso ad esordio atipico.

L.F. CIARDO, F. AGRESTA, N. BEDIN

La rottura di un aneurisma dell'aorta addominale è uno degli eventi più drammatici in cui può capitare di imbattersi durante la pratica clinica quotidiana. Tale evenienza è spesso facilmente sospettata, soprattutto in pazienti non obesi, quando i classici segni dello shock emorragico si associano ad un intenso ed acuto dolore addominale anteriore (mesogastrico) e alla presenza di una massa pulsante e rapidamente crescente in ambito addominale. Talvolta però tali segni possono essere scarsi o completamente assenti e di conseguenza la diagnosi può essere molto difficile. Tutto ciò può portare ad un ritardo fatale per il paziente.

Il nostro caso è una singolare presentazione di un aneurisma dell'aorta addominale in rottura simulante una colecistite acuta. Il quadro clinico, unito ad una storia personale del paziente priva di fattori di rischio, è stato così atipico e ingannevole che ben quattro medici esperti non sospettarono la patologia vascolare e la diagnosi fu fatta solo dall'anatomo-patologo in corso di accertamento autoptico.

KEY WORDS: Aortic aneurysm - Rupture - Misdiagnosis.
Aneurisma aortico - Rottura - Errore diagnostico.

Introduction

The rupture of an abdominal aortic aneurysm is one of the most dramatic event in the daily clinical practice. It is often easily suspected when the classical signs of hemorrhagic shock are associated with an anterior (mesogastric) abdominal pain and an expanding mass, especially in the non-obese patients. In these cases a prompt CT scan (which is not always possible to

perform 24 hours a day in every hospital setting) can confirm the diagnostic suspicion and allow an emergency surgical procedure. Sometimes many of these signs can lack and, as a consequence, the diagnosis might be very difficult. This may cause a fatal delay for the patients. In literature several cases of atypical presentation of this dramatic event simulating, i.e., nephroureterolithiasis or colonic disease are already reported.

We describe a singular case in which the rupture of an abdominal aortic aneurysm was simulating an acute cholecystitis. The presented symptoms, together with a negative personal medical history, were so atypical that even four experienced practitioners misdiagnosed the vascular lesion and the diagnosis was possible only at autopsy.

ULSS 7 Treviso
Ospedale Civile, Vittorio Veneto (TV)
Department of General Surgery
(Chief: Dott. N. Bedin)

© Copyright 2007, CIC Edizioni Internazionali, Roma

Case report

On December 2004 a 64 years old man, with a normal body-mass index and without any risk factors for vascular disease, was admitted to our institution with the diagnosis of acute cholecystitis from the Emergency Department. At the onset, four days before, was present a colic pain in the right hypocondrium without any other symptoms.

Four on call practitioners visited the patient in the emergency room and, after a routinely plain abdominal X-ray revealing small calcifications in the right hypocondrium evocative for gallstones, a diagnosis of acute cholecystitis was suspected.

The patient was sent home and the medical treatment with analgesic and antispastic drugs was successful. Due to the worsening of the symptoms, on the fourth day, he was visited again and finally admitted at 8.00 p.m. to our institution with the same diagnosis of acute cholecystitis. He was not in acute distress. Visited twice by our consultant surgeons, the physical examination did not reveal any other sign except of tenderness and rebound in the right hypocondrium. Abdominal masses, abnormal pulsing aorta or signs of peritonitis were absent. There was no sign of actual or incipient shock and the laboratory data were normal (blood haemoglobin was 17,3 g/dL).

Two hours after the admission the patient suddenly suffered for a cerebral hypoxia with an important neurological alteration as like as a cerebro-vascular accident. There was no hypotension. After ten minutes the patients partially recovered a conscious state and he did not referred any more the abdominal pain but, rather soon, a relapse of the above described status - this time together with a severe hypotension - was registered who brought the patient to die quickly. There was no time to make a CT scan or other examination except for a venous blood sample which, once received, revealed an important anaemia (blood haemoglobin was now 8,4 g/dL).

On the post-mortem examination a large retroperitoneal hemorrhage from a ruptured infrarenal aorto-right iliac aneurysm was found. Other pathologic findings were an hydropic lithiasic gallbladder and a colonic diverticulosis.

Discussion

Our case is a paradigm of an atypical presentation of a ruptured aortic aneurysm. Unfortunately for the patient the classical premonitory symptoms of rupture (i.e., mesogastric abdominal pain, hypotension and/or hypovolemic shock) were lacking and there was no time to make a prompt diagnosis and the subsequent surgical intervention. Nevertheless, in the literature reports of misdiagnosed ruptured aortic aneurysm, most of them mistaken as urinary tract or colonic disease (1-7) are already described.

Our report is a singular one due to the differential clinical diagnosis with an acute cholecystitis. The misdiagnosis was caused by many factors, and it is our opinion

that the human mistake is only in a minimal part responsible for the fatal event: in fact the pain localization in the right hypocondrium, with a positive Murphy's sign and the presence of small gallstones revealed by a routinely plain abdominal X-ray in the emergency room, were typical for acute cholecystitis (the post-mortem examination confirmed the presence of the gallstones together with an hydropic gallbladder). Moreover all the doctors which visited several times the patient did not find any abdominal pulsing mass; the peripheral arteries were normal and there were a lacking of any signs of actual or incipient hemorrhagic shock (the blood pressure at admission was 150/80 mmHg and it remained normal till the patient died).

In a clinical situation like this, a diagnosis of ruptured aortic aneurysm is hard to make and even to suspect. The only exam who would have helped and needed to correctly diagnose the rupture would have been an emergency abdominal computed tomography: unfortunately the clinical conditions of the patient at the admission were not serious to justify such urgent examination as the symptoms and the personal medical history did'nt require it. According with the supposed diagnosis of acute cholecystitis we scheduled for the morning after an ultrasound scan examination, performed by a specialist radiologist (who is only on call during the night at our hospital), in order to confirm the first suspected diagnosis. About this last examination, there is no a full agreement in literature about its effectiveness in the diagnosis of ruptured aortic aneurysm. Its role and importance in such case is debated and there are some reports in which its usefulness is denied (8) or reduced (1, 9).

According with the reports of literature (10, 11), we think that in our case a CT scan might have permitted the diagnosis but, due to the sudden rupture of the aneurysm and its fatal course, we think that probably it would have been of any utility in order to save the patient's life. We had no time to make the usual resuscitating maneuvers to stable his vital parameters and bring him into the operating room.

We think that it is important to give such reports and share the experience: in fact it permits to enlarge the knowledge of General and Specialist Practitioners with the hope of avoiding misdiagnosis. On the other hand, to say the truth, the presence in the literature of such atypical case could - we do hope - spare or limit any judicial consequences to the medical operators.

References

1. Borrero E, Queral LA. Symptomatic abdominal aortic aneurysm misdiagnosed as nephroureterolithiasis. *Ann Vasc Surg* 1988;2(2):145-9.
2. Kappey F, Eisen M, Strube HD. Die urologische Symptomatik des rupturierten infrarenalen Aortenaneurysmas. *Urologe A* 1975;14(6):263-8.

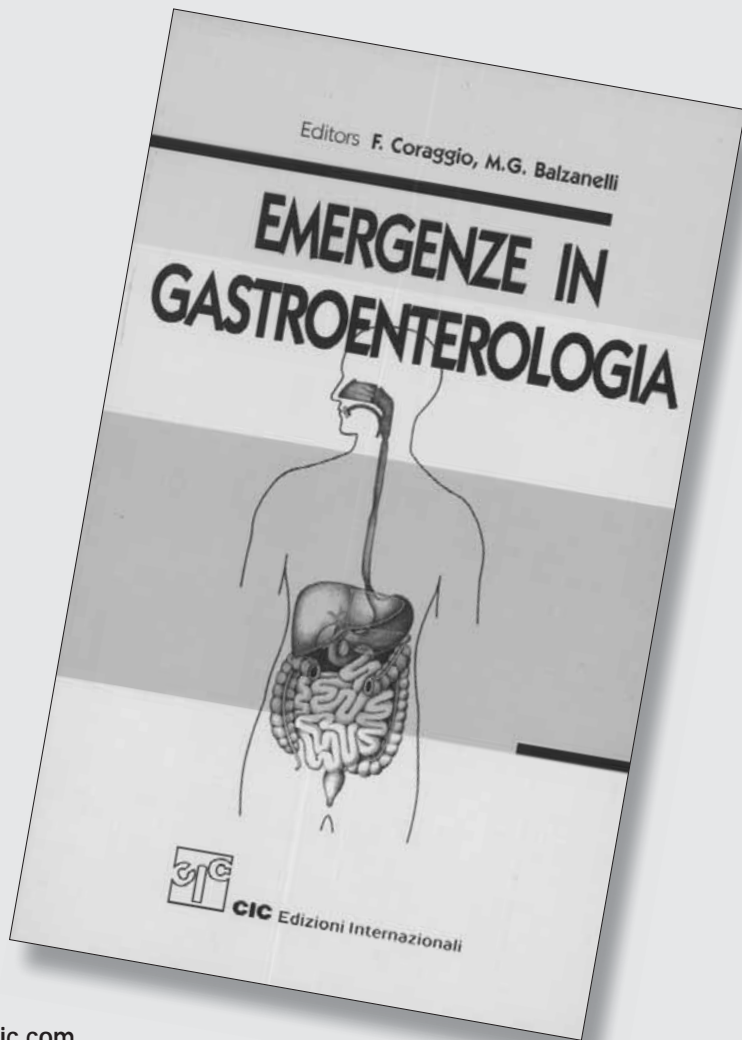
The misdiagnosis of ruptured abdominal aortic aneurysm: an ancient problem always present. Report of an atypical case

3. Salo JA, Verkkala KA, Ala-Kulju KV, Hweikkinene LO, Luosto RV. Hematuria is an indication of rupture of an abdominal aortic aneurysm into the vena cava. *J Vasc Surg* 1990;12(1):41-4.
 4. Scott HJ, Bearn PE, Scott RA. Ruptured abdominal aortic aneurysm presenting with acute urinary retention. *Br J Clin* 1992;46(1):73-4.
 5. Politoske EJ. Ruptured abdominal aortic aneurysm presenting as an obstruction of the left colon. *Am J Gastroenterol* 1990;85(6):745-747.
 6. Marston WA, Ahlquist R, Johnson G Jr, Meyer AA. Misdiagnosis of ruptured abdominal aortic aneurysms. *J Vasc Surg* 1992;16(1):17-22.
 7. Khaw H, Sottirai VS, Craighead CC, Batson RC. Ruptured abdominal aortic aneurysm presenting as symptomatic inguinal mass: report of six cases. *J Vasc Surg* 1986;4(4):384-9.
 8. Acheson AG, Graham AN, Weir C, Lee B. Prospective study on factors delaying surgery in ruptured abdominal aortic aneurysm. *J R Coll Surg Edinb* 1998;43(3):182-4.
 9. Akkerdijk GJ, Van Bockel JH. Ruptured abdominal aortic aneurysm: initial misdiagnosis and the effect on treatment. *Eur J Surg* 1998;164(1):29-34.
 10. Martin RS 3rd, Edwards WH Jr, Jenkins JM, Edwards WH Sr, Mulherin JL. Ruptured abdominal aortic aneurysm: a 25-years experience and analysis of recent cases. *Am Surg* 1988;54(9):539-543.
 11. Kvilekval KH, Best IM, Mason RA, Newton GB, Giron F. The value of computed tomography in the management of symptomatic abdominal aortic aneurysms. *J Vasc Surg* 1990;12(1):28-33.
-

F. Coraggio, M.G. Balzanelli (eds.)

EMERGENZE IN GASTROENTEROLOGIA

Volume
di 1.012 pagine
€ 35,00



per acquisti on line www.gruppocic.com



CIC Edizioni Internazionali