

## Combined resection and multi-agent adjuvant chemotherapy for intra-abdominal desmoplastic small round cell tumour: case report and review of the literature

F. TALARICO, D. IUSCO, L. NEGRI, D. BELINELLI

**SUMMARY:** Combined resection and multi-agent adjuvant chemotherapy for intra-abdominal desmoplastic small round cell tumour: case report and review of the literature.

F. TALARICO, D. IUSCO, L. NEGRI, D. BELINELLI

*Desmoplastic small round cell tumor (DSRCT) is a rare, highly aggressive malignancy with distinctive histological and immunohistochemical features occurring in young population with male predominance.*

*We report a case of DSRCT occurred in a 17 years old patient which presented with a large upper left quadrant abdominal mass that was treated with a very aggressive surgical approach and multi-agent chemotherapy. At a 12 months follow-up he is free of recurrence.*

*This kind of tumour has a very poor prognosis. No standard treatment protocol has been established. Aggressive surgery combined with postoperative multi-agent adjuvant chemotherapy is justified not only to relieve symptoms but also to try to improve the outcome.*

**RIASSUNTO:** Trattamento combinato resettivo polichemioterapico adiuvante per tumore desmoplastico a piccole cellule intraddominale: case report e revisione della letteratura.

F. TALARICO, D. IUSCO, L. NEGRI, D. BELINELLI

*I tumori desmoplastici a cellule rotonde sono delle neoplasie molto rare ed aggressive, con peculiari caratteristiche istologiche ed immunohistochimiche, che interessano soprattutto i maschi in giovane età.*

*Presentiamo un caso di un paziente di 17 anni affetto da tumore desmoplastico a cellule rotonde che si è manifestato con una voluminosa massa in ipocondrio sinistro ed è stato trattato con approccio combinato chirurgico e polichemioterapico.*

*Ad oggi per tale patologia non vi è trattamento standard e, quando possibile, un approccio chirurgico aggressivo e un trattamento polichemioterapico sembra la soluzione per migliorare sia la sintomatologia che la prognosi.*

**KEY WORDS:** Desmoplastic small round cell tumour - Surgery - Adjuvant chemotherapy.  
Tumore desmoplastico a piccole cellule rotonde - Chirurgia - Chemioterapia adiuvante.

### Introduction

Desmoplastic small round cell tumour (DSRCT) is an extremely rare and aggressive malignancy affecting most of the times young males in their second and third decades of life (1). This tumour, first described in 1989, is a member of the group of small round blue cell tumours (2) and involves mainly the abdomen and the pelvis, although thoracic, intracranial and paratesticular primary sites have been described (3). It usually has the tendency to spread along the peritoneum

and mesothelial lined-surface, so that organ involvement is only a secondary phenomenon (4).

Complete resection is generally difficult to obtain due to multiple foci and dissemination. A standard treatment protocol has not been well established. Association of surgery and chemotherapy seems to be the best potential treatment (5).

This work present a case of DSRCT with no recurrence after 12 months following complete resection of the tumour and postoperative multi-agent chemotherapy and underscore the main features of this disease.

### Case report

R.S., 17 years old male patient, presented in Emergency Room for stabbing left hypochondrium pain. His past medical history did not show any significant disease; two day before he had been accidentally hit on the left thorax. After this minor trauma, the pa-

Azienda Unità Sanitaria Locale Bologna  
Ospedale "SS. Salvatore", San Giovanni in Persiceto  
Dipartimento Chirurgico  
U.O di Chirurgia Generale  
(Responsabile: Dott. F. Talarico)

© Copyright 2007, CIC Edizioni Internazionali, Roma

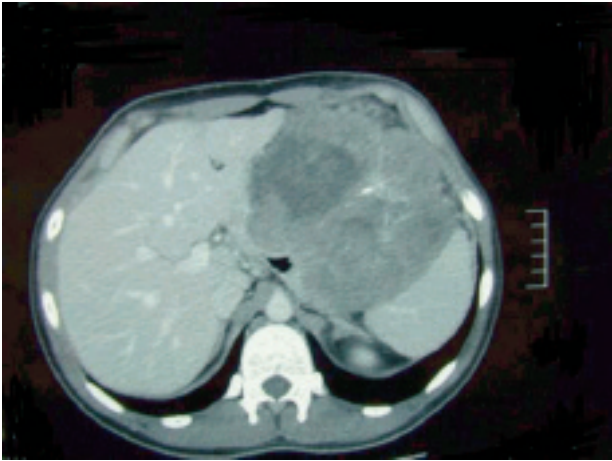


Fig. 1 - CT scan of the mass.

tient had pain while breathing and after two days this pain migrate in the left hypochondrium. The patients also declared a 10 kg weight loss in 4-5 month that was explained by him as the consequence of a diet.

On physical examination the abdomen was soft, not tender, and a 10 cm mass could be palpated in left hypochondrium without evoking pain. Laboratory tests were all normal. An ultrasound scan showed a 13 cm hypoechoic mass in left hypochondrium with some pleuric fluid on both sides. A CT scan confirmed the presence of the voluminous subdiaphragmatic round mass, with a solid content alternated to some areas of colliquation and some of calcification, that reached the inferior pole of the spleen and dislocated the stomach, the pancreas and the left colon. This mass was very close to the liver and infiltrated the splenic vascular pedicle (Fig. 1).

At laparotomy a voluminous neoplasm, arising from the retroperitoneum, that infiltrates the left side of the gastric body and antrum, the left lobe of the liver and the diaphragm, was evident (Fig. 2). A complete excision of the mass was performed *en bloc*

with splenectomy, longitudinal partial gastrectomy with a GEEA 80, regulated left liver lobectomy and partial resection of the diaphragm. The diaphragm was reconstructed by means of a patch of Gore-Tex.

Postoperative period was uneventful and the patient was discharged at VII day.

The macroscopic report of the pathologist showed a 18x20x14 cm ovoidal mass of white-gray hard tissue with a granulo-lose surface, and a soft and necrotic core. This mass infiltrates the stomach and neoplastic nodules were present in the omentum, the capsule of spleen and the liver, while the parenchyma was free of any infiltration.

The histological examination confirmed the presence of a high malignancy grade desmoplastic small round cell tumor of the retroperitoneum, with intraperitoneal multinodular dissemination. One lymph node of the lesser curvature resulted metastatic. Immunohistochemistry showed a marked positivity to vimentine, desmin and neuron-specific enolase. A positivity for cytocheratin was present in single cells. A complete negativity was observed for miogenin, smooth muscle cell actin, protein S-100, synaptophysin.

The patient underwent postoperative chemotherapy using the IVADo regimen (Ifosfamide 3 g/m<sup>2</sup> day 1 and 2; Vincristine 1,5 mg/m<sup>2</sup> day 1; Actinomycin D 1,5 mg/m<sup>2</sup> day 1; and Doxorubicin 30 mg/m<sup>2</sup> day 1 and 2). He is alive and free of recurrence at 12 months follow-up.

## Discussion

First described by Gerald and Rosai (6), DRSCT has distinct clinical, histological and polyphenotypic immunohistochemical features (7-9). The distinctive pathological finding of DRSCT is a nesting pattern of cellular growth within dense desmoplastic stroma and immunohistochemical coexpression of epithelial, muscle and neural markers (6, 8, 10). Genetic expression observed consistently in DRSCT reveals a unique reciprocal translocation - (t11;22)(p13;q11 or q12) - as

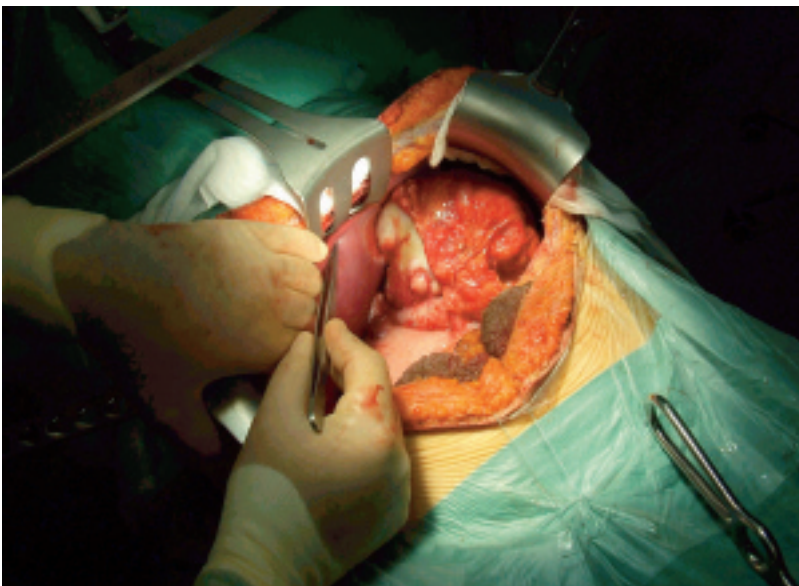

Fig. 2 - Laparotomy showing the mass infiltrating the stomach and the liver.

the result of fusion of exon 7 of Ewing's sarcoma gene (*EWS*) on chromosome 22 with exon 8 of Wilm's tumour suppressor gene (*WT1*) on chromosome 11 (11).

DRSCT usually occurs in young male with a male-female ratio of 5 to 1 and a mean age of 20 years (2, 8). The main features of this tumour is the striking predilection for serosal surfaces, mainly the peritoneum but also the pleura, and the tunica vaginalis of the testis, with only minor or no organ involvement. (7, 12) The most common site of presentation is the pelvis (62% of the cases) followed by spreading widely on the peritoneal surface (42%) (6, 8).

The most frequent presenting symptoms and signs reported in literature, such as abdominal pain, distension and a palpable abdomen, are non-specific and non-diagnostic (4). Many authors underscore that DRSCT present as a diffuse process within the abdomen without any apparent organ of origin (3, 13). Differently from extra-abdominal presentation, where this tumour is usually less extensive, in the abdomen and in the pelvis typically it presents in an advanced stage with a bulky primary mass and satellite nodules that fill the peritoneal cavity, as in our case (14). These large masses may simulate ovarian tumours or cysts in women and may also give urinary symptoms (8, 9, 12). Often lymph node, liver and lung metastasis coexist at the time of diagnosis (3).

Because of the tendency of DRSCT to involve the peritoneal and serosal surfaces with desmoplastic implant during the course of the disease, several patients may develop intestinal obstruction as a first manifestation, which will require either a debulking with intestinal resection or palliative bypass. Therefore it is important to consider DRSCT as a possible diagnosis when a young man presents with non-specific abdominal symptoms and evidence of disseminated intra- and extra-abdominal malignancy (4).

The most common diagnostic tool is CT scan. This shows a characteristic pattern of multiple intra-abdominal masses without apparent relationship with primary organs (11). An open biopsy may be useful for an accurate diagnosis so that the pattern of cellular nests can be seen. It enables histochemical tests to be carried out and may be used even in case of recurrence (11). Laparoscopy has also recently been used for biopsy of these tumours (11, 15).

Our case showed another distinctive feature of DRSCT, i.e. immunohistochemical polyphenotypic profile (cytocheratin, vimentine and neuron-specific enolase) suggestive of tripartite differentiation (epithelial, mesenchymal and neuroectodermal) (6).

The disease spread pattern reveals the predilection of these tumours to metastasise through both lymphatic and haematogenous routes, so combined surgery

and chemotherapy is needed for the management of this disease. The effect of complete resection of disseminated tumours on survival is still unknown because of the rarity of achieving it at operation. Some authors (16) reported a median survival of 20 months in 4 patients with complete resection of tumors compared with 11 months in 3 cases without complete resection. Significantly, long-term survivors, including one patient who survived for 101 months, have been treated with surgery and multi-agent chemotherapy.

Since DRSCT is a highly aggressive and progressive malignancy, postoperative adjuvant chemotherapy should be initiated as soon as possible. Farhat et al. (17) recommended that PAVEP (Cyclophosphamide 300 mg/m<sup>2</sup>, day 1-3; Etoposide 75 mg/m<sup>2</sup>, day 1-3; Doxorubicin 40 mg/m<sup>2</sup>, day 1; Cisplatin 100 mg/m<sup>2</sup>, day 4) should be the first line drug for treating DRSCT after reviewing 8 cases with complete remission. However, considering the severe and life-threatening side effects, such as grade four neutropenia, and uncertainty of the therapeutic results of PAVEP regimen, other safer and effective chemotherapeutic agents should be considered before it.

5-FU is well-known as a chemotherapeutic agent and a radioactive sensitizer broadly used for gastrointestinal tract cancers and disseminated intra-abdominal metastatic adenocarcinomas. Gerald et al. (8) reported a successful application of 5-FU in treating intra-abdominal DRSCT. Kretschmar et al (3) also reported 60% responsive rate to this chemotherapeutic agent. So it is reasonable to start chemotherapy with 5-FU especially in patient that had post-operative problems due to the extent of the resection and may not tolerate the adverse effect of the PAVEP regimen.

Another alkylator-based chemotherapy protocol named P6 (Cyclophosphamide, Doxorubicin, Vincristine, Ifosfamide, and Etoposide) was used to treat DRSCT but it only improved the progression-free survival without significant survival benefit (18).

The IVADo regimen (Ifosfamide 3 g/m<sup>2</sup> day 1 and 2; Vincristine 1,5 mg/m<sup>2</sup> day 1; Actinomycin D 1,5 mg/m<sup>2</sup> day 1; and Doxorubicin 30 mg/m<sup>2</sup> day 1 and 2) used in our case proved to be an intensive regimen that is very effective against pediatric sarcomas, whereas toxicity is manageable by expert oncologist teams, even if its role in the treatment of DRSCT is still to be well established with randomised trials (19).

Other authors recommended perioperative intra-peritoneal chemotherapy when treating DRSCT patients, but no evidence of prolonged survival was observed (16).

Radiotherapy can be applied preoperatively only in unresectable desmoid tumours and postoperatively for the control of local relapse in patients with microscopic residual disease following resection. The indication

of radiotherapy is still debated due to its late sequelae such as fibrosis and radiation-induced secondary malignancy (20).

The influence of other salvage therapies, such as immunotherapy or bone marrow ablation, is still undetermined even if preliminary results seems encouraging (21).

## Conclusion

The prognosis of DSRCT is dismal with a mean survival of 1.5-2.5 years since the wide spread of the

tumor makes radical resection difficult to achieve, and chemotherapeutic agents are often only temporarily effective in treating this disease (4).

No consensus has been reached concerning the optimal strategy for managing DRSCCT. Furthermore, because of the heterogeneity of the therapeutic modalities utilized, it is difficult to compare the efficacy and effectiveness of various regimens. However the current literature suggests that an aggressive approach involving total macroscopic excision of the tumour combined with chemotherapy and radiation may offer the best opportunity for disease control and disease free survival.

## References

1. Leuschner I, Radig K, Harms D. Desmoplastic small round cell tumour. *Semin Diagn Pathol* 1996; 20:406-412.
2. Gerald WL, Ladanyi M, de Alava E, Cuatrecasas M, Kushner BH, La Quaglia MP, Rosai J. Clinical, pathologic, and molecular spectrum of tumors associated with (t11;22)(p13;q12): desmoplastic small round-cell tumor and its variants. *J Clin Oncol* 1998;16:3028-36.
3. Kretschmar CS, Colbach C, Bhan I, Crombleholme TM. Desmoplastic small cell tumor: a report of three cases and a review of the literature. *J Pediatr Haematol Oncol* 1996; 18: 293-298.
4. Hassan I, Shyngan R, Donohue JH, Edmonson JH, Gundersen LL, Moir CR, Arndt CAS, Nascimento AG, Que FG. Intra-abdominal desmoplastic small round cell tumours. A diagnostic and therapeutic challenge. *Cancer* 2005;104:1264-70.
5. Chang-Cheng C, Jun-Te H, Jeng-Hwei T, Tsann-Long H, Han-Ming C, Yi-Yin J. Combined resection and multi-agent adjuvant chemotherapy for desmoplastic small round cell tumor arising in the abdominal cavity: report of a case. *World J Gastroenterol* 2006;12:800-3.
6. Gerald WL, Rosai J. Case 2. Desmoplastic small cell tumor with divergent differentiation. *Pediatr Pathol* 1989;9:177-83.
7. Cummings OW, Ulbright TM, Young RH, Del Tos AP, Fletcher CD, Hull MT. Desmoplastic small round cell tumors of the paratesticular region. A report of six cases. *Am J Surg Pathol* 1997;21:219-25.
8. Gerald WL, Miller HK, Battifora H, Miettinen M, Silva EG, Rosai J. Intra-abdominal desmoplastic small round-cell tumor. Report of 19 cases of a distinctive type of high-grade polyphe-notypic malignancy affecting young individuals. *Am J Surg Pathol* 1991;15:499-513.
9. Ordi J, de Alava E, Torne A, Mellado b, Pardo-Mindan J, Iglesias X, Cardesa A. Intraabdominal desmoplastic small round cell tumor with EWS/ERG fusion transcript. *Am J Surg Pathol* 1998 ;8:1026-32.
10. Ordóñez NG, el-Naggar AK, Ro JY, Silva EG, Mackay B. Intraabdominal desmoplastic small cell tumor: a light microscopic, immunocytochemical, ultrastructural, and flow cytometric study. *Hum Pathol* 1993; 24: 850-865
11. La Quaglia MP, Brennan MF. The clinical approach to desmoplastic small round cell tumour. *Surg Oncol* 2000;9: 77-81
12. Frappaz D, Bouffet E, Dolbeau D, Bouvier R, Carrie C, Louis D, Pondarre C, Tabone E, Phillip T, Brunat-Mentigny M. Desmoplastic small round cell tumour of the abdomen. *Cancer* 1994;73:1753-1756
13. Bisogno G, Roganovich J, Sotti G, et al. Desmoplastic small round cell tumor in children and adolescents. *Med Pediatr Oncol* 2000;34:228-342.
14. Wolf AN, Ladanyi M, Paull G, et al. The expanding clinical spectrum of desmoplastic small round cell tumor: a report of two cases with molecular confirmation. *Hum Pathol*. 1999;30:430-435
15. Roganovich J, Bisogno G, Cecchetto G, D'Amore E, Carli M. Paratesticular desmoplastic small round cell tumor: case report and review of the literature. *J Surg Oncol* 1999;71:269-72.
16. Gil A, Gomez Portilla A, Brun EA, Sugarbaker PH. Clinical perspective on desmoplastic small round-cell tumor. *Oncology* 2004; 67: 231-242.
17. Farhat F, Culine S, Lhomme C, Duvillard P, Soulie P, Michel G, Terrier-Lacombe MJ, Theodore C, Schreinerova M, Droz JP. Desmoplastic small round cell tumors: results of a four-drug chemotherapy regimen in five adult patients. *Cancer* 1996; 77:1363-1366.
18. Kurre P, Felgenhauer JL, Miser JS, Patterson K, Hawkins DS. Successful dose-intensive treatment of desmoplastic small round cell tumor in three children. *J Pediatr Haematol Oncol* 2000; 22: 446-450
19. Bisogno G, Ferrari A, Bergeron C, Scagnellato A, Prete A, Alaggio R, Casanova M, D'angelo P, Di Cataldo A, Carli M. The IVADo Regimen. A pilot study with Ifosfamide, Vincristine, Actinomycin D, and Doxorubicin in children with metastatic soft tissue sarcoma. *Cancer* 2005;103:1719-24
20. Schmidt BF, Koscielniak E, Pilz T, Treuner J. Radiation therapy in juvenile aggressive fibromatosis. *Klin Pediatr* 1999; 211:296-9.
21. Baltogiannis N, Mavridis G, Keramidis D. Intraabdominal desmoplastic small round cell tumour: report of two cases in paediatric patients. *Eur J Pediatr Surg* 2002;12:333-6.