

Endoscopic treatment of bilateral pheochromocytoma in MEN 2A syndrome: case report and review of the literature

D. IUSCO, L. SARLI, D. DI MAURO, V. VIOLI, L. RONCORONI

SUMMARY: Endoscopic treatment of bilateral pheochromocytoma in MEN 2A syndrome: case report and review of the literature.

D. IUSCO, L. SARLI, D. DI MAURO, V. VIOLI, L. RONCORONI

The benefits of laparoscopic adrenalectomy for single adrenal lesion have been well documented in literature; less experience though has been reported with simultaneous bilateral laparoscopic adrenalectomy. This operation is indicated in case of primary hypercortisolism caused by bilateral adrenocortical hyperfunction, Cushing's disease after failure of pituitary surgery, ectopic adrenocorticotropic hormone (ACTH) production by a tumour inaccessible for surgical intervention, and pheochromocytoma when it occurs bilaterally in case of multiple endocrine neoplasia type 2A and 2B. Different laparoscopic approaches have been described to perform this operation, such as the "anterior" approach (transperitoneal), the "lateral" approach (transperitoneal and retroperitoneal), and the "posterior" approach (retroperitoneal).

We report a case of bilateral laparoscopic adrenalectomy in a 33 years old female affected with bilateral pheochromocytoma due to multiple endocrine neoplasia type 2A treated with a bilateral transperitoneal laparoscopic adrenalectomy and disease free after 18 months follow-up.

RIASSUNTO: Trattamento laparoscopico del feocromocitoma bilaterale nella sindrome MEN 2A: case report e revisione della letteratura

D. IUSCO, L. SARLI, D. DI MAURO, V. VIOLI, L. RONCORONI

In letteratura sono ormai ben documentati i vantaggi della laparoscopia per le lesioni surrenaliche singole; minore è invece l'esperienza laparoscopica di surrenalectomia bilaterale. Questo tipo di intervento viene indicato in caso di ipercortisolismo primitivo causato da un'aumentata produzione surrenalica, morbo di Cushing dopo fallito trattamento chirurgico ipofisario, produzione ectopica di ormone adrenocorticotropo (ACTH) secreto da un tumore occulto o non operabile e feocromocitoma, che nel 10% dei casi è bilaterale ed è spesso legato a sindrome da neoplasie endocrine multiple (MEN) di tipo 2A e 2B. Diversi approcci laparoscopici sono stati descritti per questo tipo di intervento: uno "anteriore" (transperitoneale), uno "laterale" (transperitoneale e retroperitoneale) ed un approccio "posteriore" (retroperitoneale).

Presentiamo il caso di una paziente di 33 anni affetta da feocromocitoma bilaterale in MEN 2A trattata con surrenalectomia bilaterale laparoscopica transperitoneale e che è attualmente libera da malattia ad un follow-up di 18 mesi.

KEY WORDS: Pheochromocytoma - Adrenalectomy - Laparoscopy.
Feocromocitoma - Surrenalectomia - Laparoscopia.

Introduction

Laparoscopy has shown to be a safe and effective tool for the treatment of functioning and non functioning adrenal tumours, lowering the morbidity and the average hospital stay (1). Although the benefits of unilateral laparoscopic adrenalectomy have been well documented, less experience has been reported in literature

with simultaneous bilateral laparoscopic adrenalectomy (2).

We describe a case of bilateral pheochromocytoma in a patient with multiple endocrine neoplasia (MEN) 2A syndrome treated with synchronous laparoscopic bilateral adrenalectomy and we review the main topic highlighted in literature.

Case report

A 33 year old woman was referred to our Institution in June 2003. Past medical history showed total thyroidectomy and left lateral neck lymph node dissection for medullary carcinoma in 1997. A mutation in the protooncogene *RET*, which is associated with MEN 2A syndrome, was noticed by means of a genetic screening test. In April 2003 she started to have diastolic hypertension (100-110

Parma University, Medical School, Parma, Italy
Department of Surgical Sciences
Section of General Surgical Clinics and Surgical Therapy
(Head: Prof. L.Roncoroni)

© Copyright 2007, CIC Edizioni Internazionali, Roma

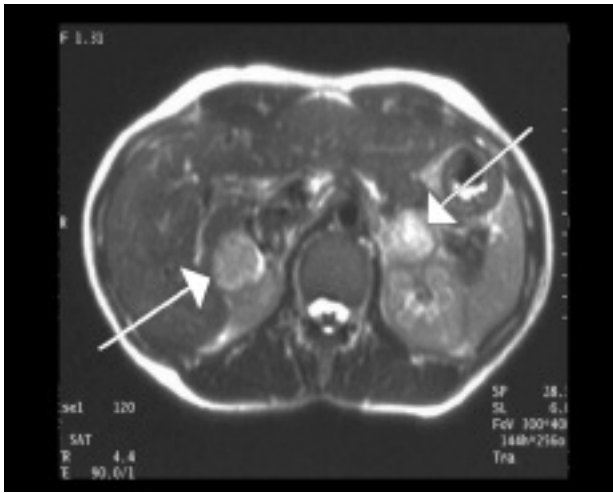


Fig. 1 - MR scan showing the bilateral adrenal mass.

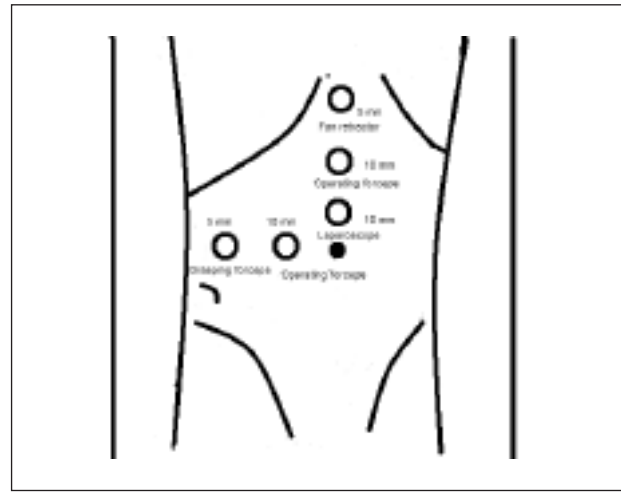


Fig. 2 - Trocars position for right transperitoneal adrenalectomy. Patient in supine position on the right side with 30° tilt achieved with the operating table.

mmHg), associated with some episodes of headache, palpitations and diaphoresis. Serological screen tests showed normal values except for the epinephrine which was 35.5 ng/L (normal range 1.7 – 22.4 ng/L). Dosage of urinary catecholamines and their metabolites was normal. Suspecting a pheochromocytoma on the basis of the patient genetic background and medical history, a total body CT and MR was performed which showed two nodules, one on the right adrenal gland (3 cm in diameter) and a second in the left adrenal gland (3,5 cm) (Fig. 1). Meta-iodo-benzylguanidine (MIBG) scan revealed hypercaptation on the left adrenal gland. The patient started pharmacological treatment with alpha and beta blockers and underwent surgery two weeks later.

The patient was placed in supine position with a 30° tilt on the right side. After the pneumoperitoneum induction by Verres needle, five trocars were positioned in a “reverse L” fashion (three 10 mm trocars, one for a 30° laparoscope, another two for operating forceps and two 5 mm trocars for the liver retractor and for grasping forceps) (Fig. 2).

The liver was elevated by retractor, and the peritoneum over the cava and in the Morrison space was excised by an hook coagulator. With bipolar laparoscopic forceps and monopolar scissors, the adrenal gland was dissected in a clock-wise direction from the fatty atmosphere of the Gerota fascia and from the lateral side of vena cava. The adrenal vein was identified, clipped and divided. The final dissection of the adrenal gland from the superior pole of the kidney was performed with ultrasound scalpel (Ultracision®, Ethicon) and an endobag was used to remove the tumour from the body. A drain was positioned in the Morrison space and the right sided trocar ports were closed.

The patient was then tilted 30° on the left side. The pneumoperitoneum was established again, and two additional trocars were placed, one 10 mm on the meeting point of the emiclavicular line and umbilical line and one 5 mm in the meeting point of the anterior axillary line and the umbilical line (Fig. 3).

The splenorenal and the splenocolic ligaments were excised so that the spleen could be moved medially and the splenic colonic angle was lowered. The kidney and the Gerota's fascia were exposed and with bipolar laparoscopic forceps and monopolar scissors the adrenal gland and the tumour were dissected. After its isolation and clipping, the adrenal vein was divided and the specimen was placed into the endobag and removed through the larger port.

The operation lasted 300 minutes approximately.

Intraoperative period was complicated by the sudden onset of an hypertensive peak (200/140 mmHg), cardiac bigeminism and a ST-

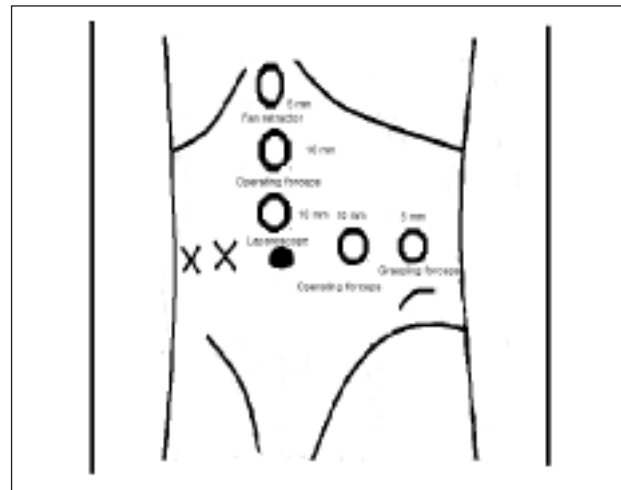


Fig. 3 - Trocars position for left transperitoneal adrenalectomy. Patient in supine position on the left side with 30° tilt achieved with the operating table.

segment depression on ECG, that was controlled with xylocaine and sodium nitroprusside.

Postoperative period was uneventful. The patient started steroid replacement on first postoperative day. She was allowed to eat and drink on the first postoperative day and the drains were taken out on the second. The patient was discharged on the fourth postoperative day. The patient is doing well at 18 months follow-up.

Discussion

The most frequent indications for synchronous bilateral laparoscopic adrenalectomy include primary hypercortisolism caused by bilateral adrenocortical hyperfunction (3), Cushing's disease after failure of pituitary surgery, and ectopic adrenocorticotrophic hormone (ACTH) production by a tumour inaccessible for surgical intervention (4). Pheochromocytoma, that occurs

bilaterally in 10% of cases often linked to cases of multiple endocrine neoplasia type 2A and 2B, and congenital adrenal hyperplasia are also found as indications for bilateral adrenalectomy (5).

Our case describes the treatment of bilateral pheochromocytoma by a transperitoneal anterior synchronous bilateral adrenalectomy in a patient with a MEN 2A syndrome.

Differently from traditional open bilateral adrenalectomy - which is associated with a high rate of surgical complications including intraoperative and postoperative bleeding (22%), pancreatic fistula, incisional hernia (10%), and wound healing impairment (13,5%) as well as general complications - bilateral laparoscopic adrenalectomy is feasible and seems to be associated with a lower operative risk (6-8). However the reported rate of complications is higher than the one reported for unilateral laparoscopic adrenalectomy (9). Since only few cases are described, the absence of intra- and postoperative complications in our case may contribute to lower the total rate of complications reported for this surgical procedure.

Different surgical approaches are described to perform laparoscopic synchronous bilateral adrenalectomy: the "anterior" transperitoneal approach, with patient in the supine position, the "lateral" transperitoneal or retroperitoneal approach, with patient in lateral decubitus position, and the "posterior" retroperitoneal approach with patient in prone position (7, 10, 11). There are no published randomized trial comparing the different approaches and each of these has advantages and disadvantages. We think that such trial would be very hardly done due to the low number of patients needing such treatment; for this reason, we consider useful to report experiences, even the ones with single case, that may give a contribution to the scientific discussion.

We have chosen the anterior transperitoneal laparoscopic approach because it allows a perfect orientation along anatomic landmarks and, particularly for the right lateral procedure, an early ligation of the suprarenal vein to avoid vena cava bleeding that constitutes the most dangerous complication of the entire procedure (12-14). In addition, since this approach does not require a changing in the patient's position but only a 30° lateral tilt achievable by operating table, a fair amount of operation time is saved.

Laparoscopic lateral approach has been frequently described for this kind of operation; it makes mobilisation of abdominal organs less difficult due to effect of gravity upon organs, and when performed with retroperitoneal approach provides direct access to the adrenal gland (15). We did not prefer the lateral approach because of the time spent in changing patient's position, and because of the difficulty in the orientation in the retroperitoneal space, which is less readily achieved with

this approach, and also for the longer learning curve.

Even the posterior approach has been described for bilateral laparoscopic adrenalectomy: it does not require the time for repositioning of the patient, it allows a direct access to the adrenal glands vessels, and it is useful in case of patient with multiple intrabdominal adhesions. Disadvantages of this approach - that made us not to use it - are the very narrow operation field, which allows to operate only small tumours and makes difficult vascular control and impossible to explore intraperitoneal structures (11).

Bonjer suggested an interesting combination of approaches which consisted in a right lateral transperitoneal and left lateral retroperitoneal adrenalectomy with the patient in lateral position (11); this approach eliminated the time for mobilisation of the left hypocondrium organs. Nevertheless an important criterion for the choice of the optimal technique is the operator's preference and his experience with a particular method.

In the case reported we chose to perform right adrenalectomy first because we consider the dissection and the section of the right adrenal vein technically the most demanding phase of the operation, so we prefer to perform it when the operating field was clear and the operating surgeons were less tired. We preferred to remove the right tumour from the body and to insert the drain in the Morrison space immediately after right adrenalectomy, because the following change of position of the patient to perform left adrenalectomy would made difficult the positioning of the drain and the tracing of the excised tumour.

During both adrenalectomies we pay particular attention not to manipulate the glands with surgical instruments in order to avoid any increment of catecholamines in the blood stream. We, in agreement with other authors (5), consider that the laparoscopic approach, compared with the open one, makes more easy the effort to avoid any manipulation of the adrenal tumour.

Our operating time, similarly to those reported literature (1), was fairly long. This important amount of time spent during the operation is probably due to the fact that our experience, like most of the cases reported in literature, was the first experience with the simultaneous bilateral procedure.

Conclusion

In conclusion we can confirm that bilateral laparoscopic adrenalectomy is feasible and safe. The absence of intra- and postoperative complications in our case may contribute to lower the total rate of complications reported in literature for this surgical procedure. Laparoscopy is the recommendable procedure for bilateral adrenalectomy.

References

1. Kebebew E, Siperstein AE, Duh QY. Laparoscopic adrenalectomy: the optimal surgical approach. *J Laparoendosc Adv Surg Tech A* 2001;11(6):409-13.
2. Zimmerman P, DaSilva M, Newman T, Marx W, Simon H. Simultaneous bilateral laparoscopic adrenalectomy: a surgical option for multiple endocrine neoplasia (MEN 2) patients with bilateral pheochromocytomas. *Surg Endosc* 2004;18(5):870.
3. Porpiglia F, Fiori C, Bovio S, Destefanis P, Ali A, Terrone C, Fontana D, Scarpa RM, Tempia A, Terzolo M. Bilateral adrenalectomy for Cushing's syndrome: a comparison between laparoscopy and open surgery. *J Endocrinol Invest* 2004;27(7):654.
4. Jager F, Heintz A, Junginger T. Synchronous bilateral endoscopic adrenalectomy: experiences after 18 operations. *Surg Endosc* 2004;18(2):314-8.
5. Brunt LM, Laimore TC, Doherty GM, Quasebarth MA, DeBenedetti M, Moley JF. Adrenalectomy for familial pheochromocytoma in the laparoscopic era. *Ann Surg* 2002;235:713-712.
6. Mikhail AA, Tolhurst SR, Orvieto MA, Stockton BR, Zorn KC, Weiss RE, Kaplan EL, Shalhav AL. Open versus laparoscopic simultaneous bilateral adrenalectomy. *Urology* 2006;67(4):693-6.
7. Brunt LM, Doherty GM, Norton JA et al. Laparoscopic compared to open adrenalectomy for benign adrenal neoplasms. *J Am Coll Surg* 1996;183:1-10.
8. Thompson G, Grant C, van Heerden JA, Shlinkert RT, Young WF, Farley DR, Ilstrup DM. Laparoscopic versus open posterior adrenalectomy: a case control study of 100 patients. *Surgery* 1997;122:1132-1136.
9. O'Riordain DS, Farley DR, Young WF, Grant JS, Van Heerden JA. Long term outcome of bilateral adrenalectomy in patients with Cushing's syndrome. *Surgery* 1994;116:1088-93.
10. Hsu TH, Gill IS. Bilateral laparoscopic adrenalectomy: retroperitoneal and transperitoneal approaches. *Urology* 2002;59(2):184-9.
11. Bonjer HJ, Sorm V, Berends FJ, Kaziemer G, Steyerberg EW, de Herder WW, Bruining HA. Endoscopic retroperitoneal adrenalectomy: lessons learned from 111 consecutive cases. *Ann Surg* 2000;232:796-803.
12. Buell JF, Alexander HR, Norton JA, Yu KC, Franker DL. Bilateral adrenalectomy for Cushing syndrome: anterior versus posterior approach *Ann Surg* 225;1:63-68.
13. Russel CF, Hamberger B, Van Heerden JA, ReMine WH, Northcutt RC, Sheedy PF 2nd, Edis AJ, Ilstrup DM. Adrenalectomy: anterior or posterior approach? *Am J Surg* 1982;144:322-324.
14. Fernandez-Cruz L, Saenz A, Benarroch G, Astudillo E, Taura P, Sabater L. Laparoscopic unilateral and bilateral adrenalectomy for Cushing's syndrome. Transperitoneal and retroperitoneal approaches. *Ann Surg* 224;6:727-736.