

## Gastrojejunal fistula after gastric surgery for duodenal ulcer: case report

G. D'AMATA, A. RAHILI, B. KARIMDJEE-SOILIHI, E. GELSI, S. AVALLONE, D. BENCHIMOL

**SUMMARY: Gastrojejunal fistula after gastric surgery for duodenal ulcer: case report.**

G. D'AMATA, A. RAHILI, B. KARIMDJEE-SOILIHI, E. GELSI, S. AVALLONE, D. BENCHIMOL

*Gastrojejunal fistulae, a late complication of gastroenterostomy, are presently uncommon. Patients can present with symptoms of a fistula 20 years or more after their original gastric surgery. The knowledge of this rare condition can allow prevention, through a better operative strategy and a medical treatment at the phase of stomal ulcer with proton pump inhibitor and Helicobacter pylori eradication.*

*We present a case of gastrojejunal fistula and discuss the modern management of this condition. It's etiological, clinical, and surgical features were briefly discussed.*

**RIASSUNTO: Fistola gastrodigiunocolica dopo chirurgia gastrica per ulcera duodenale: caso clinico.**

G. D'AMATA, A. RAHILI, B. KARIMDJEE-SOILIHI, E. GELSI, S. AVALLONE, D. BENCHIMOL

*Le fistole gastrodigiunocoliche, una tardiva complicanza della gastroenterostomia, sono attualmente molto rare. I pazienti possono presentarsi con i sintomi di una fistola 20 anni e più dopo il loro primo intervento allo stomaco. La conoscenza di questa rara condizione può permettere la sua prevenzione applicando una migliore strategia operatoria, e praticando una terapia medica nella fase di ulcera stomale con gli inibitori di pompa protonica e l'eradicazione dell'*Helicobacter pylori*.*

*Presentiamo un caso di fistola gastrodigiunocolica con una breve trattazione dell'etiologia, delle caratteristiche cliniche e delle opzioni terapeutiche di questa condizione.*

KEY WORDS: Gastrojejunal fistula - Gastrectomy - Stomal ulcer.  
Fistola gastrodigiunocolica - Gastrectomia - Ulcera stomale.

### Introduction

Gastrojejunal fistula (GJF) is one of the severe complications of gastroenterostomy, even if gastrectomy is not associated. This entity complicates more frequently gastroenterostomy for ulcer peptic disease, but it can be observed sometimes in partial gastrectomy for cancer.

It represents one of the complications after gastroenterostomy, like as stenosis, bleeding or perforation. Gastrojejunal fistula can be associated to one or more of these complications. The factors that favours this complication are mainly technicals: insuffi-

cient resection of the stomach, incomplete vagotomy, retained antrum after gastrectomy and a long afferent loop may lead to the development of a stomal ulcer, which induces this disease. The knowledge of this rare condition can her prevention, through a better operative strategy and a medical treatment at the phase of stomal ulcer with proton pump inhibitor and *Helicobacter pylori* eradication.

### Case report

A 66-year-old man presented at our hospital on March 2004 with vomiting, diarrhoea, severe weight loss and epigastric pain. His history included a gastroenterostomy for complicated duodenal ulcer on 1961 and a right colectomy for colic cancer on January 2001 with adjuvant chemotherapy. On November 2002 the patient was operated for a high digestive obstruction due to the stenosis of the gastroenterostomy. A resection of the gastroenterostomy and a new loop-en-Y gastroenterostomy was performed. From April 2003 to march 2004 the patient was afflicted by several symptoms including abdominal pain, subocclusion and vomiting.

Nice University Hospital, "Archet 2", Nice, France  
Department of General Surgery and Digestive Oncology,  
Centro Ospedaliero Universitario di Nizza, Ospedale "L'Archet 2", Francia  
Servizio di Chirurgia Generale ed Oncologia Digestiva  
(Direttore: Prof. A. Bourgeon)

© Copyright 2006, CIC Edizioni Internazionali, Roma

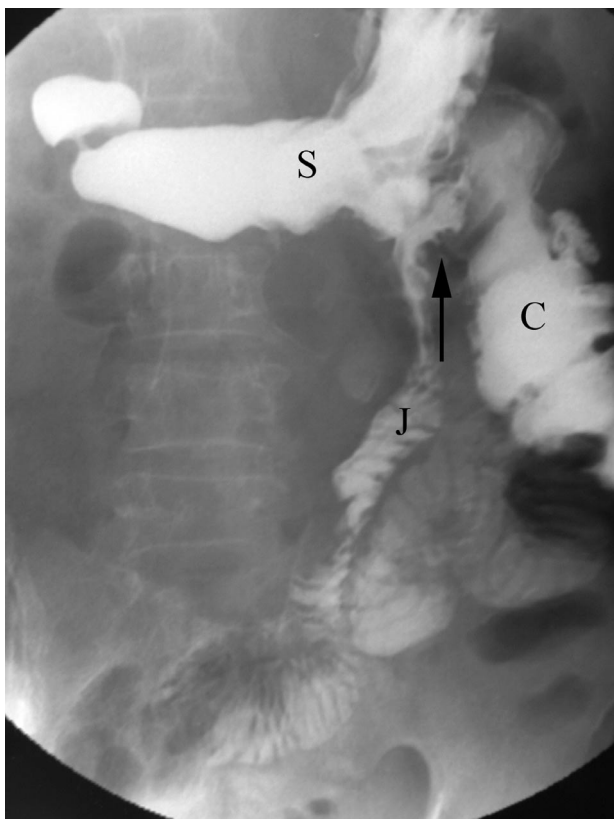


Fig. 1 - Gastrografin meal assessment confirmed the presence of a gastrojejunocolic fistula (arrow). J: jejunum; C: colon; S: stomach.

During this period he had various investigations (gastroscopy, abdominal TC, tumoral markers) which were normal.

The last admission on March 2004 was decided for physical decadence. A computerized tomography was not contributory, a gastroscopy showed eritematous gastritis and the presence of faecal matter in the stomach. Gastrografin meal assessment confirmed the presence of a jejunocolic fistula (Fig. 1). A colonoscopy was not contributory for the impossibility to pass through left colic angle. An hydrosoluble enema confirmed the presence of a gastrojejunocolic fistula and it was visible the anastomosis ileo-transversum at distance from the fistula (Fig. 2).

We performed an explorative laparotomy on April 2004 which confirmed the absence of local or peritoneal recurrence of colic cancer. The gastrojejunocolic fistula was found on the transverse colon at 12 cm from the anastomosis. A "revision" gastrectomy including the gastroenterostomy and segmental resection of the transverse colon with new ileo-transverse anastomosis were performed. Recovery was uneventful and the patient remained well at follow-up.

## Discussion

Gastric surgery for peptic ulcer disease is now rarely performed due to the development of medical therapies including  $H_2$ -receptor antagonists, proton pump inhibitors, and regimens for *Helicobacter pylori* era-

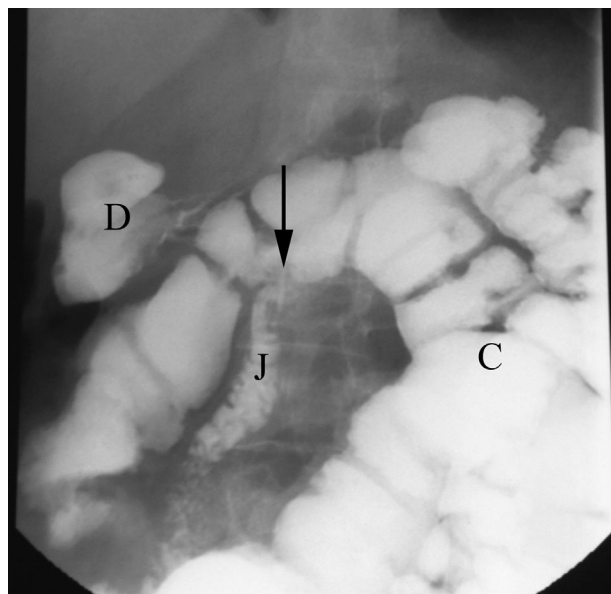


Fig. 2 - Hydrosoluble enema: there is contrast in the colon (C) which then entered stomach and duodenum (D) through the gastrojejunocolic fistula (arrow). J: jejunum loop of gastroenteroanastomosis.

dication. Previous case reports of gastrojejunocolic fistula have documented a latent period of up to 30 years before presentation (1). Thus, patients who underwent gastric surgery in the 1960s and 1970s are still likely to be seen with GJF in current clinical practice (2).

Marginal ulcer occurs in 3% of patients post-Billroth II subtotal gastrectomy; it occurs in less than 1% if truncal vagotomy is included but in up to 30% of patients with gastroenterostomy without vagotomy. Marginal ulcer can be seen in the last years after surgery for morbid obesity and pylorus-preserving pancreatoduodenectomy (3, 4). Recurrent, anastomotic, stomal and marginal ulcer are synonymous terms in the clinical practice. Marginal ulcer results generally from inadequate surgical therapy, that is insufficient resection of the stomach during subtotal gastrectomy or incomplete vagotomy. The other, less common, causes of marginal ulcer are the Zollinger-Ellison syndrome, retained antrum after gastrectomy, hyperparathyroidism and heavy use of salicylates (5).

Marginal ulcer can be complicated by perforation, haemorrhage and gastrojejunocolic fistula. Epigastric pain and haemorrhage are the most common symptoms of recurrent ulcers (6). Sudden development of diarrhoea and associated weight loss subsequent to gastroenterostomy should call attention to possible gastrojejunocolic fistula (7). It is generally believed that symptoms of marginal ulcer appear early after gastric resection for duodenal ulcer than after gastroenterostomy. When a patient is affected by denutrition and

faeculent eructation and he has a past history of gastric surgery we must think to this diagnosis (8).

For a correct diagnosis of this disease is essential to demonstrate the passage of barium from the stomach or jejunum into the transverse colon. A barium enema confirm the diagnosis in 90% of cases (9). By contrast, a barium meal demonstrates fistula in only 30% of all cases. Diagnosis is possible using upper gastrointestinal endoscopy. Gastroscopy finding of faecal matter associated with gastroenterostomy suggest the possibility of a gastrojejunal fistula. Faecal matter is an indirect sign of the fistula. In some instances, the diagnosis can be made on histological identification of colonic mucosa in the fistula (7). The use of endoscopy with simultaneous gastroscopy and colonoscopy has been proposed to achieve more sensibility (10).

Surgical treatment includes an en bloc resection of

stomal ulcer, including the fistula and involved colon, gastric and jejunal segment (11). In patients with severe denutrition management of gastrojejunal fistula involves improving metabolic status with total parenteral nutrition before undertaking one-stage, definitive surgery (7) or colostomy diversion as first step of surgical therapy (12).

In conclusion, gastrojejunal fistula, although rare, is seen occasionally in current practice as a result of past gastric surgery. It is therefore necessary to consider gastrojejunal fistula in the differential diagnosis when patients who have undergone gastrectomy with Billroth II reconstruction suffer from such symptoms as malnutrition or diarrhoea or faecal vomiting and weight loss. A revision gastrectomy and/or truncal vagotomy is the one-stage surgery indicated for this condition.

## References

*Per richiesta estratti:*

Iurassich Stefano  
Via P. Del Torto, 41 - 80131 Napoli  
e-mail Iuraderm@Libero.it

1. Sorensen BM. Non malignant gastrointestinal shortcircuit. (gastrojejunal fistula and gastroileostomy) *Acta Chir Scand Suppl* 1969;396:67-70.
2. Subramaniasivam N, Ananthakrishnan N, Kate V, Smile SR, Jagdish S, Srinivasan K. Gastrojejunal fistula following surgery for peptic ulcer. *Trop Gastroenterol* 1997;18:183-7.
3. Grace PA, Pitt HA, Longmire WP: Pylorus preserving pancreaticoduodenectomy: an overview. *Br J Surg* 1990;77:968-974.
4. Jordan JH, Hocking MP, Rout WR, Woodward ER: Marginal ulcer following gastric bypass for morbid obesity. *Am Surg* 1991;57:286-288.
5. Stable BE, Passaro E jr. Rrecurrent peptic ulcer. *Gastroenterol* 1976;70:124-130.
6. Keighley MRB, Hoare AM, Horrocks JC. A symptomatic discriminant to identify recurrent ulcer in patients with dyspepsia after gastric surgery. *Lancet* 1976;2:287-292.
7. Chung DPC, Li RSK, Leong HT. Diagnosis and current management of gastrojejunal fistula. *HKMJ* 2001;7:439-41.
8. Forrest EH, McMahon A, Danesh BJ. A man with a leaky drain. *Lancet* 2000;355:1328
9. Wilson RG, Wilson KS, Champion HR. Gastrojejunal fistula. *J R Coll Surg Edinb* 1973;18:227-30.
10. Nussinson E, Samara M, Abud H. Gastrojejunal fistula diagnosed by simultaneous gastroscopy and colonoscopy. *Gastrointestinal Endosc* 1987;33:398-9.
11. Ohta M, Hiroyuki K, Tatsuo T, Megumi B, Kinji K, Hiroshi M, Naoki U, Haruhiko S, Satoshi N. Gastrojejunal fistula after gastrectomy with Billroth II reconstruction: report of a case. *Surg Today* 2002;32:367-370.
12. Cody JH, DiVincenti C, Cowick DR, Mahanes JR. Gastrocolic and gastrojejunal fistulae: report of twelve cases and review of the literature. *Ann Surg* 1975;181:376-380.