

## Medullary thyroid carcinoma: state of the art

G. FAVIA, M. IACOBONE

Medullary thyroid carcinoma (MTC) is a tumor derived from the parafollicular C cells; it represents 3% to 10% of thyroid gland malignancies, but it is responsible for up to 13.4% of deaths that are caused by thyroid cancer (1). The proportion of medullary thyroid cancer to thyroid malignancies does not show a significant variation in geography, or regional iodine status.

MTC may occur in sporadic (70-84%) and familial forms (16-30%), inherited as an autosomal dominant pattern of transmission (2, 3). All ages may be affected by this neoplasm, but its incidence peaks during the fourth and sixth decades of life for the sporadic type and the second and third for the familial type (3). There is a slow increase in incidence with age and a slight female predominance among whites. Table 1 summarizes the main features of the various types of MTC.

### Pathology

Medullary thyroid carcinoma develops in C cells. The C cells have great biosynthetic activity and secrete several hormones and biogenic amines, including calcitonin (CT), ACTH, histaminase, carcinoembryogenic antigen (CEA). Clinically, the most important of these is CT, a peptide hormone, composed of 32 amino acids, which serves as an excellent tumor marker for MTC. The C cells are embryologically derived from the neural crest and are unrelated to the thyroid follicular cells. These cells and MTC become distributed typically within the middle and upper third of the lateral thyroid lobes.

MTC is usually solid, firm, non-encapsulated, but relatively well circumscribed and either whitish or red in colour. On histological examination, it consists in clusters of spindle-shaped, polygonal or round cells separated by fibrous stroma. The nuclei are usually uniform in shape with rare mitotic figures. Amyloid is frequently present. In all MTCs there is positive immunohistochemical staining for CT and CEA.

C cell hyperplasia (CCH) is a histologic abnormality associated and even implicated as the precursor of the hereditary types of MTC. CCH is present in all patients with hereditary MTC. Familial MTCs derived from CCH are bilateral, multicentric neoplasms. In contrast, sporadic MTCs are usually unifocal. MTC is usually considered an indolent disease, with prolonged survival, although it spreads early in its course to regional lymph nodes. Palpable MTC is reported to present with cervical lymph node metastases in 25-82% of cases; they are correlated with the size of the intrathyroid primary tumour (4, 5).

### Clinical presentation and diagnosis

The most common presentation of MTC is a painless thyroid nodule. Less commonly, the patient may present pain, dysphagia, hoarseness, or diarrhea. At initial presentation, the thyroid

TABLE 1 - MAIN FEATURES OF SPORADIC AND HEREDITARY MTC.

|                                     | Sporadic MTC  | MTC associated to MEN 2A  | MTC associated to MEN 2B  | Isolated familial MTC   |
|-------------------------------------|---|---|---|---|
| <i>Incidence</i>                    | 70%   | 20%   | 5%  | 5%  |
| <i>F:M ratio</i>                    | >1  | =1  | =1  | =1  |
| <i>Age at diagnosis</i>             | >45 years   | 20-30 years   | 1-10 years  | Variable  |
| <i>Histopathologic features</i>     | Unilateral lesion<br>Absence of C cell hyperplasia                                      | Multifocal and bilateral lesions<br>Presence of C cell hyperplasia              | Multifocal and bilateral lesions<br>Presence of C cell hyperplasia              | Multifocal and bilateral lesions<br>Presence of C cell hyperplasia              |
| <i>Associated diseases</i>          | -   | Pheochromocytoma (20-80%)<br>Hyperparathyroidism (10-30%)                       | Pheochromocytoma (20-60%)<br>Marfanoid features (80-90%)                        | -   |
| <i>Genetic marker</i>               | RET somatic mutations   | RET germinal mutations (exons 10,11)  | RET germinal mutations (exon 16)  | RET germinal mutations (exons 10,11,13,14,15)                                   |
| <i>Surgical treatment</i>           | Total thyroidectomy +<br>Central node dissection +<br>Mono or bilateral neck dissection | Total thyroidectomy +<br>Central node dissection +<br>Bilateral neck dissection | Total thyroidectomy +<br>Central node dissection +<br>Bilateral neck dissection | Total thyroidectomy +<br>Central node dissection +<br>Bilateral neck dissection |
| <i>Prophylactic treatment (age)</i> | None  | Total thyroidectomy (5 years)   | Total thyroidectomy (1 - 6 months)  | Total thyroidectomy (according to the type of mutation)                         |

swelling may be associated in up to 75% of patients with cervical lymphadenopathy which may not always be palpable.

Another mode of presentation is the patient who is found to have MTC on screening for medullary carcinoma as a component of MEN that presents with another neoplasm, or a family member of a patient with MEN.

The cornerstone to the diagnosis of MTC is the measurement of plasma calcitonin levels, representing the most sensitive diagnostic test. Virtually all patients with MTC have elevated basal calcitonin. It can be exploited for screening, diagnosis, and follow-up of the disease. The routine basal calcitonin measurement allows the identification of MTC at a preclinic stage; provocative test (pentagastrin and/or calcium) are accurate to differentiate between MTC-related hypercalcitoninemia from non thyroidal disease (ectopic secretion, renal insufficiency) (6).

Ultrasonography is a rapid, easy, noninvasive tool; it typically reveals a hypoechogenic solid nodule, and the state of the neck adenopathy. Ultrasonography can also guide fine needle aspiration cytology (FNAC). FNAC is adequate and easy, but it makes the correct diagnosis of MTC in only 50% of the cases and it is less sensitive than CT measurements (6).

The usual cytological findings for MTC are polygonal or triangular cells that are commonly binucleated with eccentric nuclei containing a coarse, granular chromatin pattern. The cytoplasm is abundant or moderate in amount with fine granularity and azurophylic granules. In addition, amyloid is found in variable amounts in the amorphous substance.

TABLE 2 - CORRELATION BETWEEN GENOTYPE AND PHENOTYPE AND THERAPEUTIC IMPLICATIONS IN MTC.

| Risk category            | Mutations  | Phenotype    | Age for prophylactic surgery                     |
|--------------------------|--|--------------|--|
| <i>Highest risk</i>      | exon 16 (codon 918)  | MEN 2B       | first 1- 6 months                                |
| <i>High risk</i>         | exon 11 (codon 634)<br>exon 10 (codons 609, 611,<br>618 and 620)                 | MEN 2A, FMTC | 5 years<br>(possibly later<br>for 609 mutations) |
| <i>Intermediate risk</i> | exon 13 (codon 768, 790, 791)<br>exon 14 (codon 804, 844)<br>exon 15 (codon 891) | FMTC         | 5-10 years or later                              |

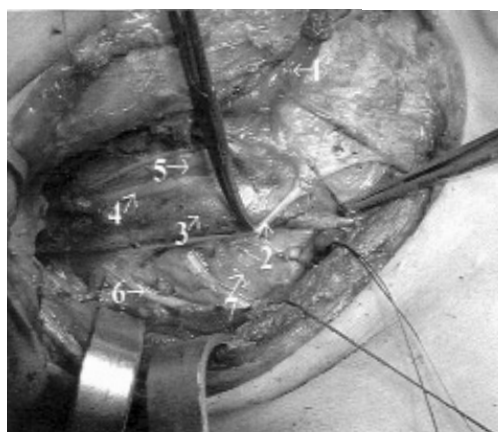


Fig. 1 - Right modified lateral neck dissection for MTC (lateral vision). 1: omohyoid muscle (sectioned); 2: ansa cervicalis; 3: jugular vein; 4: vagus nerve; 5: carotid artery; 6: accessory spinal nerve; 7: cervico-brachial plexus.

Furthermore, a CT scan that included the whole neck and mediastinum is required before surgery. The use of various scintigraphic studies is reserved for recurrence or metastatic disease.

### MTC and MEN syndromes

Hereditary MTC is transmitted as an autosomal dominant trait; it may be inherited alone (Familial Medullary Thyroid Carcinoma, FMTC) or as part of a Multiple Endocrine Neoplasia (MEN) 2A or 2B syndrome. Germ-line mutation of the RET proto-oncogene were identified in MEN 2A, FMTC and MEN 2B. The gene has 21 exons and it is located on chromosome 10q11.2; it encodes a tyrosine-kinase receptor. Patients with MEN 2A or 2B syndromes are primarily characterized by the occurrence of multifocal MTC and pheochromocytoma which is bilateral in 40% to 50% of cases. In addition, patients with MEN 2A may develop primary hyperparathyroidism, cutaneous lichen amyloidosis and Hirschsprung's disease (7).

Patients with MEN 2B syndrome are usually affected at a younger age with more aggressive tumours. In addition, these patients have a marfanoid habitus and develop mucosal gangliomas in the gastrointestinal tract, conjunctiva, tongue, and lips. The RET proto-oncogene encodes a cell surface tyrosine-kinase receptor with a large extracellular domain, a transmembrane domain and two cytoplasmic tyrosine-kinase domains. Germ-line mutations in different codons of this gene result in different phenotypes of the disease (8).

Mutations causing MEN 2A affect the cysteine-rich extracellular domain. These mutation are located in codon 634 (exon 11) or codons 609/611/618 and 620 (exon 10). The most common mutation, accounting for over 80% of all mutations associated with MEN 2A, affect the codon

634. In about half of FMTC kindreds mutations affect codons in exon 10 (mainly 618, 620); mutations affecting exons 11, 13, 14 and 15 occur more rarely. The main mutation in patients with MEN 2B is at codon 918 (exon 16) which encodes part of the cytoplasmatic tyrosine-kinase catalytic domain of the receptor (9).

Screening for MTC by testing for genetic mutations can also predict the occurrence of the disease, which allows for earlier surgery and potentially relieves the patient from worrying about the routine check-up. Approximately 5% of patients with apparently sporadic MTC have a germline mutation of the RET gene, and consequently hereditary MTC. A blood RET proto-oncogene analysis is advocated for all patients with apparently sporadic MTC. All patients with a germline RET mutation should undergo a prophylactic total thyroidectomy, though the timing of surgery is controversial.

Recently, according to the type of mutation, patients with hereditary MTC have been divided into three different risk categories (Table 2) (10). Patients with 918 mutations (MEN2B) should be operated early (at the first month of life), because of the aggressiveness of the disease, while patients with mutations in exons 13, 14 or 15 could undergo prophylactic surgery later, up to the third or even fourth decade of life (11) or, alternatively, when pentagastrin stimulation test becomes abnormal.

## Treatment

The primary treatment of MTC is the surgical removal of all neoplastic tissue present in the neck, and should be performed after careful exclusion of a pheochromocytoma by biochemical studies (urinary catecholamines, urinary and plasmatic metanephrines). In fact, in case of MEN, adrenalectomy should be performed prior to thyroidectomy, to avoid the possible hazardous effects of hormonally-active pheochromocytoma during neck surgery.

Several studies have shown that survival in patients with MTC is dependent upon the adequacy of the initial surgical procedure. For several reasons total thyroidectomy and systematic central neck node dissection is indicated for both the hereditary and sporadic forms. Familial MTC is almost always multifocal and bilateral; 30% of sporadic cases have bilateral disease, approximately 5% of apparently sporadic MTC prove to be index cases for hereditary forms; finally, in all cases nodal spreading occur very early.

Some authors recommend inclusion of the lateral neck dissection only if central or lateral lymph node metastases are proved, or if the primary tumor is palpable. In fact nodal metastases usually increase according to the size of the tumor, although large MTC without nodal involvement have been published (7). Others recommend systematic lateral modified neck lymph node dissection (Fig. 1), based on the notoriously high incidence of regional lymphatic involvement. Contralateral lymph node dissection may be omitted only in patients with an unilateral thyroid tumour and with no ipsilateral and central lymph node involvement. If mediastinal lymph node metastases are proved, this compartment should be dissected systematically.

In young gene carriers, detected through family screening, with normal basal or pentagastrin-stimulated calcitonin level and no overt thyroid lesion, total thyroidectomy results to be prophylactic and, subsequently, curative.

All parathyroid glands should be identified during thyroidectomy, however controversy exists regarding how these glands should be preserved to maintain function. Some authors preserve the superior parathyroids in situ, since inferior glands are usually excised at the time of central node dissection; others perform total parathyroidectomy with autotransplantation (12). An invasive medullary carcinoma may require resection of a part or a sleeve of the trachea or a part of the pharyngeal wall.

Following surgical treatment, the patients are monitored with regular measurements of basal and pentagastrin-stimulated serum calcitonin levels. Calcitonin and CEA levels should usually be assessed for baseline levels approximately 4 weeks after surgery (13). A persistent or re-elevating level may indicate loco-regional recurrence or metastatic disease.

In patients with persistently elevated CT levels, the challenge is finding the site of residual disease. Tumour localization techniques include ultrasonography of the neck and liver, CT or MRI of the neck, chest and liver, and bone scintigraphy. Isotopic scanning with thallium 201,

dimercaptosuccinic acid labelled with  $^{99m}\text{Tc}$ ,  $^{123}\text{I}$  metaiodobenzyl-guanidine (MIBG), somatostatin analogues labelled with indium 111 or monoclonal antibodies directed against CT or CEA, and even position emission tomography (PET) with FDG are poorly sensitive. Liver metastases may be difficult to visualize by these imaging modalities and may be identified only at laparoscopy.

Selective venous sampling catheterization with CT measurements appears to be the most sensitive and specific technique for localizing occult metastatic disease.

Patients with elevated calcitonin should be carefully selected for reoperation. Iterative surgery is rarely curative in case of recurrent or persistent MTC, and should be reserved only for cases localized exclusively at the neck. Reoperations could be effective in reducing calcitonin levels, but the real impact on survival is being debated.

Although there are ongoing clinical trials, no single agent or combination chemotherapy has been shown to be beneficial in the control of metastatic disease. Future directions include the use of gene therapy, for inactivation or destruction of RET, and  $^{131}\text{I}$  MIBG for the treatment of advanced and metastatic disease.

### Abstract

Medullary thyroid carcinoma (MTC) constitutes about 3-10% of all thyroid cancers. It arises from the parafollicular C cells that produce calcitonin (CT) and occurs as a sporadic form, or less commonly, as a hereditary form, as part of multiple endocrine neoplasia syndromes types 2A (MEN 2A) and 2B (MEN 2B). The hereditary forms are autosomal dominant traits associated with germline mutations of RET proto-oncogene. Progresses in genetics have permitted an improvement of management, screening and treatment. Surgery is the only successful treatment for MTC, as there is no effective adjuvant therapy for residual disease. A total thyroidectomy and vigilant management and surveillance of the neck are recommended. Interdisciplinary management including surgeons, endocrinologists, pathologists, radiotherapists, radiologists, and oncologists should be considered.

### References

1. Hundahl SA, Fleming ID, Fremgen AM, Menck HR. A national cancer data base report on 53,856 cases of thyroid carcinoma treated in the U.S., 1985-1995. *Cancer* 1998; 83:2638-2648.
2. Wells SA Jr, Franz C. Medullary carcinoma of the thyroid gland. *World J Surg* 2000; 24:952-956.
3. Raue F. German medullary thyroid carcinoma /multiple endocrine neoplasia registry. German MTC/MEN Study Group. Medullary thyroid carcinoma/multiple endocrine neoplasia type 2. *Langenbecks Arch Surg* 1998; 383: 334-336.
4. Scollo C, Baudin E, Travagli JP, Caillou B, Bellon N, Leboulleux S, Schlumberger M. Rationale for central and bilateral lymph node dissection in sporadic and hereditary medullary thyroid cancer. *J Clin Endocrinol Metab*, 2003; 88:2070-2075.
5. Tamagnini P, Iacobone M, Sebag F, Marcy M, De Micco C, Henry JF. Lymph node involvement in macroscopic medullary thyroid carcinoma. *Br J Surg* 2005; 92:449-453.
6. Iacobone M, Niccoli-Sire P, Sebag F, De Micco C, Henry JF. Can sporadic medullary thyroid carcinoma be biochemically predicted? Prospective analysis of 66 operated patients with elevated serum calcitonin levels. *World J Surg* 2002; 26:886-890.
7. Pasini B, Rossi R, Ambrosio MR, Zatelli MC, Gullo M, Gobbo M, Collini P, Aiello A, Pansini G, Trasforini G degli Uberti EC. RET mutation profile and variable clinical manifestations in a family with multiple endocrine neoplasia type 2A and Hirschprung's disease. *Surgery* 2002; 131:373-381.
8. Eng C, Clayton D, Schuffenecker I, Lenoir G, Cote G, Gagel RF, van Amstel HK, Lips CJ, Nishisho I, Takai SI, Marsh DJ, Robinson BG, Frank-Raue K, Raue F, Xue F, Noll WW, Romei C, Pacini F, Fink M, Niederle B, Zedenius J, Nordenskjold M, Komminoth P, Hendy GN, Mulligan LM, et al. The relationship between specific RET proto-oncogene mutations and disease phenotype in multiple endocrine neoplasia type 2. International RET mutation consortium analysis. *JAMA* 1996; 276: 1575-1579.
9. Skinner MA, Moley JA, Dilley WG, Owzar K, Debenedetti MK, Wells SA Jr. Prophylactic thyroidectomy in multiple endocrine neoplasia type 2A. *N Engl J Med* 2005; 15; 353: 1105-1013.
10. Cote GJ, Gagel RF: Lessons learned from the management of a rare genetic cancer. *New England Journal of Medicine*, 2003; 349, 1566-1568.
11. Frohnauer MK, Decker, RA. Update on the MEN 2A c804 RET mutation: is prophylactic thyroidectomy indicated? *Surg* 2000; 128: 1052-1058.
12. Cohen MS, Moley JF. Surgical treatment of medullary thyroid carcinoma. *J Intern Med*, 2003; 253:616-626.
13. Brauchoff M, Gimm O, Brauchoff K, Ukkat J, Thomusch O, Dralle H. Calcitonin kinetics in the early postoperative period of medullary thyroid carcinoma. *Langenbecks Arch Surg*, 2001; 386: 434-439.